

CONGENITAL CARDIOLOGY TODAY

Timely News and Information for BC/BE Congenital/Structural Cardiologists and Surgeons

Volume 6 / Issue 2

February 2008

International Edition

IN THIS ISSUE

Role of Interventional Cardiology in the Treatment of Neonates – Part III

by P. Syamasundar Rao, MD
Page 1

Congenital Cardiology at ACC.08: Exciting New Program Planned

by John W. Moore, MD, FACC and
John F. Rhodes, Jr., MD, FACC
Page 12

DEPARTMENTS

Medical News, Products and Information

Page 15

CONGENITAL CARDIOLOGY TODAY

Editorial and Subscription Offices
16 Cove Rd, Ste. 200

Westerly, RI 02891 USA

www.CongenitalCardiologyToday.com

© 2008 by Congenital Cardiology Today ISSN: 1544-7787 (print); 1544-0499 (online). Published monthly. All rights reserved.

Statements or opinions expressed in Congenital Cardiology Today reflect the views of the authors and sponsors, and are not necessarily the views of Congenital Cardiology Today.

**Register Now for
CCS.08
Congenital Cardiology
Solutions
Launching at
ACC.08
Mar 29-Apr 1, 2008,
Chicago, IL USA
Register Today
www.acc08.acc.org/ccs08
See Ad on Page 2**

Role of Interventional Cardiology in the Treatment of Neonates - Part III

By P. Syamasundar Rao, MD

"Role of Interventional Cardiology in the Treatment of Neonates – Part III" is the third and final article in a series of articles by P. Syamasundar Rao, MD, Professor of Pediatrics and Medicine, Director, Division of Pediatric Cardiology, University of Texas-Houston Medical School. The first article appeared in December 2007, and the second appeared in January 2008. All issues are on the website in PDF files.

INTRODUCTION

Non-surgical atrial septostomy to enlarge or create atrial septal defects and balloon angioplasty/valvuloplasty to relieve critical obstructive lesions in the neonate were presented in the first two parts of this review [1,2]. Discussion of other interventional procedures (Table I) will be presented in this third and final paper.

Table I. Catheter Interventional Techniques Used in the Neonate

- Non-surgical atrial septostomy
- Balloon angioplasty/valvuloplasty
- Radiofrequency perforation of atretic pulmonary valve
- Transcatheter occlusion of shunts
- Stents

RADIOFREQUENCY PERFORATION OF ATRETIC PULMONARY VALVE

Pulmonary atresia with intact ventricular septum is a complex cyanotic congenital heart defect with poor long-term prognosis [3-6]. One of the objectives of the management of these infants is to optimize chances for restoration of a four-chambered heart [6-9]. To achieve this objective, the hypoplastic right ventricle should be encouraged to grow [6,7]. Surgical pulmonary valvotomy at the time of presentation or shortly thereafter was initially recommended to promote forward egress of the right ventricular output and to stimulate growth of the right ventricular cavity so that it could eventually support the cardiac output into the pulmonary circuit [6,7]. Perforation of the atretic pulmonary valve membrane with the blunt end of a guide wire or by Laser and radiofrequency energy followed by balloon valvuloplasty [8,10-18] has been advocated by some cardiologists. With the availability of radiofrequency wires (now approved by the US Food and Drug Administration), this method replaces perforation with the stiff end of a guide wire.

Radiofrequency Perforation

The procedure involves the usual percutaneous catheterization, followed by right ventricular angiography in sitting-up (15° LAO and 35° cranial) and straight lateral views to evaluate the anatomy of the right ventricle and to measure the pulmonary valve

RECRUITMENT ADVERTISING FOR Europe, Asia, Middle East, Australia

- Pediatric Cardiologists
- Congenital/Structural Cardiologists
- Interventionalists
- Echocardiographers
- Imaging Specialists
- Electrophysiologists
- Congenital/Structural Heart Failure Specialists
- Cardiac Intensivists

For more information and pricing: recruit@cct.bz



CCS.08

Congenital
Cardiology
Solutions



Launching at ACC.08!
March 29 - April 1, 2008 Chicago

CCS.08 will combine the best of the traditional programming for cardiologists and surgeons specializing in congenital heart disease with live interventional cases demonstrating the latest in medical and scientific advances in interventional therapies. Join us and be on the leading edge with the latest information on congenital and structural heart disease. Specific topics include:

- Imaging strategies for congenital heart defect patients
- Transition of pediatric CHD patients to adult CHD clinics
- Molecular and genetic aspects of CHD
- CHD surgical techniques and outcomes
- Repair and care of PFO, VSD and Aortic coarctation
- Sudden cardiac death in young athletes
- Arrhythmia management of adult CHD patients
- FDA Trial Updates on devices for VSD, PFO, PDA and other congenital conditions
- Plus, one day of live interventional cases from the master interventionalists at Columbus Children's Hospital and Boston Children's Hospital.

Congenital cardiology programming is also available at the SCAI-ACCi2 sessions. **Advance registration closes Feb. 20!** Visit www.acc08.acc.org to register today for the combo meeting package for access to both ACC.08 and SCAI-ACCi2 sessions.

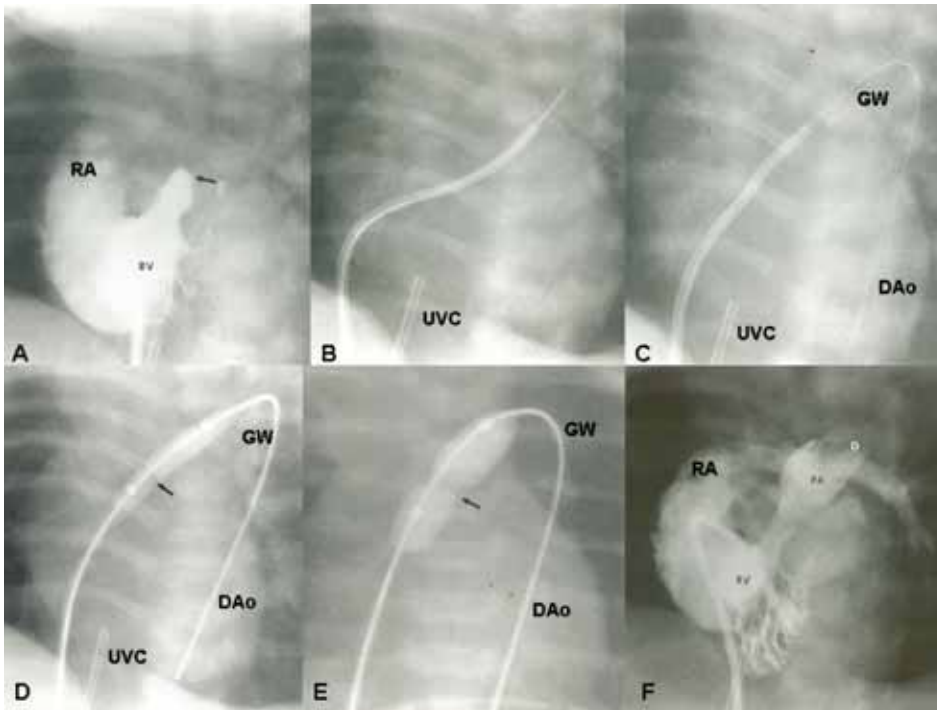


Figure 1. [A]. Selected right ventricular (RV) cineangiographic frame in a sitting-up (15° LAO and 35° cranial) view demonstrating an atretic pulmonary valve (arrow). Note opacification of the right atrium (RA) due to tricuspid insufficiency. [B & C]. Following perforation of the atretic pulmonary valve, note passage of a guide wire (GW) into the pulmonary artery and then into the descending aorta (DAo). [D & E]. Five mm diameter and 8 mm diameter balloon dilatation catheters across the perforated pulmonary valve membrane are shown with "waisting" of the balloon (arrows) during the initial phases of balloon inflation which has disappeared following full inflation of the balloon (Not shown). [F]. Right ventricular angiography following the procedure demonstrates opacification of the pulmonary artery (PA) and its branches. Also note opacification of pulmonary end of patent ductus arteriosus (D). There was significant tricuspid insufficiency both before and after the procedure. UVC, Umbilical venous catheter.

annulus. The echo data along with angiographic data should ensure that there is no right ventricular dependent coronary circulation. A right coronary artery (Cordis) or a similar guide catheter is placed in the right ventricular outflow tract and a Nykanen radiofrequency perforation catheter (wire) (Baylis, Montreal, Canada) is positioned against the pulmonary valve. After confirming the position of the catheter, low power (5 to 10 watts) radiofrequency energy of one to two second duration is applied with a BMC radiofrequency perforation genera-

tor (Baylis), thus perforating the pulmonary valve. The perforation catheter is advanced across the pulmonary valve and then into the branch pulmonary arteries or into the descending aorta via the ductus. A Protrach[™] Micro catheter (Baylis) (into which the radiofrequency wire was pre-loaded) is then advanced over the Nykanen radiofrequency perforation catheter and exchanged with a floppy-tipped coronary guide wire that is suited to position the selected balloon dilatation catheter. A balloon angioplasty catheter is ad-

vanced over the guide wire and positioned across the pulmonary valve. The balloon is inflated with diluted contrast material (1 in 4), as described in the Critical Pulmonary Stenosis section [2]. Progressively increasing sizes of balloon diameters are usually required, with a final balloon diameter of 6 to 8 mm, depending upon the measured pulmonary valve annular diameter. Various steps in accomplishing the procedure are illustrated in Figure 1.

Results

The feasibility of perforation of the atretic valve varies from one study to the other, reviewed elsewhere [8]. In one large series [19], successful perforation was achieved in 27 out of 30 (90%) patients. In half the patients a modified Blalock-Taussig shunt was required between 2 and 24 days after opening the valve. There were three early deaths and two late deaths. During follow-up, sixteen patients achieved biventricular circulation. The study authors concluded that percutaneous perforation followed by balloon dilatation is a good treatment strategy for neonates with pulmonary atresia provided that there is no right ventricle-dependent coronary circulation and the right ventricular infundibulum is patent.

TRANSCATHETER OCCLUSION OF SHUNTS

Atrial and Ventricular Septal Defects and Patent Ductus Arteriosus

A number of devices to close the atrial [20-23] and ventricular [24] septal defects and patent ductus arteriosus [25-27] have been developed. However, closure of these defects by transcatheter methodology is either not necessary or feasible in the neonate and will not be further discussed.

Superfluous Vascular Lesions

Transcatheter embolization of superfluous vascular lesions, although well-described by the late 1970s [28,29], was by and large a procedure used in adult subjects,



Healing hearts. Training minds. Bringing hope.

5075 Arcadia Avenue Minneapolis, MN 55436 U.S.A.
Toll Free: 888.928.6678; Phone: 952.928.4860; Fax: 952.928.4859

www.childrensheartlink.org

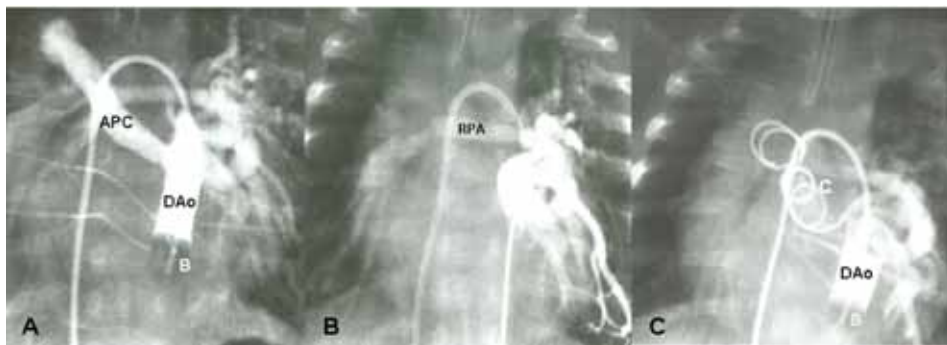


Figure 2. [A]. Selected cineangiographic frame from balloon (B) occlusion aortography in a neonate with severe congestive heart failure demonstrating a large persistent aorto-pulmonary collateral (APC) vessel connecting the descending aorta (DAo) to the right pulmonary artery (RPA). [B]. Dual blood supply to the RPA is demonstrated from an APC on the left side. [C]. Occlusion initially with an 8-mm diameter Gianturco coil (c) and a few smaller coils resulted in complete occlusion of the APC. The infant improved remarkably from congestive heart failure and eventually underwent unifocalization and complete correction.

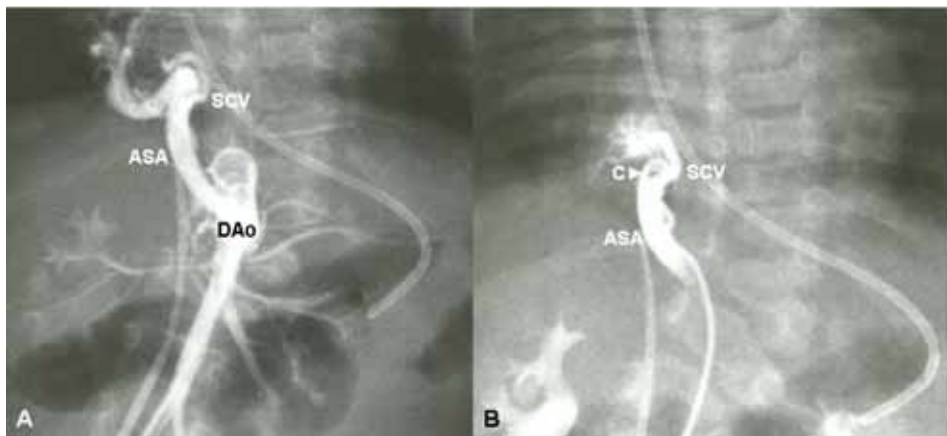


Figure 3. [A]. Selected descending aorta (DAo) cineangiographic frames demonstrating a large anomalous systemic artery (ASA) opacifying a sequestered lung segment in an infant with severe congestive heart failure. [B]. The ASA was occluded with a coil (c) resulting in complete occlusion of the ASA. A small vessel (SV) was not occluded. Following the procedure the infant improved dramatically.

usually performed by radiologists. A number of embolic materials have been used, but the steel coil described by Gianturco and his associates in 1975 [30] has become the embolic material of choice. Transcatheter occlusion has been applied to children to close pulmonary arterio-venous fistulae, aorto-pulmonary collateral vessels, veno-venous collateral vessels, aorto-pulmonary surgical shunts, coronary arterio-venous fistulae, and vessels associated with pulmonary sequestration and hemoptysis [31,32]. While Gianturco coils are most commonly used, other embolic materials such as detachable balloons, devices and more recently Amplatzer vascular plugs are also used.

While not frequent, need for occlusion of superfluous vascular lesions in the neonate does exist and these include: cerebrovascular and hepatic arterio-venous fistulae, multiple aorta-pulmonary collateral vessels (MAPCVS) associated with pulmonary atresia with ventricular septal defect (Tetralogy of Fallot) and anomalous systemic artery associated with pulmonary sequestration/scimitar syndrome. Cerebrovascular and hepatic arterio-venous fistulae are usually dealt with by the neurosurgeons and/or interventional radiologists and will not be reviewed.

MAPCV

In patients with pulmonary atresia or tetralogy of Fallot, MAPCVS arise most commonly from the descending aorta or from brachiocephalic vessels. Whereas the pulmonary blood flow through these vessels is useful in maintaining good systemic arterial oxygen saturation, such vascular connections may become problematic when excessive pulmonary blood flow through these vessels may precipitate congestive heart failure. The procedure involves defining the pulmonary arterial supply and then occluding the collateral vessel(s) after ensuring dual supply to that particular lung segment. Gianturco coils are usually used (Figure 2) although devices and vascular plugs may be useful in such situations. Such aorta-pulmonary collateral vessels are seen in other cardiac defects and even in otherwise normal hearts and can cause significant cardiac dysfunction requiring closure in the neonatal period.

Pulmonary Sequestration

Pulmonary sequestration may either be intralobar or extralobar [33] and is usually associated with Scimitar syndrome [34,35]. The sequestered lung, however, receives blood supply from an anomalous systemic artery, most commonly arising from abdominal or thoracic aorta. Large intrapulmonary shunt may result in congestive heart failure in the newborn. Whereas surgical resection of the sequestered lung along with ligation of the vessel supplying the sequestered lung segment has been the conventional approach, several workers, over the years [32,36-40], employed transcatheter embolization and found successful results. Gianturco coils have successfully been used [32,36-40]. Indication for transcatheter intervention in the neonate is severe or difficult to treat heart failure. Transcatheter coil occlusion (Figure 3) is safe, feasible and effective. The procedure involves performing selective descending aortography to define the vascular supply to the sequestered lung segment and then occluding the vessel(s) with a coil or vascular plug.

STENTS

Balloon angioplasty may be effective in relieving vascular obstructive lesions. However, elastic recoil of the vessel wall may result in ineffective relief of obstruction in some cases. Stents, by exerting radial forces, prevent elastic recoil of the vessel wall and produce more effective

relief of obstruction. The concept of the stent was initially proposed by Dotter and Judkins and their associates [41,42] in the 1960s. Clinical use was not established until late 1980s when Palmaz, Sigwart and their colleagues brought it to fruition [43-45]. Pediatric applications of stent technology followed [46,47] and were reviewed in detail elsewhere [48]. The major limitation of stents in the pediatric patient is that the stents do not grow as the child grows, because the majority of stents are metallic. Stents, in addition to keeping open obstructed stenotic vessels may also be used to keep open naturally occurring structures such as patent foramen ovale (PFO) and patent ductus arteriosus (PDA). Potential uses of stents (Table II) in the neonates will be discussed below.

Table II. Potential Uses of Stents in the Neonate

- Obstruction at patent foramen ovale/atrial septum
- Ductus arteriosus
- Aortic coarctation
- Branch pulmonary arteries
- Miscellaneous

Atrial Septum/PFO

The role of stents in creating or keeping open an atrial defect has been discussed in the section on non-surgical atrial septostomy [1] and will not be discussed further.

Ductus Arteriosus

There are a number of cardiac defects in which the ductus, if it remained patent, would be beneficial, providing pulmonary or systemic blood flow. These lesions are listed in Table III. Pharmacologic means of maintaining the ductus by intravenous infusion of Prostaglandin E1 is quite helpful, but requires prolonged and continuous intravenous access, and more importantly, the effectiveness of PGE1 fades as the neonate ages. Consequently, alternative methods of keep-

Table III. Ductal-Dependent Cardiac Defects

A. Ductal-Dependent Pulmonary Flow

- Pulmonary atresia or critical stenosis with intact ventricular septum
- Pulmonary atresia with ventricular septal defect
- Severe tetralogy of Fallot
- Tricuspid atresia
- Complex cyanotic heart disease with pulmonary atresia or severe stenosis
- Ebstein's anomaly of the tricuspid valve
- Hypoplastic right ventricle

B. Ductal-Dependent Systemic Flow

- Hypoplastic left heart syndrome
- Severe coarctation of the aorta syndrome
- Interrupted aortic arch

ing the ductus open have to be pursued. Balloon dilatation of the ductus was attempted, as reviewed elsewhere [49], but the long-term patency is uncertain. Therefore, stenting of the ductus arteriosus is a logical extension of transcatheter methodology. Stent implantation in experimental animal models [50-54] to maintain ductal patency have been undertaken and have demonstrated that stents are superior to balloon dilatation in maintaining ductal patency [49,52]. Clinical applications followed and include ductal stent implantation for treatment of pulmonary atresia [8,54,55], right ventricular hypoplasia [56], critical pulmonary stenosis [55], other complex heart defects with reduced pulmonary blood flow [55,57] and Hypoplastic left heart syndrome [58,59].

Stent Implantation Procedure

Two groups of lesions (Table III) will require separate consideration. First is the pulmonary oligemia group (ductal dependent pulmonary flow; Table III A), comprising complex cyanotic congenital heart defects with severe pulmonary stenosis or atresia that are not correctable in the neonatal period. The established management practice involves creation of an aortopulmonary anastomosis (usually a modified Blalock-Taussig shunt) to alleviate pulmonary oligemia and systemic arterial hy-

poxemia. An alternative approach is to keep the ductus open by placing a stent in it. Similarly, left heart obstructive lesions, particularly Hypoplastic left heart syndrome patients may be benefited by ductal stents while awaiting for a more definitive procedure or as a part of hybrid procedures [58-63].

Pulmonary Oligemia

Initially, diagnostic cardiac catheterization and selective cineangiography are performed to determine the type of heart defect and sources of pulmonary blood flow. If it is determined that the defect is not correctable in the neonatal period, ductal stent implantation is a reasonable option. Aortograms are reviewed, and if necessary, additional aortograms are performed to define the ductal anatomy and its minimal diameter and length. Straight lateral, sitting-up (15° LAO and 35° cranial) and 30° RAO views are best to define the ductal morphology. This will also establish landmarks for ductal stenting. A #4-French Judkins right coronary artery (RCA) catheter or a cut-pigtail catheter is positioned in the aortic arch and a coronary guide wire (Choice PT Extra S'port (Boston Scientific) or a similar wire) is manipulated into the ductus arteriosus and main pulmonary artery and from there into a distal left or right pulmonary artery. The ductal length is re-measured since its straightening by the



Barth Syndrome
Foundation

The Barth Syndrome Foundation

P.O. Box 974, Perry, FL 32348

Tel: 850.223.1128

info@barthsyndrome.org

www.barthsyndrome.org

Symptoms: Cardiomyopathy, Neutropenia, Muscle Weakness, Exercise Intolerance, Growth Retardation

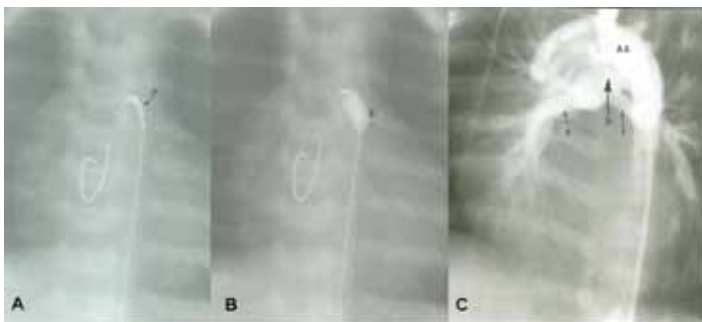


Figure 4. [A]. Selected cinefluorographic frames demonstrating the position of a guide wire which was advanced from the aorta into the right ventricle via the ductus arteriosus and the main pulmonary artery over which an uninflated stent/balloon assembly is deployed. The arrow marks the articulation within the stent. [B]. Note the position of the stent in the ductus while inflating the balloon. [C]. Aortic arch (AA) angiogram shows the stented ductus (St) and good opacification the right (R) and left (L) pulmonary arteries. The main pulmonary artery is not shown.

guide wire may alter its length. The catheter and femoral arterial sheath are removed and replaced with a 4-French long sheath (Cook, Bloomington, IL). A 3.5 to 4.5 mm diameter (depending upon the weight of the baby) coronary stent mounted on a balloon is introduced through the 4-French sheath, over the guide wire, and positioned across the ductus arteriosus (Figure 4A) and the balloon is inflated (Figure 4B), thus implanting the stent into the ductus. The length of the stent should be 1 to 2 mm longer than the measured length of the ductus. A variety of stents have been used in the past and include Palmaz-Schatz articulated (Johnson & Johnson, Warren, NJ), Jostent (JoMed, Ramendingen, Germany), Express (Boston Scientific, Maple Grove, Minnesota), Multi-link Tetra/Penta (Guidant, Santa Clara, California), Cordis JJ (Cordis Europa, Roden, The Netherlands), Medtronic AVE (Medtronic Inc., Minneapolis, MN), liberté (Boston Scientific), Driver (Medtronic), Tsunami (Terumo), NIR coronary (Medinol/SciMed Life, Maple Grove, MN), Coroflex (B Braun Medical, Emmenbruche, Switzerland), Tristar (Guidant, Santa Clara, California), and others depending upon the availability at that particular time at a given institution. Aortography following stent implantation (Figure 4C) is performed to demonstrate the patency of the stent and opacification of the main and both right and left pulmonary arteries. The arterial oxygen saturation is measured.

In nearly 10% of the patients the aortic origin of the ductus may be very proximal (from the undersurface of the aorta) and conventional retrograde trans-femoral arterial access may not be feasible. In such instances, the ductus may be cannulated via an antegrade transvenous route through the ventricular septal defect or via trans-carotid artery cut-down.

Results

Gibbs and associates [54] were the first to report placement of ductal stents; they implanted ductal stents (Palmaz-Schatz) via axillary arteriotomy in two neonates with pulmonary atresia which resulted in improvement of systemic arterial oxygen saturation. Both infants, however, died suddenly within five weeks of stent placement, although the stented ducts were patent. They concluded that: (a) stenting of arterial duct is technically feasible, (b) stenting provides adequate palliation and this technique may prove to be a promising alternative to

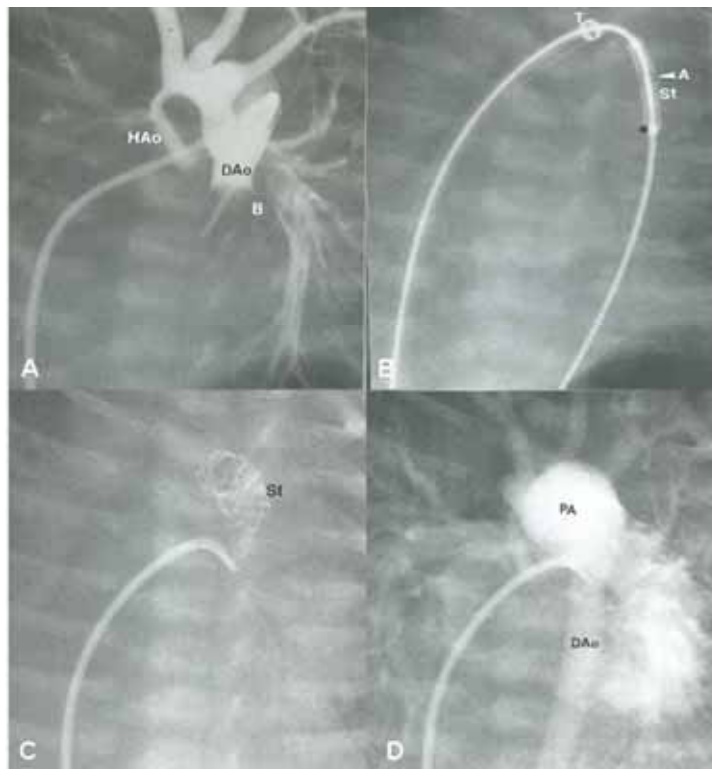


Figure 5. [A]. Selected frame of balloon (B) occlusion descending aortic (DAo) angiogram demonstrating good retrograde opacification of the aortic arch and brachiocephalic vessels and a hypoplastic ascending aorta (HAo). The ductus and left pulmonary artery are also seen, but not labeled. [B]. Selected cinefluorographic frame showing the position of the unexpanded stent (St) in the ductus. The articulation of the stent (A) and tip (T) of the delivery sheath are marked. [C]. The deployed stent (St) in the ductus after removal of the balloon is shown. The catheter is in the pulmonary artery. [D]. Pulmonary artery (PA) cineangiographic frame demonstrating opacification of the descending aorta (DAo) and branch pulmonary arteries. Retrograde opacification of the brachiocephalic vessels and a hypoplastic ascending aorta (not labeled) is also seen.

aorto-pulmonary shunt surgery. Despite initial enthusiasm [54,64], Gibbs et al [65] were discouraged with stenting because of intimal proliferation in the majority of patients, requiring re-intervention. A larger experience reported by Alwi et al [66] demonstrated feasibility, safety and effectiveness of ductal stents. They attempted stenting the ductus in 56 patients, aged 7 days to 2.8 years (30% were neonates) with successful implantation in 91% patients. Complications occurred in 3 (6%) patients. The oxygen saturation improved from $70 \pm 14\%$ to $91 \pm 7\%$. At follow-up in 3 to 20 months (mean 10 months), the oxygen saturations remained improved and were $79 \pm 5\%$. Additional interventions such as balloon dilatation of the stent, placement of an additional stent or Blalock-Taussig shunt were performed in 8 (16%) patients. Re-intervention-free rates were 89% and 55% at six and 12 months respectively. They conclude that stenting of the ductus is an attractive alternative to surgical aorto-pulmonary shunts in palliating infants with ductal dependant pulmonary circulation. They also suggested that ductal stenting should not be undertaken if left pulmonary artery stenosis is present.

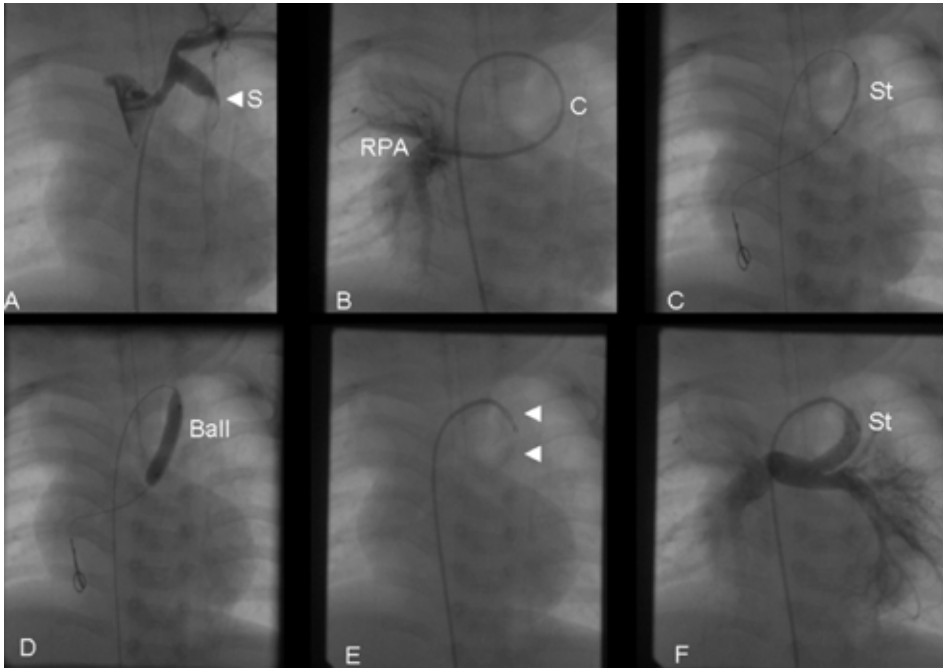


Figure 6. [A]. Selected cineangiographic frame from subclavian artery injection demonstrating stenotic and almost completely obstructed (arrowhead S) Blalock-Taussig shunt. [B]. A catheter (c) is positioned across the Blalock-Taussig shunt into the right pulmonary artery (RPA). [C]. A guide wire has been passed through Blalock-Taussig shunt and its tip positioned in the distal RPA over which a stent (unexpanded) is placed within the Blalock-Taussig shunt. [D]. Same as C except that the stent-coved balloon is expanded. [E]. The balloon is removed showing the deployed stent (arrow heads). [F]. Post-stent implantation angiogram showing the well opacified, widely open stent (St) in the Blalock-Taussig shunt with subsequent opacification of the branch pulmonary arteries.

Comments

Based on our experience and that of others [8,54-57,66] ductal implantation of stent is a technically demanding but a feasible procedure. Inability to cannulate the ductus and constriction of the ductus [64,66], the latter being potentially fatal, may occur. It is important to stent the entire length of the ductus [8,64,66] lest constriction of the unstented ductus may occur later, requiring a repeat procedure. In neonates, the stent should not be expanded to more than 4 mm diameter; larger diameter stents may produce heart failure [18]. The availability of more flexible stents on smaller delivery catheters and recognition that selected use in situations where progressive closure of the stented ductus over a period of months

may indeed be beneficial, could rejuvenate the use of ductal stents in the future.

Left Heart Obstruction

The stent implantation procedure is performed anterogradely from the femoral venous route (Figure 5) or via a pulmonary artery purse-string suture during hybrid procedures. It is important to define the ductal anatomy [67] and to cover the entire length of the ductus. Stent diameter is 6 to 10 mm, much larger than that used for pulmonary oligemia patients. Both balloon expandable and self-expandable stents have been used. In most reported studies, palliation is deemed to have been achieved, but the experience is limited.

Further studies and experience is required before general use.

Other Uses of Ductal Stents

In addition to the above two groups, ductal stents have also been successfully used to treat pulmonary oligemia secondary to right ventricular outflow tract rhabdomyoma [68] and to retrain the left ventricle in transposition of the great arteries with intact ventricular septum [69].

Aortic Coarctation

Neonates with severe aortic coarctation causing congestive heart failure are candidates for intervention. Surgical intervention has been the main approach to treat these babies. More recently, balloon angioplasty techniques have been utilized in the management of aortic coarctation. Because of the high rate of recurrence seen in neonates [2,70-73], balloon angioplasty in neonates and young infants is reserved for critically ill babies, particularly in those in whom avoidance of anesthesia or aortic cross-clamping required for surgery is beneficial in the overall management [2,74]. To address this issue some cardiologists have used stents [75-78]. Unfortunately, as previously mentioned, the stents, which are metallic, do not grow with the child, and therefore, could not routinely be used in neonates and infants. Biodegradable stents [79,80] may offer a solution; the stents will keep the coarcted aortic segment open for a 3 to 6 month period, when the stents would dissolve. Further experience with this methodology is necessary before the adoption of this mode of treatment.

Branch Pulmonary Artery Stenosis

Stenotic branch pulmonary arteries may sometimes pose problems; these are particularly important in patients destined for a Fontan-type of repair. Near-normal sized pulmonary arteries are mandatory for successful completion of Fontan. Rehabilitating the pulmonary arteries may be undertaken with balloon angioplasty, but, because of lack of uniform response to this mode of treatment, stents have been considered. Again, the growth problems, al-



Pediatric Critical Care Medicine 2008

5th Biannual Review for Board Preparation, Recertification, and Comprehensive Update

Program Directors: Anthony D. Slonim, MD, DrPH, FCCM and Heidi J. Dalton, MD, FCCM

Location: The Ritz-Carlton, Tysons Corner - McLean, VA Date: April 12-15, 2008

For a full course brochure and on-line registration, please visit www.cbcbiomed.com or call 201-342-5300

luded to in the preceding section, exist. Biodegradable stents or stents that can be expanded to near adult size [81,82] may circumvent this problem. Further studies are awaited to determine the optimum method of management.

Miscellaneous Uses

In some patients with tetralogy of Fallot and MAPCVS, pulmonary oligemia may be relieved by stenting the collateral vessel [83] while awaiting more definitive palliation. Following surgical palliation of pulmonary oligemia with Blalock-Taussig shunts or single ventricle Norwood palliation with Blalock-Taussig or Sano shunts, stenosis may develop at the anastomotic sites or within the connecting Gore-Tex graft, causing hypoxemia. Placement of stents to enlarge the obstructed shunts is feasible and has generally resulted in good outcome [84-88]. An example from our experience is shown in Figure 6. Temporary relief of pulmonary venous obstruction may also be achieved by implantation of stent in the obstructed vertical vein [89].

SUMMARY AND CONCLUSIONS

In this and the previous [1,2] reviews, various transcatheter methodologies available for management of neonates with congenital heart disease have been enumerated and include atrial septostomy procedures, balloon dilatation of stenotic valve or vessel, perforation of atretic pulmonary valve, occlusion of defects or vessels causing cardiac failure and stents to keep open closing fetal circulatory pathways and vascular stenotic lesions. These procedures should complement other medical therapies and surgical interventions. In a given patient, the method selected should be a method that is most likely to provide the best outcome.

References

- Rao PS. Role of interventional cardiology in neonates – Part I - Non-surgical atrial septostomy. *Neonatology Today*. 2007; 2(9): 9-14.
- Rao PS. Role of interventional cardiology in neonates – Part II - Balloon angioplasty/valvuloplasty. *Neonatology Today*. 2007; 2(10): 1-12.
- Cobanoglu A, Metzdorff MT, Pinson CE, et al. Valvotomy for pulmonary atresia with intact ventricular septum. *J Thorac Cardiovasc Surg* 1985; 89: 482-90.
- de Leval M, Bull C, Hopkins R, et al. Decision-making in the definitive repair of the heart with a small right ventricle. *Circulation* 1985; 72 (Suppl. II): 52-60.
- Coles JC, Freedom RM, Lightfoot ME, et al. Long-term results in the neonate with pulmonary atresia and intact ventricular septum. *Ann Thorac Surg* 1989; 47: 213-7.
- Rao PS. Comprehensive management of pulmonary atresia with intact ventricular septum. *Ann Thorac Surg* 1985; 40: 409-13.
- Rao PS, Liebman J, Borkat G. Right ventricular growth in a case of pulmonary stenosis with intact ventricular septum and hypoplastic right ventricle. *Circulation* 1976; 53: 389-94.
- Siblini G, Rao PS, Singh GK, et al. Transcatheter management of neonates with pulmonary atresia and intact ventricular septum. *Cathet Cardiovasc Diagn* 1997; 42: 395-402.
- Rao PS. Pulmonary atresia with intact ventricular septum. *Current Treatment Options in Cardiovasc Med* 2002; 4: 321-36.
- Gorunay V, Piechard F, Delogua AB, et al. Balloon valvotomy for critical stenosis or atresia of pulmonary valve in new-born. *J Am Coll Cardiol* 1995; 26: 1725-31.
- Qureshi SA, Rosenthal E, Tynan M, et al. Transcatheter laser-assisted balloon pulmonary valve dilatation in pulmonary valve atresia. *Am J Cardiol* 1991; 67: 428-31.
- Rosenthal E, Qureshi SA, Tynan M, et al. Radiofrequency-assisted balloon dilatation in patients with pulmonary valve atresia and intact ventricular septum. *Br Heart J* 1993; 69: 347-51.
- Redington AN, Cullens S, Rigby MC. Laser or radiofrequency pulmonary valvotomy in neonates with pulmonary valve atresia and intact ventricular septum: description of a new method avoiding arterial catheterization. *Cardiol Young* 1992; 2: 387-90.
- Parsons JM, Rees MR, Gibbs JL. Percutaneous laser valvotomy with balloon dilatation of the pulmonary valve as a primary treatment for pulmonary atresia. *Br Heart J* 1991; 66: 36-8.
- Schneider M, Schranz D, Michel-Behnke I, Oelert H. Transcatheter radiofrequency perforation for pulmonary atresia in a 3,060 g infant. *Cathet Cardiovasc Diagn* 1995; 34: 42-5.
- Wright SB, Radtke WA, Gillette PC. Percutaneous radiofrequency valvotomy using a standard 5-Fr electrode catheter for pulmonary atresia in neonates. *Am J Cardiol* 1996; 73: 1370-2.
- Akagi T, Hashino K, Maeno Y, et al. Balloon dilatation of the pulmonary valve in a patient with pulmonary atresia with intact ventricular septum using a commercially available radiofrequency catheter. *Pediatr Cardiol* 1997; 18: 61-3.
- Justo RN, Nykanen DG, Williams WG, et al. Transcatheter perforation of the right ventricular outflow tract as initial therapy for pulmonary valve atresia and intact ventricular septum in the newborn. *Cathet Cardiovasc Diagn* 1997; 40: 408-13.
- Humpl T, Söderberg B, McCrindle BW, et al. Percutaneous balloon valvotomy in pulmonary atresia with intact ventricular septum: impact on patient care. *Circulation*. 2003; 108: 826-32.
- Chopra PS, Rao PS. History of development of atrial septal occlusion devices. *Current Intervent Cardiol Reports* 2000; 2: 63-9.
- Rao PS. History of atrial septal occlusion devices. In: Rao PS, Kern MJ (Eds): *Catheter Based Devices for Treatment of Noncoronary Cardiovascular Disease in Adults and Children*. Lippincott, Williams & Wilkins, Philadelphia, PA, 2003: 1-9.
- Rao PS. Summary and comparison of atrial septal closure devices. *Current Intervent Cardiol Reports* 2000; 2: 367-76.
- Rao PS. Comparative summary of atrial septal defect occlusion devices. In: Rao PS, Kern MJ. (Eds) *Catheter Based Devices for Treatment of Noncoronary Cardiovascular Disease in Adults and Children*. Lippincott, Williams & Wilkins, Philadelphia, PA, 2003: 91-101.
- Rao PS. Current status of cardiac interventions for pediatric congenital heart disease – Part II: Percutaneous closure of cardiac septal defects. *Pediatric Cardiology Newsletter* 2004; 6(2): 1-5.
- Rao PS. History of transcatheter patent ductus arteriosus closure devices. In: Rao PS, Kern MJ (Eds): *Catheter Based Devices for the Treatment of Noncoronary Cardiovascular Disease in Adults and Children*. Lippincott, Williams & Wilkins, Philadelphia, PA, 2003: 145-53.
- Rao PS. Summary and comparison of patent ductus arteriosus closure devices. *Current Intervent Cardiol Reports* 2001; 3: 268-74.
- Rao PS. Summary and comparison of patent ductus arteriosus closure methods. In: Rao PS, Kern MJ (Eds): *Catheter Based Devices for the Treatment of Noncoronary Cardiovascular Disease in Adults and Children*.

- Lippincott, Williams & Wilkins, Philadelphia, PA, 2003: 219-28.
28. Berenstein A, Kricheff II. Catheter and material selection for transcatheter embolization: technical considerations. I. Catheters. *Radiology* 1979;132: 616-30.
 29. Berenstein A, Kricheff II. Catheter and material selection for transcatheter embolization: technical consideration. II. Materials. *Radiology* 1979; 132: 631-42.
 30. Gianturco C, Anderson JH, Wallace S. Mechanical device for arterial occlusion. *Am J Roentgen* 1975; 124: 428-35.
 31. Siblini G, Rao PS. Coil embolization in the management of cardiac problems in children. *J Invasive Cardiol* 1996; 8: 332-40.
 32. Rao PS. Transcatheter embolization of unwanted blood vessels in children. In: Rao PS, Kern MJ (Eds): *Catheter Based Devices for the Treatment of Noncoronary Cardiovascular Disease in Adults and Children*. Lippincott, Williams & Wilkins, Philadelphia, PA, 2003: 219-28.
 33. DeParades CG, Pierce WS, Johnson DG, Waldhausen JA. Pulmonary sequestration in infants and children: a 20-year experience and review of the literature. *J Pediatr Surg* 1970; 5: 136-47.
 34. Neill CA, Ferencz C, Sabiston DC, Shelden H. The familial occurrence of hypoplastic right lung with systemic arterial supply and venous drainage "Scimitar syndrome". *Bulletin Johns Hopkins Hosp* 1960; 167: 1-21.
 35. Mardini MK, Rao PS. Scimitar syndrome: experience with four patients and review of literature. *Arab J Med* 1984; 3: 13-23.
 36. Dickinson DF, Galloway RW, Massey R, et al. Scimitar syndrome in infancy: role of embolization of systemic arterial supply to right lung. *Br Heart J* 1982; 47: 468-72.
 37. Park ST, Yoon CH, Sung K, et al. Pulmonary sequestration in a newborn infant: treatment with arterial embolization. *J Vasc Intervent Radiol* 1998; 9: 668-70.
 38. Tokel K, Boyvat F, Varan B. Coil embolization of pulmonary sequestration in two infants: a safe alternative to surgery. *Am J Radiol* 2000; 175: 993-5.
 39. Perry SB, Radtke W, Fellows KE, et al. Coil embolization to occlude aortopulmonary collateral vessels and shunts in patients with congenital heart disease. *J Am Coll Cardiol* 1989; 13: 104-8.
 40. Rothman A, Tong AD. Percutaneous coil embolization of superfluous connections in patients with congenital heart disease. *Am Heart J* 1993; 126: 206-13.
 41. Dotter CT, Judkins MP. Transluminal treatment of atherosclerotic obstruction. *Circulation* 1964; 30: 654-70.
 42. Dotter CT. Transluminally placed coil spring endarterial tube grafts. *Invest Radiol* 1969; 4: 329-32.
 43. Palmaz JC, Windeler SA, Garcia F, et al. Atherosclerotic rabbit aortas: expandable intraluminal grafting. *Radiol* 1986; 160: 723-6.
 44. Sigwart W, Puel J, Mirkowich V, et al. Intravascular stents to prevent occlusion and restenosis after transluminal angioplasty. *New Engl J Med* 1987; 316: 701-6.
 45. Palmaz JC, Richter GM, Noeldge G, et al. Intraluminal stents in atherosclerotic iliac artery stenosis: preliminary report of a multicenter study. *Radiology* 1988; 168: 727-31.
 46. Mullins CE, O'Laughlin MP, Vick GW, III, et al. Implantation of balloon expandable intravascular grafts by catheterization in pulmonary arteries and systemic veins. *Circulation* 1988; 77: 189-99.
 47. O'Laughlin MP, Perry SB, Lock JE, et al. Use of endovascular stents in congenital heart disease. *Circulation* 1991; 83: 1923-39.
 48. Rao PS. Stents in the management of congenital heart disease in the pediatric and adult patients. *Indian Heart J* 2001; 53: 714-30.
 49. Rao PS, Thapar MK. Balloon dilatation of other congenital and acquired stenotic lesions of the cardiovascular system. In Rao PS (Ed): *Transcatheter Therapy in Pediatric Cardiology*, Wiley-Liss, New York, NY, 1993: 275-319.
 50. Coe JY, Olley PM. A novel method to maintain ductus arteriosus patency. *J Am Coll Cardiol* 1991; 18: 837-41.
 51. Moore JW, Kirby WC, Lovett EJ, O'Neill JT. Use of an intravascular endoprosthesis (stent) to establish and maintain short-term patency of the ductus arteriosus in newborn lambs. *Cardiovasc Intervent Radiol* 1991; 14: 299-301.
 52. Rosenthal E, Qureshi SA, Kakadekar AP, et al. Comparison of balloon dilatation and stent implantation to maintain patency of the neonatal arterial ducts in lambs. *Am J Cardiol* 1993; 71: 1373-6.
 53. Hijazi ZM, Aronovitz MJ, Marx GR, Fulton DR. Successful placement and re-expansion of a new balloon expandable stent to maintain patency of the ductus arteriosus in a newborn animal model. *J Invasive Cardiol* 1993; 5: 351-7.
 54. Gibbs JL, Rothman MT, Rees MR, et al. Stenting of the arterial duct: a new approach to palliation for pulmonary atresia. *Br Heart J* 1992; 67: 240-5.
 55. Schneider M, Zartner P, Sidiropoulos A, et al. Stent implantation of the arterial duct in newborns with duct-dependent circulation. *Eur Heart J* 1998; 19: 1401-9.
 56. Rosenthal E, Qureshi SA, Tynan M. Percutaneous pulmonary valvotomy and arterial duct stenting in neonates with right ventricular hypoplasia. *Am J Cardiol* 1994; 74: 304-6.
 57. Zahn EM, Lima VC, Benson LN, et al. Use of endovascular stents to increase pulmonary blood flow in pulmonary atresia with ventricular septal defect. *Am J Cardiol* 1992; 70: 411-2.
 58. Ruiz CE, Gamra H, Zhang P, et al. Stenting of the ductus arteriosus as a bridge to cardiac transplantation in infants with hypoplastic left heart syndrome. *New Engl J Med* 1993; 328: 1605-8.
 59. Gibbs JL, Wren C, Watterson KG, et al. Stenting of the arterial duct combined with banding of the pulmonary arteries and atrial septectomy or septostomy: a new approach to palliation for the hypoplastic left heart syndrome. *Br Heart J* 1993; 69: 551-5.
 60. Michel-Behnke I, Akintuerk H, Marquardt I, et al. Stenting of the ductus arteriosus and banding of the pulmonary arteries: basis for various surgical strategies in newborns with multiple left



Cardiostim 2008

June 18-21, 2008

Nice Acropolis - French Riviera

16th World Congress in Cardiac Electrophysiology and Cardiac Techniques

For more information and registration: www.cardiostim.fr



- heart obstructive lesions. *Heart*. 2003; 89: 645-50.
61. Boucek MM, Mashburn C, Chan KC. Catheter-based intervention palliation for hypoplastic left heart syndrome. *Semin Thorac Cardiovasc Surg Pediatr Card Surg Annu*. 2005;72-7.
 62. Galantowicz M, Cheatham JP. Lessons learned from the development of a new hybrid strategy for the management of hypoplastic left heart syndrome. *Pediatr Cardiol*. 2005 ;26: 190-9.
 63. Lim DS, Peeler BB, Matherne GP, et al. Risk-stratified approach to hybrid transcatheter-surgical palliation of hypoplastic left heart syndrome. *Pediatr Cardiol*. 2006 ;27 :91-5.
 64. Gibb JL. Stenting the arterial duct. *Arch Dis Child* 1995; 72: 196-7.
 65. Gibbs JL, Orhan U, Blackburn MEC, et al. Fate of stented arterial duct. *Circulation* 1999; 99: 2621-5.
 66. Alwi M, Choo KK, Latiff HA, et al. Initial results and medium-term follow-up of stent implantation of patent ductus arteriosus in duct-dependent pulmonary circulation. *J Am Coll Cardiol*. 2004; 44: 438-45.
 67. Boucek MM, Mashburn C, Kunz E, Chan KC. Ductal anatomy: a determinant of successful stenting in hypoplastic left heart syndrome. *Pediatr Cardiol*. 2005; 26: 200-5.
 68. Ilin MV, Jaeggi ET, Lee KJ. Neonatal rhabdomyoma causing right ventricular inflow obstruction with duct-dependent pulmonary blood flow: successful stenting of PDA. *Catheter Cardiovasc Interv*. 2007 ;69 :881-5.
 69. Sivakumar K, Francis E, Krishnan P, Shahani J. Ductal stenting retrains the left ventricle in transposition of great arteries with intact ventricular septum.. *J Thorac Cardiovasc Surg*. 2006; 132 :1081-6.
 70. Reddington AN, Booth P, Shore DF, Rigby ML. Primary balloon dilatation of coarctation in neonates. *Br Heart J* 1990; 64: 277-81.
 71. Rao PS, Galal O, Smith PA, Wilson AD. Five-to-nine-year follow-up results of balloon angioplasty of native aortic coarctation in infants and children. *J Am Coll Cardiol* 1996; 27: 462-70.
 72. Rao PS. Current status of balloon angioplasty for neonatal and infant aortic coarctation. *Progress Pediatr Cardiol* 2001; 14: 35-44.
 73. Rao PS, Jureidini SB, Balfour IC, et al. Severe aortic coarctation in infants less than 3 months: Successful palliation by balloon angioplasty. *J Intervent Cardiol* 2003; 15: 203-8.
 74. Rao PS. Balloon angioplasty for native aortic coarctation in neonates and infants. *Cardiology Today* 2005; 9: 94-9.
 75. Suarez de Lezo J, Pan M, Romero M, et al. Balloon-expandable stent repair of severe coarctation of aorta. *Am Heart J* 1995; 129: 1002-8.
 76. Suarez de Lezo J, Pan M, Romero M, et al. Immediate and follow-up findings after stent treatment for severe coarctation of aorta. *Am J Cardiol* 1999; 83: 400-6.
 77. Ballweg J, Liniger R, Rocchini A, Gajarski R. Use of Palmaz stents in a newborn with congenital aneurysms and coarctation of the abdominal aorta. *Catheter Cardiovasc Interv*. 2006; 68: 648-52.
 78. Al-Ata J, Arfi AM, Hussain A, et al. Stent angioplasty: an effective alternative in selected infants with critical native aortic coarctation. *Pediatr Cardiol*. 2007; 28 :183-92.
 79. Tamai H, Igaki K, Dyo E, et al. Initial and 6-month results of biodegradable poly-L-lactic acid coronary stents in humans. *Circulation* 2000; 102: 399-404.
 80. Schranz D, Zartner P, Michel-Behnke I, Akintürk H. Bioabsorbable metal stents for percutaneous treatment of critical recoarctation of the aorta in a newborn. *Catheter Cardiovasc Interv*. 2006; 67: 671-3.
 81. Zeidenweber CM, Kim DW, Vincent RN. Right ventricular outflow tract and pulmonary artery stents in children under 18 months of age. *Catheter Cardiovasc Interv*. 2007; 69: 23-7.
 82. Stanfil, R, Nykanen D, Osario S, Et Al. Long-term follow-up of stents placed in infants with congenital heart disease (Abstract). *Catheter Cardiovasc Interv*. 2007; 70: S1.
 83. McLeod KA, Blackburn ME, Gibbs JL. Stenting of stenosed aortopulmonary collateral: a new approach to palliation in pulmonary atresia with multifocal aortopulmonary blood supply. *Br Heart J* 1994; 71: 487-9.
 84. Alcibar J, Cabrera A, Martinez P, et al. Stent implantation in a central aortopulmonary shunt. *J Invasive Cardiol* 1999; 11: 506-9.
 85. Zahn EM, Chang AC, Aldousany A, et al. Emergent stent placement for acute Blalock-Taussig shunt obstruction after stage I Norwood surgery. *Cathet Cardiovasc Diagn* 1997; 42: 191-4.
 86. Eicken A, Genz T, Sebening W. Stenting of stenosed shunts in patients after a Norwood-Sano operation. *Catheter Cardiovasc Interv*. 2006; 68 :301-3.
 87. Petit CJ, Gillespie MJ, Kreutzer J, Rome JJ. Endovascular stents for relief of cyanosis in single-ventricle patients with shunt or conduit-dependent pulmonary blood flow. *Catheter Cardiovasc Interv*. 2006; 68: 280-6.
 88. Muyskens S, Foerster S, Balzer D. RV to PA conduit stenoses in the Norwood with Sano modification: an institutional experience with endovascular stenting. *Catheter Cardiovasc Interv*. 2007; 70: S3.
 89. Lo-A-Njoe SM, Blom NA, Bökenkamp R, Ottenkamp J. Stenting of the vertical vein in obstructed total anomalous pulmonary venous return as rescue procedure in a neonate. *Catheter Cardiovasc Interv*. 2006; 67: 668-70.

CCT

P. Syamasundar Rao, MD
Professor and Director, Division of Pediatric Cardiology
University of Texas/Houston Medical School
6431 Fannin, MSB 3.130
Houston, TX 77030 USA
(P) 713-500-5738; (F): 713-500-5751
P.Syamasundar.Rao@uth.tmc.edu



17th Utah Conference on Congenital Cardiovascular Disease

February 24 – 27, 2008

The Cliff Lodge at Snowbird Ski Resort, Snowbird, Utah

Please visit our web site: www.primarychildrens.com/medicalclasses and download a PDF file of the registration form.



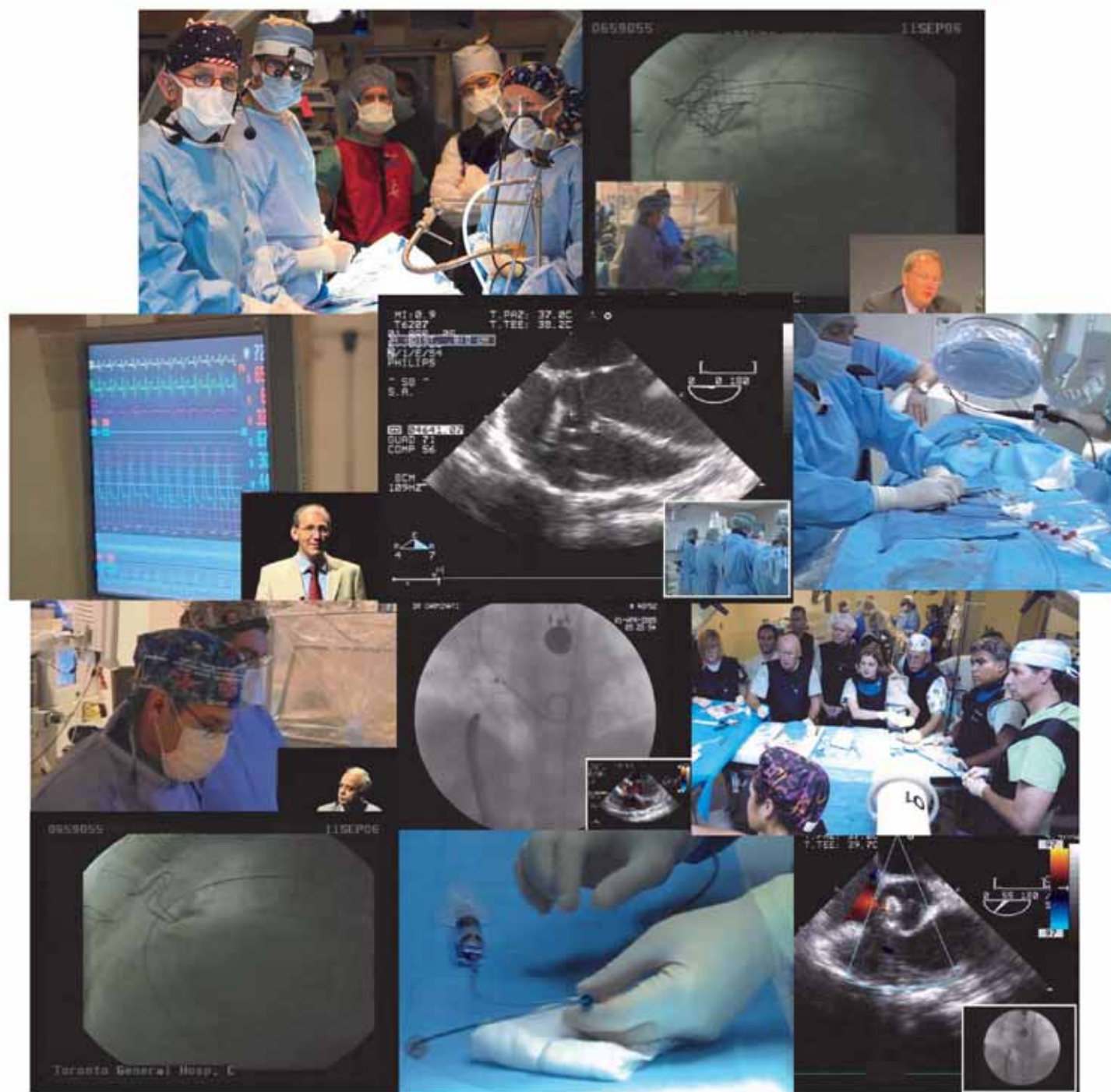
WATCH SELECTED LIVE CASES
on the web www.CHDVideo.com

Live Cases Produced and Provided by

International Symposium on the Hybrid Approach to Congenital Heart Disease (ISHAC)

Pediatric and Adult Interventional Therapies for Congenital and Valvular Disease (PICS)

The International Workshop on Interventional Pediatric Cardiology (WorkshopIPC)



If you would like to be notified when other videos in the series are available, please send an email to:

LiveCases@CHDVideo.com

Video Live Cases Hosted by **Congenital** Cardiology Today

Congenital Cardiology at ACC.08: Exciting New Program Planned

By John W. Moore, MD, and John F. Rhodes, Jr., MD

Past Annual Scientific Sessions of the American College of Cardiology may have included a strong pediatric and congenital heart disease program track, but this year ACC.08 sets the bar higher by adding on the third day "Congenital Cardiology Solutions 2008" or CCS.08, an exciting new program for those who specialize or are interested in pediatric and adult congenital interventional cardiac catheterization. Inspired by efforts of the ACC Pediatric Cardiology and Adult Congenital Heart Disease Section, CCS.08 will offer a unique blend of traditional programs associated with congenital heart disease and pediatric cardiology topics as well as state of the art and live interventional case presentations on new or controversial interventions. General ACC.08 Sessions for Pediatric and Adult Congenital Heart Disease will begin on Sunday, March 30th and continue through Monday, March 31st. Then, CCS.08 will be held all day on Tuesday, April 1st.

ACC.08 sessions begin on Sunday with a symposium on issues of transition of pediatric CHD patients to adult CHD clinics, co-chaired by Gary Webb, MD, FACC, and Susan Fernandes, MD, and a Meet the Experts Session on Pediatric Circulatory Support Options. Additional symposia will include case presentations, right ventricular outflow tract issues and arrhythmias in adults with CHD, chaired by Ronald Kanter, MD, FACC. Other sessions that day include a congenital surgical technique and outcome session using videos as well as pregnancy and CHD.

On Monday, the program includes an excellent symposium on translational medicine in childhood heart disease co-chaired by Bruce D. Gelb, MD, and Jeffrey A. Towbin, MD, FACC. Other scheduled symposia for Monday include:

- **Evaluation and Management of Congenital Pulmonary Vein Stenosis** - Co-chairs: Chris Caldarone, MD, and Kathy Jenkins, MD, FACC.
- **Sudden Cardiac Death in the Young Athlete** - Co-chairs: Barry J. Maron, MD, FACC, and Francis R. Gilliam II, MD, FACC.

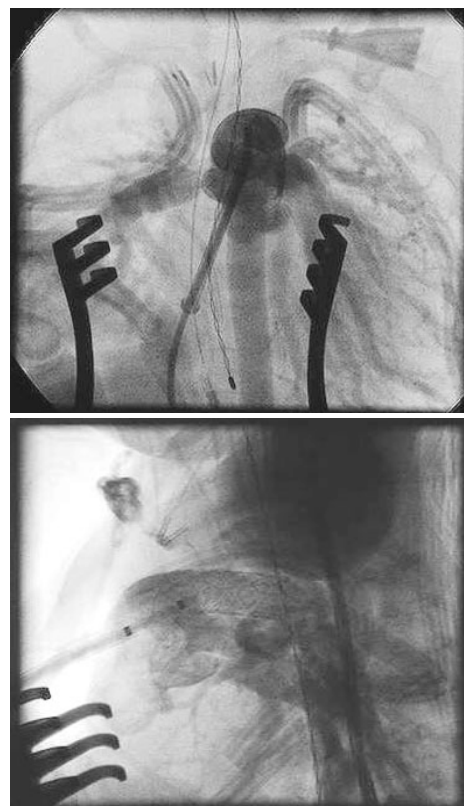
- **Can We Fix Secondary Pulmonary Hypertension?** - Co-chairs: Robyn J. Barst, MD, FACC, and David D. Ivy, MD, FACC.
- **Long-Term Outcomes of Aortic Coarctation Repair Strategies** - Co-chairs: Michael Landzberg, MD, FACC, and Gary D. Webb, MD, FACC.

The CCS.08 live interventional case programming on Tuesday will focus on new and/or controversial interventions. The live case presentations will be led by John Cheatham, MD, FACC, and James Lock MD, FACC.

In the morning session, the first interventional case will be a patient with coarctation of the aorta, who will undergo stent implantation. John Cheatham, MD, FACC, and his associates will demonstrate the procedure, transmitting from the Nationwide Children's Hospital in Columbus, Ohio. The discussions will address the risk and outcome of coarctation stenting and angioplasty, indications for using covered stents and redilation of aortic stents years after implantation and coarctation stenting in older patients. The second morning session case will be a patient with Tetralogy of Fallot after repair with pulmonic insufficiency and impending right ventricular failure. James Lock, MD, FACC, and Audrey C. Marshall, MD, at Boston Children's Hospital will demonstrate implantation of a Medtronic/Bonhoeffer Stent Valve.

In-between live cases there will be a session focusing on recently completed or ongoing FDA trials of devices designed for treatment of congenital heart defects as well as new techniques available to the pediatric and adult congenital patient.

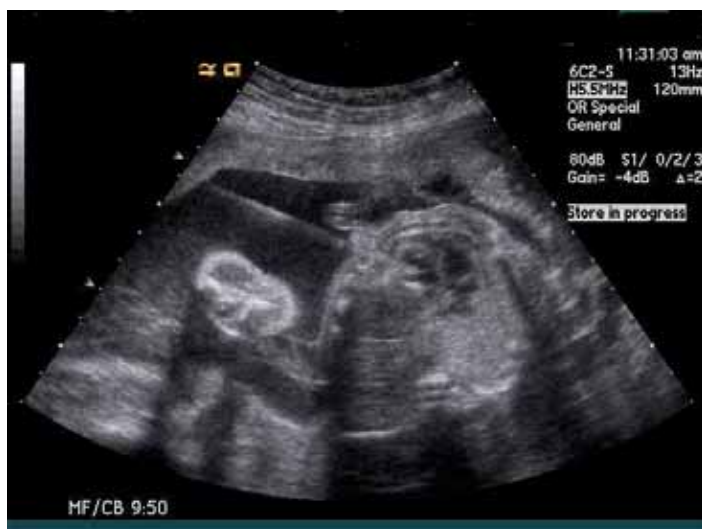The afternoon session will feature cutting-edge procedures, which are performed and advocated by only a small number of centers. The first afternoon live case will be a patient with hypoplastic left heart syndrome undergoing a Hybrid Palliation and Fetal Valvuloplasty, again performed by John Cheatham, MD. The second afternoon case, which will be equally controversial, involves James Lock, MD, FACC, and Audrey C. Marshall, MD, at Boston Children's Hospital performing a live fetal intervention.



The Program will feature a live Hybrid Procedure from Nationwide Children's Hospital. (Figure shows AP [top] and LAT [bottom] Cineangiogram Frames of Hybrid Palliation of HLHS courtesy of John Moore, MD, Rady Children's Hospital, San Diego).

CCS.08 promises to be one of ACC.08's most exciting program additions. Developed by pediatric and adult congenital heart disease cardiologists and surgeons, it is designed to address quality, collaboration and long term patient care issues that are faced regularly by pediatric cardiologists, adult congenital cardiologists, congenital interventional cardiologists and cardiac surgeons.

One of the major goals of this CCS.08 congenital interventional programming is to complement the congenital sessions offered by the combined I2/SCAI program which will also be at the Chicago Convention Center on March 30th and 31st along with the main ACC Meeting. The I2/SCAI Program will feature a congenital interventional track which combined with the



The Program will feature a live fetal intervention from Boston Children's Hospital. (Echo frame shows needle perforation of fetal left ventricle courtesy of Wayne Tworetzky, MD, Children's Hospital Boston).

CCS.08 interventional day can comprise a full three day congenital interventional meeting. Combined registration is available through links in the ACC or the SCAI websites.

Advance registration closes February 20, 2008. Register for Congenital Cardiology Solutions and plan your educational experience online at www.acc08.acc.org.

Moore is chair and Rhodes is a member of the CCS.08 planning committee.

Reprinted and modified slightly with permission from the ACC's publication, Cardiology.

CCT

Corresponding Author

John W. Moore, FACC, FSCAI
Rady Children's Hospital and
University of California, San Diego
jmoore@rchsd.org

John F. Rhodes, Jr., MD, FACC
Duke University Medical Center

CONTEGRA[®]

Pulmonary Valved Conduit



A natural tissue conduit
worthy of your pediatric
RVOT needs

CONTEGRA[®] Pulmonary Valved Conduit

Indications: See "Humanitarian Use Device" section below.

Contraindications: None known. Warnings/Precautions/Side Effects: Acceptable clinical performance has been established for the CONTEGRA conduit in pediatric patients under the age of 10. Because of the possibility that complications of the device could become apparent only after extended use, a benefit-risk consideration of the long-term use of the CONTEGRA conduit in pediatric patients over 10 years of age is particularly important. General complications reported with valved conduits and biological tissue valves implanted in the heart include: hemorrhage, bleeding diathesis due to use of anticoagulants, residual or increasing transvalvular gradients, progressive neointimal thickening and peeling, progressive stenosis and obstruction, progressive pulmonary hypertension, graft infection, endocarditis, regurgitation, hemolysis, valve malfunction, physical or chemical deterioration, thromboembolism, thrombus, conduit dilatation. For additional information, please refer to the Instructions For Use provided with the product. CAUTION: Federal law (USA) restricts this device to sale by or on the order of a physician.

"Humanitarian Use Device"

Authorized by Federal law for use in patients under 18 years of age for correction or reconstruction of the Right Ventricular Outflow Tract (RVOT) in the following congenital heart malformations: Pulmonary Stenosis, Tetralogy of Fallot, Truncus Arteriosus, Transposition with Ventricular Septal Defect (VSD), Pulmonary Atresia. In addition, the CONTEGRA Pulmonary Valved Conduit is indicated for the replacement of previously implanted but dysfunctional pulmonary homografts or valved conduits. The effectiveness of this device for these uses has not been demonstrated.

UC20080101 IN © Medtronic, Inc. 2007



Medtronic

Alleviating Pain • Restoring Health • Extending Life

Do you Want to Recruit a Pediatric Cardiologist?

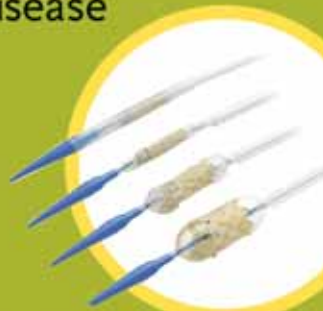Advertise in Congenital Cardiology Today, the only monthly publication totally dedicated to pediatric and congenital cardiology.

For more information send an email to: TCarlsonmd@mac.com

MELODY™
Transcatheter Pulmonary Valve
ENSEMBLE™
Transcatheter Delivery System



Providing new options
for the lifetime management
of patients with congenital
heart disease



The Melody™ Transcatheter Pulmonary Valve and Ensemble™ Transcatheter Delivery system have received CE Mark approval and are available for distribution in Europe. Additionally, a Medical Device Licence has been granted and the system is available for distribution in Canada. Products are not available for sale in the United States.

UC200801936 EE © Medtronic, Inc. 2007




Medtronic

Alleviating Pain • Restoring Health • Extending Life



Heart Valves • Cannulae • Oxygenators & Filters
RVOT Conduits • Ablation Technologies • Pacemakers • ICDs

*Committed to providing more options
for the lifetime care of patients
with congenital heart disease.*



UC200802144 EN © Medtronic, Inc. 2007



Medtronic

Alleviating Pain • Restoring Health • Extending Life

CSI 2008 Congenital and Structural Interventions
Frankfurt, Germany June 25-28 2008



Congenital and Structural Interventions with live case demonstrations from Frankfurt and Hands on Workshops.
For more information: <http://www.csi-congress.org/>



Medical News, Products and Information

Rush University Medical Center Investigating Whether a Heart Procedure May Be Key To Relieving Migraines

Interventional cardiologists at Rush University Medical Center are investigating whether a heart procedure may be the key to relieving migraines in patients with severe headaches.

Earlier studies have indicated that there may be a link between a particular congenital heart anomaly, a patent foramen ovale (PFO), and migraine. Some patients – particularly those suffering from migraine with aura – have had reductions in the frequency and severity of migraines following closure of their PFO. In the Rush study, interventional cardiologists will close the PFO in the catheterization lab using an implant that acts like an umbrella, crossing over the chambers in attempt to occlude or close the flaps together.

Principal investigator Dr. Clifford Kavinsky and his team have started enrolling patients for the clinical trial, called MIST II (Migraine Intervention with BioSTAR). The team is looking for individuals with severe migraines to see if they may have a patent foramen ovale.

"In a smaller predicate trial of similar design conducted in the United Kingdom, headache specialists observed a significant treatment effect with 42% of patients experiencing a 50% reduction in migraine headache days and 37% reduction in frequency and duration of migraine attacks," says Kavinsky. "The combination of the bioabsorbable septal repair implant and the longer duration of the MIST II Trial are expected to provide even more positive outcomes. Finding an effective therapy for this group of patients who are refractory to medical therapy would be an important advance in the treatment of migraine."

The trial is a prospective, randomized, multi-center, controlled study. The double-blinded trial is designed to randomize approximately 600 migraine patients with a PFO to either PFO clo-

sure with the bioabsorbable technology or a control arm.

For additional information:
www.pfo-migraine.com.



The American College of Cardiology presents

CCS.08
Congenital Cardiology Solutions

Launching at ACC.08! March 29 – April 1, 2008 Chicago

Featuring a full day of groundbreaking cases including —

- Coarctation of the aorta
- Pulmonary stent valve implantation
- Hybrid surgical/interventional procedures
- Interventions in the developing fetus

Plus in-depth educational sessions with on-site experts.

Advance registration closes Feb. 20!

Visit www.acc08.acc.org/ccs08 for more information.

A08187 © ACC, 2008

CONGENITAL CARDIOLOGY TODAY

© 2008 by Congenital Cardiology Today
ISSN: 1544-7787 (print); 1544-0499 (online).
© 2007 by Congenital Cardiology Today
(ISSN 1544-7787-print; ISSN 1544-0499-online). Published monthly. All rights reserved.

Headquarters

9008 Copenhaver Dr. Ste. M
Potomac, MD 20854 USA

Publishing Management

Tony Carlson, Founder & Editor

TCarlsonmd@mac.com

Richard Koulbanis, Publisher & Editor-in-Chief

RichardK@CCT.bz

John W. Moore, MD, MPH, Medical Editor/

Editorial Board

JMoore@RCHSD.org

Jeffrey Green, Contributing Editor

Editorial Board

Teiji Akagi, MD

Zohair Al Halees, MD

Mazeni Alwi, MD

Felix Berger, MD

Fadi Bitar, MD

Jacek Bialkowski, MD

Philipp Bonhoeffer, MD

Mario Carminati, MD

Anthony C. Chang, MD, MBA

John P. Cheatham, MD

Bharat Dalvi, MD, MBBS, DM

Horacio Faella, MD

Yun-Ching Fu, MD

Felipe Heusser, MD

Ziyad M. Hijazi, MD, MPH

Ralf Holzer, MD

Marshall Jacobs, MD

R. Krishna Kumar, MD, DM, MBBS

Gerald Ross Marx, MD

Tarek S. Momenah, MBBS, DCH

Toshio Nakanishi, MD, PhD

Carlos A. C. Pedra, MD

Daniel Penny, MD

James C. Perry, MD

P. Syamasundar Rao, MD

Shakeel A. Qureshi, MD

Andrew Redington, MD

Carlos E. Ruiz, MD, PhD

Girish S. Shirali, MD

Horst Sievert, MD

Hideshi Tomita, MD

Gil Wernovsky, MD

Zhuoming Xu, MD, PhD

William C. L. Yip, MD

Carlos Zabal, MD

FREE Subscription

Congenital Cardiology Today is available free to qualified professionals worldwide in pediatric and congenital cardiology. International editions available in electronic PDF file only; North American edition available in print. Send an email to Subs@CCT.bz. Include your name, title, organization, address, phone and email.

Contacts and Other Information

For detailed information on author submission, sponsorships, editorial, production and sales contact, current and back issues, see website or send an email to:

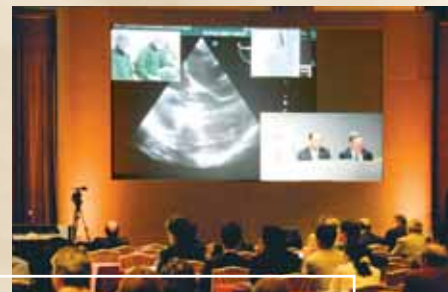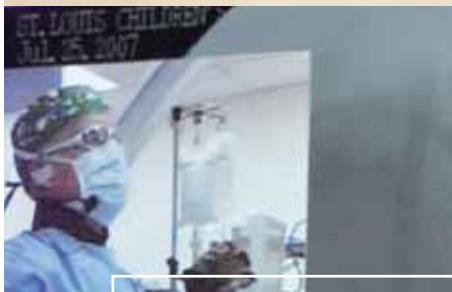INFO@CCT.bz.

REVISED DATE

PICS-AICS 08

July 20-23, 2008
Bellagio, Las Vegas

PEDIATRIC AND ADULT INTERVENTIONAL CARDIAC SYMPOSIUM



Course Directors: Dr. Ziyad M. Hijazi, Dr. William E. Hellenbrand, Dr. John P. Cheatham, & Dr. Carlos Pedra

- **FOCUSING ON THE LATEST ADVANCES IN INTERVENTIONAL THERAPIES FOR CHILDREN AND ADULTS** with congenital and structural heart disease, including the latest technologies in devices, implantable valves, stents and balloons. Special sessions will provide an in-depth focus on septal defect closure, coarctation stenting, hybrid intervention for HLHS and fetal intervention.
 - **SPECIAL SESSIONS** will be dedicated to the care of adults with congenital heart disease.
 - **HOT DAILY DEBATES** between cardiologists and surgeons on controversial issues in intervention for congenital and structural heart disease.
 - The popular session of **"MY NIGHTMARE CASE IN THE CATH LAB"**
 - **LIVE CASE DEMONSTRATIONS** featuring approved and non-approved devices will be transmitted daily from many cardiac centers around the world. During these live cases, the attendees will have the opportunity to interact directly with the operators to discuss the management options for these cases.
 - **BREAKOUT SESSIONS** for cardiovascular nurses and CV technicians.
 - **MEET THE EXPERT SESSION**, held on Sunday, will give attendees the opportunity to discuss difficult cases with our renowned faculty.
- ACCREDITATION** The Society for Cardiovascular Angiography and Interventions is accredited by the Accreditation Council for Continuing Medical Education (ACCME) to sponsor continuing medical education for physicians.

Abstract Submission Deadline is March 15, 2008.

For registration and abstract submission go online to www.picsymposium.com

