CONGENITAL CARDIOLOGY TODAY

Timely News and Information for BC/BE Congenital/Structural Cardiologists and Surgeons

October 2015; Volume 13; Issue 10
International Edition

IN THIS ISSUE

CONGENITAL CARDIOLOGY TODAY
Editorial and Subscription Offices
16 Cove Rd, Ste. 200
Westerly, RI 02891 USA
www.CongenitalCardiologyToday.com

Cardiac CTA with 3D Reconstruction for Diagnosing Bilateral Patent Ductus Arteriosi: A Case Series

Kimberly J. Lavin, MD; Erin E. Birmingham, MD; Randy R. Richardson, MD

Key Words: Bilateral Patent Ductus Arteriosus, Cardiac Computed Tomography Angiography, Transthoracic Echocardiogram

Introduction

A ductus arteriosus is a normal prenatal vascular connection between the descending aorta or brachiocephalic artery and the pulmonary artery. The ductus arteriosus arises from the distal sixth aortic arch at six-gestational weeks and contributes to 60% of fetal cardiac output throughout the pregnancy.[1] The continuity of intrauterine life is partially dependent on the ductus arteriosus shunting blood from the right ventricular outflow tract to bypass the pulmonary arteries when the lungs are not yet participating in gas exchange. It commonly closes a few days after birth due to a decrease in the concentration of prostaglandins.

A Patent Ductus Arteriosus (PDA) is one of the most common cardiac congenital malformations and occurs when this connection remains open postnatally. On rare occasions, two patent ductus arteriosi arise instead of just one, known as bilateral patent ductus arteriosi. In these instances, the abnormal vascular connections tend to arise from both the aorta and left brachiocephalic artery and terminate directly into their corresponding main pulmonary artery .[2, 3]

These bilateral patent ductus arteriosi are also susceptible to closure within the first few days of life. Initially patent ductal preservation is accomplished with prostaglandin E1. This treatment is usually temporary until surgical repair or palliation is possible. Having a reliable image of the cardiac anatomy and correct diagnosis of this cardiac condition is necessary for initiation and completion of the appropriate interventions.

Most patients presenting with the signs and symptoms of congenital cardiac malformations receive a transthoracic echocardiogram (TTE) first, due to the convenience and low risk associated with this procedure. It is important to note that Dorfman et al reported that a TTE has a higher incidence of clinically important diagnostic errors in premature and low-birthweight infants with structural congenital heart disease indicating a need for additional cardiac imaging in this patient population.[4]

Computed Tomography Angiography (CTA) is a cross-sectional imaging modality that has proven to be useful in the diagnosis of great vessel obstruction, cardiac shunts and complex congenital cardiac anomalies due to its high spatial and temporal resolution.[5] This imaging modality allows for visualization of small structures while minimizing artifact.[5] Furthermore, the isotropic voxels of CTA enable reconstructions with high resolution to create 3D images using various software programs.[5] These 3D reconstructed images are useful in the diagnosis and plans for surgical intervention of congenital heart malformations.

The literature surrounding bilateral patent ductus arteriosi is primarily comprised of individual case reports with no epidemiologic studies reporting on this congenital

PROVEN PERFORMANCE. SIMPLY DELIVERED.

MELODY TPV DELAYS CONDUIT REPLACEMENT

98%
Patients at 2 years

91%
Patients at 5 years

Data from US IDE Study

Melody®
Transcatheter Pulmonary Valve Therapy

For a listing of indications, contraindications, precautions, warnings, and potential adverse events, please refer to the Instructions for Use.

Melody-TPV.com

Europe
Medtronic International Trading Sàrl
Route du Molliau 31
Case postale 84
CH-1131 Tolochenaz
Switzerland
Tel: 41.21.802.7000
Fax: 41.21.802.7900

LifeLine
CardioVascular Technical Support
Tel: (877) 526-7890
E-mail: rs.cstechsupport@medtronic.com

Medtronic
Further, Together

malformation's prevalence. Inaccurate diagnosis secondary to poor visualization on echocardiogram, rarity of the disease, and confounding comorbidities may contribute to the lack of literature available. This investigation compiled the largest number of bilateral patient ductus arteriosi in one study thus far. In combination with an extensive literature review, we hope to present an imaging modality that can consistently be used to diagnose this congenital malformation, which will lead to a better understanding of the disease process and management.

Materials and Methods

The institutional review board of St. Joseph's Hospital and Medical Center approved the retrospective review of patient data for this study. We reviewed the medical records of four neonates at St. Joseph's Hospital and Medial Center with the diagnosis of bilateral patent ductus arteriosi. All four patients underwent diagnostic imaging with TTE and CTA with 3D reconstruction for the evaluation of "multiple cardiac anomalies" or "complex congenital heart disease." Literature was accessed through PubMed searching using the phrase "bilateral patent ductus arteriosi."

Case Series

Case 1

This male patient was born to a 37-year-old G1P0 mom at 39 weeks, weighing 2973 grams. Prenatal ultrasound indicated a complex congenital heart defect. The patient initially had decreased breath sounds and a pale, very quiet heart rate of 100 beats per minute. APGAR scores were 7 at one minute and 8 at five minutes. Initial oxygen saturations were 80% pre- and post-ductally. PGE was started, as well as Lovenox for a large thrombus in the left main pulmonary artery.

Initial echocardiogram findings reported a single tortuous PDA along with dextrocardia, an unbalanced AV canal defect with a dominant right ventricle and small left ventricle, and a large ostium primum ASD. There was also evidence of supracardiac total anomalous pulmonary venous return, draining into the right vertical vein to the innominate vein, moderate atrioventricular valve regurgitation, and pulmonary atresia.

When cardiac CTA with 3D reconstruction was performed a bilateral patent ductus arteriosi was clearly evident with the left-sided PDA arising from the brachiocephalic artery and the right-sided PDA arising from the undersurface of the aortic arch (Figure 1). Other congenital defects reported by CTA were: situs inversus, a left-sided IVC and SVC, total anomalous pulmonary venous return, a single large ventricle, and the morphologic right coronary artery arising on the left from the non-coronary sinus.

The patient was taken to the operating room onDay 12 of Life for repair of anomalous pulmonary venous return, unifocalization, and placement of modified Blalock-Taussig shunt from the innominate artery to the unifocalized pulmonary artery. However, during a sternal closure, the patient decompensated and was placed on ECMO in critical condition. Head CT around this time showed severe diffuse ischemic injury of the cerebral hemispheres bilaterally secondary to hemorrhagic stroke. At this time the family decided to withdraw care.

Case 2

This male patient was born to a 20-year-old G1P0 mom, who delivered via C-section for a failed induction of labor. APGAR scores were 9 at

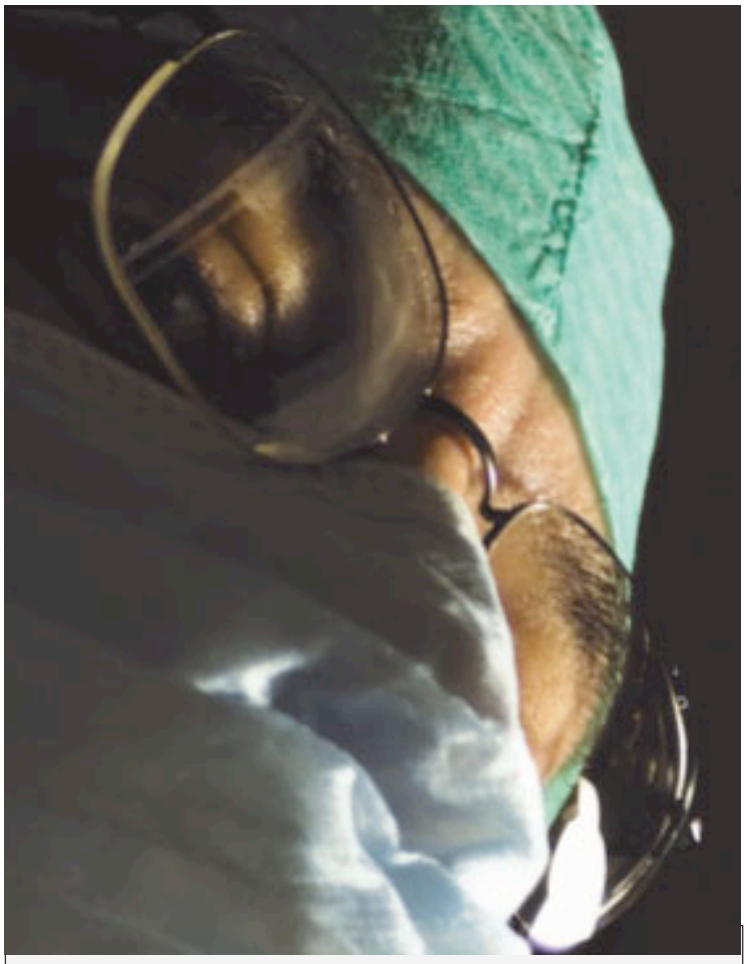

Figure 1. Patient 1, CTA with 3D reconstruction, anterior view of the bilateral patent ductus arteriosi (green). The right PDA (green) arises from the undersurface of the aortic arch and terminates into the right pulmonary artery (blue). The left PDA arises from the brachiocephalic artery and gives rise to the left pulmonary artery (blue).

one minute and 9 at five minutes. Once in the nursery, the patient started developing cyanosis and desaturations to the 70's, in spite of oxygen administration. A TTE was ordered at this time to assess cardiac status.

Initial echocardiogram findings showed Tetralogy of Fallot with pulmonary atresia. The report also noted the presence of confluent left and right branch pulmonary arteries fed by a ductus arteriosus, a right-sided arch, and a small Patent Foramen Ovale (PFO). At this point, the patient was started on prostaglandins and a CTA with 3D reconstruction was ordered to thoroughly map out the cardiac anatomy and assess the need for surgery.

The CTA with 3D reconstruction reported bilateral patent ductus arteriosi with the left-sided PDA arising from the left brachiocephalic trunk and the right-sided PDA arising from the inferior aspect of the transverse aortic arch (Figure 2). Cardiac comorbidities included in the report were Teratology of Fallot, a Ventricular Septal Defect (VAD), mild ventricular hypertrophy, and an ascending aorta overriding both the left and right ventricle.

After obtaining CTA results it was concluded that the infant would need refocalization. On

Figure 2. Patient 2, CTA with 3D reconstruction, posterior view of the bilateral patent ductus arteriosi (blue). The left PDA (blue) arises from the left brachiocephalic artery and ends in the left pulmonary artery (blue). The right PDA (blue) arises from the inferior aspect of the transverse aortic arch and terminates into the right pulmonary artery (blue).

Day 4 of Life the patient underwent a unifocalization of the collaterals and received a systemic-to-pulmonary artery shunt.

Case 3

This female patient was born to a 31-year-old G1P0, by vaginal delivery, at 39 weeks and 1 day gestation, weighting 3430 grams. The prenatal course was complicated by Class A1 gestational diabetes and fetal atrial flutter. The mother was treated with digoxin and underwent a prenatal ultrasound. The prenatal ultrasound was suggestive of cardiac disease characterized by tricuspid atresia, Total Anomalous Pulmonary Venous Return (TAPVR), and obstructed supradiaphragmatic, double Transposition of the Great Arteries. APGARS were 8 at one minute and 8 at five minutes. Immediately after birth, the patient received a prostaglandin infusion.

When the patient was a few hours old, a TTE was performed that demonstrated total anomalous pulmonary venous return with the superior vena cava and the inferior vena cava entering the right atrium, transposition of the great arteries, a primum ASD, VSD, and levocardia. The report also indicated that there was a right-PDA, and that the left pulmonary artery arose off the innominate artery via a collateral.

Functional analysis of the ventricles and 3-D reconstructions of the images obtained from a chest CTA at a later date suggested tortuous, bilateral patent ductus arteriosi with a multitude of coexistent congenital defects. The left PDA arose from the brachiocephalic artery and eventually gave rise to the left pulmonary artery, while the right PDA arose from the undersurface of the descending aortic arch before giving rise to the right pulmonary artery (Figure 3). The report also indicated transposition of the great arteries, an ASD, a VSD, a hypoplastic right ventricle, total anomalous pulmonary venous return, asplenia heterotaxy and a right coronary artery that arose from a non-coronary sinus.

The patient underwent cardiac catheterization with bilateral stenting of the proximal pulmonary arteries at 8 days old. The plan for complete correction of her congenital cardiac disease was a Glenn procedure at 4-6 months, followed by a Fontan-type extracardiac conduit type conversion at age 3.

Case 4

This male patient was born at 39 weeks gestation, weighing 2385 grams to a 27-year-old G1P0. The pregnancy was complicated by preeclampsia, which was treated with the induction of labor. Prenatal ultrasound noted possible Tetralogy of Fallot and a single umbilical artery. APGARS were 8 at one minute, and 9 at five minutes. Initially the patient appeared dusky, had a heart rate of 60 beats per minute and a pulse oximetry reading of 80%. The only intervention the infant received initially was 1 L of oxygen via nasal cannula.

The initial echocardiogram reported multiple aortopulmonary artery collaterals arising from the transverse and descending aorta, but no mention of a bilateral patent ductus arteriosi. The report also mentioned that the patient had pulmonary atresia, a VSD, an ASD, a dilated coronary sinus with persistent left superior vena cava, and a mild right ventricular hypertrophy.

The CTA with 3D reconstruction indicated bilateral patent ductus arteriosi with the right PDA arising from the base of the brachiocephalic artery and the left PDA arising from the undersurface of the aorta (Figure 4). Comorbid cardiac malformations included: Tetralogy of Fallot, a VSD, an overriding ascending aorta, pulmonary atresia, and a left-sided superior vena cava.

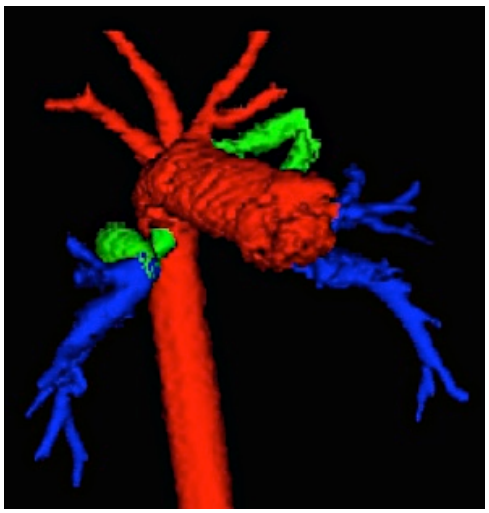

Figure 3. Patient 3, CTA with 3D reconstruction, anterior view of the bilateral patent ductus arteriosi (green). The right PDA (green) arises from the undersurface of the descending aortic arch and gives rise to the right pulmonary artery (blue). The left PDA (green) arises from the brachiocephalic artery and terminates into the left pulmonary artery (blue).

At this point the utilization of prostaglandins was discussed and the patient was closely monitored in order to maintain a pulse oximetry reading around 75% to 80%.

Discussion

Our retrospective chart review revealed four cases of bilateral patent ductus arteriosi that were all clearly diagnosed with CTA with 3D reconstruction. Cases in the literature were reviewed to investigate ulterior diagnostic approaches for this rare disease. Definitive diagnosis can be achieved with surgical visualization, pathology, monitoring for blood vessel closure postnatally, or radiologic confirmation of two separate blood vessels originating from an extracardiac artery and connecting directly to the central branch pulmonary arteries.[3] Alternately, major aortopulmonary collateral arteries connect indirectly to the pulmonary arteries.[3] Only a few case reports have been published within the last 15 years describing the diagnosis and management of bilateral patent ductus arteriosi.

Dipchand et al in 2002 presented a newborn in respiratory distress.[6] This patient's diagnosis of bilateral patent ductus arteriosi was initially discovered with echocardiogram and was later confirmed with CTA and surgical visualization.[6] Wong et al describes a case of bilateral PDAs with discontinuous branch pulmonary arteries in the setting of Heterotaxy Syndrome. In this case the echocardiogram was able to show the bilateral PDAs, which were later confirmed with MRI.[3] Sun et al in 2005 described an 18-day-old infant with cyanosis and congestive heart failure.[7] The echocardiogram outlined multiple cardiac malformations, but was unable to correctly identify the bilateral patent ductus arteriosi.[7] Subsequent testing with contrast

Figure 4. Patient 4, CTA with 3D reconstruction, posterior view of the bilateral patent ductus arteriosi (green). The left PDA (green) arises from undersurface of the aorta and gives rise to the left pulmonary artery (blue). The right PDA (green) arises from the base of the brachiocephalic artery and ends in the right pulmonary artery (blue).

enhanced magnetic resonance angiography (MRA) diagnosed bilateral patent ductus arteriosi.[7] Another case described by Ansnes et al in 2006, described an infant with bilateral patent ductus arteriosi that went unidentified on echocardiogram, but was visualized using a contrast enhanced helical computed tomography.[8] Lastly, Urgurlucan et al in 2011 described a nine-month-old male who presented with cyanosis. Echocardiogram report was inconclusive stating that either the patient had a right-sided patent ductus artery with a left-sided major aortopulmonary collateral artery or bilateral patent ductus arteriosi.[9] Definitive diagnosis was achieved through cardiac catheterization and direct surgical visualization.[9]

Many cases in the literature have shown that bilateral patent ductus arteriosi may be suspected on the initial echocardiogram, but usually requires further imaging to confirm the diagnosis. Furthermore, it appears that bilateral patent ductus arteriosi may be confused with aortopulmonary collateral arteries on TTE, as seen with our patient 4 and in the case report by Urgurlucan et al.[9] This may occur because a bilateral patent ductus arteriosi is defined as two separate blood vessels originating from an extracardiac artery and directly terminating into the central branch pulmonary arteries.[3] Alternately, in order to label a blood vessel a major aortopulmonary collateral artery, it must connect indirectly to the pulmonary arteries.[3] This is a small distinction that may not be observable with lower resolution of TTE.

While angiography, MRA and CT were used in the cases described above to diagnose the bilateral patent ductus arteriosi, there are no multi-patient studies indicating that these imaging modalities can consistently detect this type of congenital heart disease. Our case series suggests that CTA with 3D reconstruction can accurately and easily diagnosis this congenital malformation.

Advantages of CTA with 3D reconstruction include the high spatial resolution images, 3D reconstructed images, short imaging times that seldom require sedation, and direct visualization of the extracardiac structures like blood vessels and airway anatomy.[5, 2] The avoidance of sedation can be of crucial importance in this high-risk population. The arguments against CTA include exposure to ionizing radiation, use of intravenous contrast, and no circulatory flow information.[5] While no amount of radiation may be considered safe, with new techniques designed to minimize a patient's risk, the radiation exposure can be kept as low as possible.[2] For instance, in a prospective CTA study, patients are scanned intermittently for anywhere between three to four cardiac cycles. This is in contrast to retrospective CTA studies where patients are subjected to continuous radiation for multiple cardiac cycles. In adults with normal heart rates ranging from 70-100 beats per minute, prospective gating with padding will only capture a minimal percentage of the cardiac cycle, thus providing no functional information. In contrast, neonates have normal heart rates ranging from 120-160 beats per minute. Their increased heart rate makes it so we can image 50-100% of the cardiac cycle with every image captured, which when combined and analyzed, provides functional information on the entire cardiac cycle for use in 3D reconstruction with significantly reduced radiation exposure. The benefits may outweigh the arguments against CTA when you consider that the high-resolution 3D images are crucial in the identification of complex cardiac anatomy, provide functional information and can be used to plan the customized surgeries these patients require.

Within our case series there appeared to be no correlation between the comorbid cardiac malformations. Cardiac pathology ranged from Tetralogy of Fallot to total anomalous pulmonary venous return to ventricular septal defects. The only association was that every patient had multiple cardiac findings on CTA and TTE, which makes it difficult to recommend CTA for a particular population of patients that may be most at risk for bilateral ducti. The literature reports two cases of bilateral patent ductus arteriosi that were associated with microdeletions of chromosome 22q11 but within our study this association was not observed.[7, 8] The lack of repetition between presenting symptoms, cardiac comorbidities, and unpredictability of diagnosis puts even more emphasis on the use of imaging modalities such as CTA with 3D reconstruction to definitively diagnose this cardiac malformation.

Our case series is a compilation of the greatest number of cases of bilateral patent ductus arteriosi, and aimed at highlighting consistent imaging modality for this diagnosis. This case series emphasizes that the images obtained

Innovations in Pediatric Heart Failure Symposium

December 3-5, 2015, San Diego, CA

Loews Coronado Bay Hotel • www.SDPedsCardiology.com

Presented by

Rady Children's Hospital San Diego

UC San Diego School of Medicine

CHOC Children's Children's Hospital of Orange County

Education, Innovation and Collaboration

This state-of-the-art, interactive program is specifically designed for those involved in the care of patients with pediatric heart disease including pediatric cardiologists, surgeons, intensivists, nurses and other allied health professionals.

Conference highlights include:

- **Optional hands-on, interactive pre-conference academy on the intricacies of mechanical circulatory support (MCS) in children.**
- **Two Keynote Lectures:**
  - ***From Baby Fae to Today: Innovations in Infant Heart Transplant* by Dr. Leonard Bailey, Surgeon-in-Chief at Loma Linda University Children's Hospital.**
  - ***Regenerative Medicine: From Stem Cell To Clinical Biology in Pediatric Heart Failure* by Dr. Timothy Nelson, Mayo Clinic.**
- **General Sessions:**
  - **Heart Failure in Cardiomyopathy Patients**
  - **Managing Heart Failure in your Office**
  - **Challenging Mechanical Circulatory Support Scenarios**
  - **Controversies in Heart Failure**
  - **Fontan Failure to Success**
  - **The Next 25 Years: What Can We Expect?**
- **Plus…expert panels, interactive case discussions, breakout sessions, and thought-provoking debates!**

Early registration rates end October 27, 2015.
Discounted rates available for trainees, nurses, and other allied health professionals.

innovation
belongs in every moment

For more information contact: cme@rchsd.org 858-576-1700, ext. 4972.

with CTA with 3D reconstruction provide consistent and clear visuals of bilateral patent ductus arteriosi. The diagnostic reliability of other imaging modalities may be investigated in the future. However, at this point, the authors would recommend obtaining CTA in any stable infant with complex congenital heart disease to evaluate the possible presence of this rare finding, as well as to obtain a more complete representation of the cardiac anatomy and function.

Contributor Statement

Kimberly Lavin and Erin Birmingham have contributed equally to this paper.

Acknowledgements

The authors thank Dr. Stephen Pophal, MD, Dr. Andrew Keyser, MD, and the staff of Medical Records at St. Joseph's Hospital and Medical Center for their support and participation in the collection of data.

References

1. Cassels DE, Bharati S, Lev M (1975) The natural history of the ductus arteriosus in association with other congential heart defects. Perspect Biol Med 18(4): 541-572.
2. Richardson RR (2013) Atlas of Pediatric Cardiac CTA. Springer, New York pp 60-63.
3. Kwan-Wong C, Kramer L, Gupta-Malhotra M (2010) Echocardiographic diagnosis of bilateral ductus with discontinuous branch pulmonary arteries and heterotaxia syndrome. Pediatr Cardiol 31:917-918.
4. Dorfman A, Levine JC, Colan SD, Geva T (2005) Accuracy of echocardiography in low birthweight infants with congenital heart disease. Pediatrics 115: 102-107.
5. Siegel MJ (2008) Cardiac CTA: congenital heart disease. Pediatr Radiol 38(suppl 2): S200-S204.
6. Dipchand AI, Williams WG, Hornberger LK (2002) Double aortic arch with interruption proximal to the right carotid artery, bilateral patent ductus arteriosi, and complex congenital heart disease. Pediatr Cardiol 23: 246-247.
7. Sun AM, Alhabshan F, Branson H, Freedom R, Yoo SJ (2005) MRI diagnosis of isolated origin of the left subclavian artery from the left pulmonary artery. Pediatr Radiol 35: 1259-1262.
8. Asnes JD, Kirsch J, White RD, Duncan B (2006) Interrupted aortic arch with bilateral ductus arteriosi and bilateral aberrant subclavian arteries. Circulation 113(24): e863-e865.
9. Urgurlucan M, Sayin OA, Dayioglu E, Tireli E (2011) Bilateral PDA in patient with VSD and pulmonary atresia. J Card Surg 26(1): 107-110.

CCT

Biographical Sketch

Kimberly Lavin, MD is a recent graduate from Creighton University School of Medicine. She is currently an intern at MacNeal Hospital's transitional year program and she will begin her ophthalmology residency at Loyola University Medical Center in 2016.

Corresponding Author

Kimberly J. Lavin, MD
Creighton University School of Medicine, Phoenix Regional Campus, St. Joseph's Hospital and Medical Center, 350 West Thomas Road, Phoenix, AZ, 85013, USA
Tel. 602.406.9900; Fax. 602.406.9909
Kimberly.J.Lavin@gmail.com

Erin E. Birmingham, MD
Creighton University School of Medicine, Phoenix Regional Campus, St. Joseph's Hospital and Medical Center, 350 West Thomas Road, Phoenix, AZ, 85013, USA

Randy R. Richardson, MD
Creighton University School of Medicine, Phoenix Regional Campus, St. Joseph's Hospital and Medical Center, 350 West Thomas Road, Phoenix, AZ, 85013, USA

Development of A Pediatric Preventive Cardiology Clinic: Early Intervention for a Lifetime of Impact

Ann M. Dodge, MS, RN, CPNP; Erin L. Marriot, MS, RN, CPNP; Amy L.H. Peterson, MD

Purpose: To describe the indications for and implementation of a multi-disciplinary clinic for the management and treatment of childhood dyslipidemia.

Keywords: dyslipidemia, cholesterol, pediatric, lipids, screening, obesity, prevention, universal screening, guidelines.

Introduction

Atherosclerotic Heart Disease is a major cause of morbidity and is still the leading cause of death in the United States.[1] It is well known that atherosclerosis, the pathologic basis for clinical cardiovascular disease, originates in childhood. Childhood cardiovascular risk factors track into adulthood and have been shown in autopsy[2,3] studies to be strongly predictive of the extent of subclinical atherosclerosis in young adults.[4] Risk factors such as dyslipidemia, obesity, hypertension, insulin resistance, and tobacco use, if begun in childhood, accelerate the progression to clinical coronary artery disease in adulthood.

Treatment and modification of coronary artery disease risk factors are most effective if intervention takes place at a young age,[5,6] Both lifestyle modifications and FDA-approved medications exist for children in order to manage identified risk factors for coronary artery disease.

The prototypical inherited disease of cholesterol metabolism, Familial Hypercholesterolemia (FH), illustrates this concept. Due to an autosomal dominant mutation, children with FH have markedly elevated low-density lipoprotein cholesterol (LDL-C) levels present from birth which predispose them to early coronary artery disease. FH is a very common disease with an incidence of 1/200-250.[7] It is readily identifiable in children through measurement of serum LDL-C levels[8] and data indicate that early, aggressive treatment could restore normal life expectancy.[9]

Recognizing the need to identify and treat pediatric dyslipidemia in order to prevent premature death, in 2011 the National Heart, Lung, and Blood Institute (NHLBI) issued guidelines recommending universal lipid screening in all children ages 9-11 years, and again, at 17-21 years of age.[10] These guidelines were promptly endorsed by the American Academy of Pediatrics and were included in the updated version of Bright Futures published in February 2014. Universal screening of all children, rather than selective screening of children with existing risk factors, was recommended as studies show a selective screening approach has unacceptably low sensitivity in detecting pediatric dyslipidemia.[11]

A universal approach to pediatric lipid screening will greatly increase the number of children diagnosed with dyslipidemia Currently there is a paucity of clinics specializing in childhood dyslipidemia to meet this current and future demand, both in terms of trained providers and accessible locations.

Motivation to Implement Clinic

We felt it important to effectively diagnose and treat FH as well as other modifiable risk factors for coronary artery disease in our pediatric cardiology clinic. After recognizing the dearth of appropriate care providers and lack of awareness of pediatric dyslipidemia, we decided education and intervention for these pediatric patients was greatly needed. We felt it important to share this implementation process in order to assist and encourage other providers across different disciplines to implement specialized clinics for children with both acquired and genetic dyslipidemias.

Before 2011, our general pediatric cardiology clinic did not offer treatment and management specifically tailored to childhood dyslipidemia. A multilevel approach has been found to best meet the needs of our patients. Providers include a physician medical director and two pediatric nurse practitioners. One of our pediatric cardiology nurse practitioners had implemented a tobacco cessation program for pregnant women earlier in her career. In addition, she had studied motivational interviewing, which is a powerful tool in assisting patients to make long term healthier lifestyle choices.[12]

Our organization offers a subspecialty pediatric fitness clinic that serves overweight and obese children. We realized that their services would be synergistic for the obese patients in our pediatric dyslipidemia clinic and would allow us to offer more comprehensive interventions. Our hospital based clinic is also fortunate to have highly-skilled pediatric dietitians. As the Pediatric Preventive Cardiology Clinic (PPCC) expanded to regional clinics, we appreciated that many areas have similar services available that can be modified to meet pediatric needs. Dietitians who are interested in working with pediatric patients and families, and provider awareness of local resources to encourage physical activity are critical to the success of the program.

Establish Clinic Staff

The Pediatric Preventive Cardiology Clinic (PPCC) staff consists of a physician medical director, two pediatric nurse practitioners, pediatric dietitians, a registered nurse, a medical assistant and scheduling assistant. Our medical director is instrumental as a resource for patients, families and nurse practitioners in complex medication management. She also has been instrumental in reaching out to referring physicians. The skill set of nurse practitioners is ideal for a pediatric dyslipidemia clinic, as their training and experience emphasizes prevention, motivation, education and medication management. Nurse practitioners communicate well with other mid-level providers, and increase provider-awareness of screening and the importance of early treatment. In PPCC, they are able to function independently for patient clinic visits.

A designated dietician knowledgeable in treating children with lipid disorders is of utmost importance for consistent, family-centered dietary modifications. Many of our patients are able to avoid pharmacologic therapy due to successful lifestyle and dietary modifications. The registered nurse provides telephone consultation and triage of new patients. A well-trained medical assistant is important for accurate vital signs, BMI and waist circumference measurements. The medical assistant calls all patients the week before their visit to remind them to have fasting labs completed. They then enter all outside lab results in the electronic record so results are available to providers at time of visit. We found it very important to have designated scheduling staff to schedule all clinic appointments, as well as mail out pre-appointment food diaries and detailed family health history questionnaires that are brought to the initial clinic visit.

Staff Education

Early on we identified mentors to assist in education and guidance. Patrick McBride MD, MPH provided opportunity for all of our staff members to observe in the adult Preventive Cardiology Clinic. Dr. McBride is the Co-Director of the University of Wisconsin Hospital clinical preventive cardiology program. He continues to be a mentor and resource for our clinic. Guidelines and references we have found particularly useful are listed in Table 1. In addition, the National Lipid Association has regular mailings, journals, conferences, and CME offerings.

Innovations in Pediatric Heart Failure Symposium

Sponsored by

December 3-5, 2015, San Diego, CA

LOEWS CORONADO BAY RESORT

www.SDPedsCardiology.com

This state-of-the-art, interactive program is specifically designed for those involved in the care of patients with pediatric heart disease including pediatric cardiologists, surgeons, intensivists, nurses, trainees and other allied health professionals. Nationally recognized faculty members from over 20 institutions will cover challenging heart failure topics related to: cardiomyopathies, end stage congenital heart disease (including failing Fontans), heart transplantation, ventricular assist devices, interventional cardiology, cardiac ICU management, nursing care, genomics, cardiac imaging, pharmacotherapeutics, ethics and end of life care, electrophysiology and more!

Our focus will be on innovation, and as such, the conference format will be unique! There will be interactive sessions that are case-based and dependent on audience participation. Expert panels will be assembled to help answer the difficult management questions the clinician faces in their practice. Didactic sessions will be limited to short PowerPoint presentations. Workshops will be available to provide hands-on training for trainees, nurses and junior faculty members.

Confirmed guest faculty members include:

Juan Chuck Alejos, MD
Mattel Children's Hospital UCLA

Daniel Bernstein, MD
Lucile Packard Children's Hospital Stanford

Elizabeth Blume, MD
Boston Children's Hospital

Charles E. Canter, MD
St. Louis Children's Hospital

Brian Feingold, MD, MS
Children's Hospital of Pittsburgh of UPMC

Daphne T. Hsu, MD
The Children's Hospital at Montefiore

John Lynn Jefferies, MD, MPH, FAAP, FACC, FAHA
Cincinnati Children's Hospital Medical Center

Paul F. Kantor, MBBCh, FRCPC
Stollery Children's Hospital

Yuk M. Law, MD
Seattle Children's Hospital

Steven Lipshultz, MD, FAAP, FAHA
Children's Hospital of Michigan

Seema Mital, MD, FACC, FAHA, FRCP(C)
The Hospital for Sick Children Toronto

Shelley Miyamoto, MD
Colorado Children's Hospital

David L.S. Morales, MD
Cincinnati Children's Hospital Medical Center

Elfriede Pahl, MD, FACC, FAHA
Ann and Robert Lurie Children's Hospital

Jack F. Price, MD
Texas Children's Hospital

David Rosenthal, MD
Lucile Packard Children's Hospital Stanford

Joseph W. Rossano, MD, MS
The Children's Hospital of Philadelphia

Robert E. Shaddy, MD
The Children's Hospital of Philadelphia

Jeffrey A, Towbin, MD
Le Bonheur Children's Hospital

Steven A. Webber, MBChB, MRCP
Monroe Carell Jr. Children's Hospital at Vanderbilt

Steven Zangwill, MD
Phoenix Children's Hospital

Course Director:
Rakesh K. Singh, MD, MS
Rady Children's Hospital-San Diego

Need more information? cme@rchsd.org
858-576-1700, ext. 4972.

innovation
belongs in every moment

Board certification in clinical lipidology is available for both physicians and nurse practitioners. The American Board of Clinical Lipidology is an independent physician-certifying organization offering the highest benchmark of professional competency in Clinical Lipidology. Dr. Peterson holds this credential. The Clinical Lipid Specialist (CLS) Program is an advanced certification pathway open to licensed nurses, nurse practitioners, physician assistants, pharmacists, registered dietitians, clinical exercise physiologists/ specialists and other health professionals who meet qualifying criteria. The CLS program certifies allied health professionals and validates their professional credentials to provide specialized care to patients with dyslipidemia and related cardiometabolic conditions. The Nurse Practitioner providers have completed Lipid Academy, which is a two-day intensive course offered through the National Lipid Association (NLA). This course provides a comprehensive

Table 1
Useful Guidelines and Review Articles

1. McCrindle BW. Familial hypercholesterolemia in children and adolescents. Curr Opin Lipidol 2012;23:525-531.
2. Wiegman A, Gidding SS, Watts GF, et al. Familial hypercholesterolemia in children and adolescents: gaining decades of life by optimizing detection and treatment. Eur Heart J 2015, epub 5/25/15.
3. Goldberg AC, Hopkins PN, Toth PP, et al. Familial hypercholesterolemia: screening, diagnosis, and management of pediatric and adult patients. 2011;5:S1-S8.
4. Daniels SR, Benuck I, Christakis DA, et al. Expert panel on integrated guidelines for cardiovascular health and risk reduction in children and adolescents: summary report. Pediatrics 2011;128:S1-S44.

Figure 1. Community poster to raise awareness regarding pediatric universal lipid screening and our Pediatric Preventive Cardiology Clinic. Produced and created by American Family Children's Hospital, Madison, WI.

indoctrination to lipid science and essential information for the systematic management of dyslipidemia.

Marketing A New Clinical Service

It is vital to educate referring providers in regards to the need for universal screening and referral criteria in order to both ensure children receive recommended medical care and to attract the appropriate patient population. The NHLBI guidelines report normal ranges and treatment criteria for lipids based on age, other cardiac risk factors and co-morbidities. These ranges can become cumbersome and difficult to interpret when trying to make a quick referral decision in the context of a busy well-child visit.

To spread this message and encourage appropriate referrals, by developing a multi-media campaign. We worked closely with our public relations department to develop our website, (www.uwhealthkids.org/kidscholesterol). In addition, *Nursing Matters,* a statewide nursing publication that goes to every nurse and nurse practitioner in Wisconsin, ran an article about PPCC. Dr. Peterson continues to give presentations on pediatric dyslipidemia at various medical conferences that include a large number of pediatric providers, while the nurse practitioners provide outreach presentations to groups of nurses, physician assistants and nurse practitioners around the state. Posters are used at various local events and include a summary of our clinic with contact information (Figure 1). Our marketing department created flyers that are distributed to providers at conferences that summarize referral criteria and provide our contact information (Figure 2).

To date, we have we have received referrals from family practitioners, pediatricians, nurse practitioners, physician assistants, and other pediatric sub-specialty providers and have evaluated and treated over 400 patients since its inception in 2011.

Initial Clinic Visit Structure

To refer a patient to the PPCC, providers or nurses contact the clinic and provide a brief family health history, lipid results, and other pertinent patient information. An electronic referral system is also in place. Schedulers then mail the family a packet including: a family health history form, 3-day food diary, and introduction sheet to the clinic. One of the NPs then reviews each new patient being referred to determine if any additional laboratory studies are needed before the visit.

Our initial staff resources allowed for 12 one-hour visits per month, which has now expanded to 42 visits every month. In the past three years, two outreach PPCC clinic sites in Appleton, WI and Wausau, WI have been added. The child and family see both the nutritionist and NP or MD provider at the initial one hour clinic visit. Our clinic is currently experiencing a three-week wait for new appointments, with current plans being made for future expansion. The medical director is available during clinic hours to provide support as needed for NP visits or to staff visits which require more complex medication management.

When a patient arrives for their first appointment, the medical assistant obtains: vital signs, height, weight, waist circumference, and collects history form and food diary from the family. Each patient fills out a "lifestyle form" to document average weekly exercise time, screen time, preferred activities and eating habits.

Clinic patients are reviewed in advance to determine appropriate strategies for individualized treatment, as well as to try to establish an appropriate diagnosis based on the child's lipid profile and family history. During the first clinic visit, the provider assesses the child's overall risk, including family history, physical exam, comorbidities, obesity, hypertension, insulin resistance, and other conditions. If there are indications based on the history or physical examination, an ECG and/or an echocardiogram are ordered.

Education is a large component of this clinic. Providers and nutritionists educate the child and family about the results of the child's fasting lipid profile. Long-term

Pediatric Preventive Cardiology Clinic

Cholesterol Screening in Children

UW Health's American Family Children's Hospital is pleased to provide the following guidelines for cholesterol screening in children. If you have any questions about this information or would like to speak with a provider in the Pediatric Preventive Cardiology Clinic, please call us at (608) 263-3260.

WHEN/WHOM TO SCREEN
(FLP = fasting lipid panel)

Age	Test
Birth-2 yrs.	No screening recommended
2-8 yrs.	FLP if risk factors (below)
9-11 yrs.	**Everyone: Non-fasting lipid panel**
12-16 yrs.	FLP if risk factors (below)
17-21 yrs.	**Everyone: Non-fasting lipid panel**

NORMAL VALUES

Non-fasting: Non-HDL Chol < 145 or HDL > 40

Non-fasting lipid panel includes total cholesterol and HDL cholesterol

Non HDL cholesterol=TC (total cholesterol) minus HDL cholesterol

Fasting: Children and Adolescents

	Acceptable	Borderline
Total Cholesterol	< 170	170-199
LDL	< 110	110-129
HDL	> 45	40-45
Trig. 0-9 yrs.	< 75	75-99
Trig. 10-19 yrs.	< 90	90-129

RISK FACTORS

- Positive family history
- (MI, CABG, sudden cardiac death, < 55 yr. males, < 65 yr. females)
- Hypertension
- Obesity
- Tobacco use
- HDL < 40 mg/dL
- Type 1 & 2 diabetes
- Kidney disease
- Heart transplant
- Kawaski disease
- Chronic inflammatory disease
- HIV

RECOMMENDED REFERRAL GUIDELINES

The Pediatric Preventive Cardiology Clinic will see any patient with abnormal *fasting* lab results. If non-fasting lab results are abnormal, have the child do a fasting lipid panel.

Urgent Referral Recommended:
LDL > 190, TG > 500

APPOINTMENTS AND QUESTIONS

Providers:
Amy Peterson MD, Ann Dodge NP, Erin Marriott NP

Appointments: (608) 263-6420

To reach a provider: (608) 263-3260

UWHealth American Family Children's Hospital

School of Medicine and Public Health
UNIVERSITY OF WISCONSIN-MADISON

uwhealthkids.org/cholesterol

CH-37794-13

Figure 2. Pediatric Preventive Cardiology Clinic lipid screening information sheet for referring providers. Produced and created by American Family Children's Hospital, Madison, WI.

implications of an abnormal lipid profile are reviewed and tailored to the learning style and age of the child. We provide time for the patient and family to understand their individual and family risk factors, explore motivation and barriers to lifestyle changes, as well as establish patient-centered goals specific to exercise and nutrition. Motivational interviewing is used whenever possible to increase self-efficacy.

If the child has FH or another genetic dyslipidemia, we use this time to educate the family regarding the diagnosis of FH, and the likely need for future statin therapy due to this particular genetic diagnosis. Cascade screening is performed on potentially affected relatives. We have diagnosed parents, aunts, uncles, and siblings with FH and have referred them for appropriate treatment. An ongoing focus of our clinic is to improve lifestyle factors that may be influencing the lipid profile before implementing any form of pharmacotherapy. The dietician reviews the food diary and discusses strategies for optimizing their nutrition to improve the lipid profile.

Creating and collecting appropriate patient education materials is imperative prior to the implementation of the clinic. We have made child-friendly packets for each family that includes exercise and nutrition information. We have developed a file of multiple educational materials to address individual diagnoses, as well as handouts on fish oil, reading food labels, activity logs, and others. We have 3-dimensional artery models that mimic large arteries with various stages of plaque progression.

For documentation of clinic notes and patient education, electronic visit and patient instruction templates were created for both new and return visits. An electronic flowsheet and database were developed so that consistent information is captured at all visits in a format that allows for management of clinic operations, quality assurance, and will allow for future data analysis.

Follow-up Clinic Visit Structure:

Follow-up visits are joint 45 minute nutrition/provider visits. They follow a similar format to initial clinic visits. These visits include health history and family history updates, as well as completing the lifestyle form at each visit. Patients on medications are assessed for compliance and any potential side effects. Dose changes are made based on current lipid profile results. Patient-centered goals specific to exercise and nutrition are summarized by the patient at the end of each visit. A visit summary with lab results, lifestyle goals, and follow-up visit date with future labs are provided as a written summary after each visit. We have also recently implemented a pilot program to offer a telephone visit option for follow-up visits. These phone visits are intended for patients that do not require a nutritionist at every visit. This type of visit is appreciated by many families that live several hours away, or have school/work constraints. Families generally have a small co-pay for these visits and they are billable by our providers.

Conclusions

The process of establishing a pediatric dyslipidemia clinic, which is an under-recognized disease phenomenon in children, can be challenging but is also very rewarding. This is a very large patient population without enough providers and clinics to meet their present and future needs.

There continues to be controversy in regards to the 2011 universal pediatric screening guidelines as well as lack of data regarding long term statin use in children. We found that educating referring providers assists with further understanding and acceptance of the guidelines, and, as a result, we have seen a marked increase in referrals of children with pediatric dyslipidemia. We also are able to reassure referring providers that only a minority of our patient population requires medication therapy, as our focus is on lifestyle changes to promote improved long-term cardiovascular health.

We hope that sharing our experience of implementing a clinic specializing in the treatment of childhood dyslipidemias will encourage others to follow suit to address this very important, and under diagnosed pediatric patient population in order to reduce their risk factors for coronary artery disease.

References

1. Roger VL, Go AS, Lloyd-Jones DM, et al. Heart disease and stroke statistics – 2011 update. Circulation 2011;123:e18-e209.
2. Strong JP, Malcom GT, Oalmann MC, et al. The PDAY study: natural history, risk factors, and pathobiology. Pathobiological determinants of atherosclerosis in youth. Ann N Y Acad Sci 1997;811:226-35.
3. Berenson GS, Srinivasan SR, Bao W, et al. Association between multiple cardiovascular risk factors and atherosclerosis in children and young adults. N Engl J Med 1998;338:1650-6.
4. Noto N, Okada T, Abe Y, et al. Changes in the textural characteristics of intima-media complex in young patients with familial hypercholesterolemia: implication for visual inspection on B-mode ultrasound. J Am Soc Echocardiogr 2011;24:438-443.
5. Wiegman A, Hutten BA, de Groot E, ete al. Efficacy and safety of statin therapy in children with familial hypercholesterolemia: a randomized controlled trial. JAMA 2004;292:331-337.
6. Rodenburg J, Visseres MN, Wiegman A, et al. Statin treatment in children with familial hypercholesterolemia: the younger, the better. Circulation 2007;116:664-668.
7. Nordestgaard BG, Chapman MJ, Humphries SE, et al. Familial hypercholesterolemia is underdiagnosed and undertreated in the general population: guidance for clinicians to prevent coronary heart disease: Consensus Statement of the European Atherosclerosis Society. Eur Heart J 2013;34:3478-3490a.
8. Cuchel M, Bruckert E, Ginsberg HN, et al. European Atherosclerosis Society Consensus Panel on Familial Hypercholesterolemia: homozygous familial hypercholesterolemia: new insights and guidance for clinicians to improve detection and clinical management. Eur Heart J 2014;35:2146-2157.
9. Steinberg D. The rationale for initiating treatment of hypercholesterolemia in young adulthood. Curr Atheroscler Rep 2013;15:296.
10. Daniels SR, Benuck I, Christakis DA, et al. Expert panel on integrated guidelines for cardiovascular health and risk reduction in children and adolescents: summary report. Pediatrics 2011;128:S1-S44.
11. Ritchie SK, Murphy ECS, Ice C, et al. Universal versus targeted blood cholesterol screening among youth: the CARDIAC project. Pediatrics 2010;126:260-265.
12. Burke BL, Arkowitz H, and Mechola M. The efficacy of motivational interviewing: a meta-analysis of controlled clinical trials. J Consult Clin Psychol 2003;71:843-861.

CCT

Biographical Sketch

Ann Dodge, MS, RN, CPNP completed her Bachelor of Nursing degree at Duke University in Durham, North Carolina, and her Masters degree in the pediatric nurse practitioner program at University of Wisconsin-Madison. Her interests include working with the family inherited arrhythmia program and supporting the management of children with congenital heart disease. She is also passionate about providing education, support and treatment to children facing increased risks of heart disease as adults, including: obesity, dyslipidemia and tobacco use.

Ann M. Dodge MS, RN, CPNP,
American Family Children's Hospital
1675 Highland Ave.
AFCH Mail Code C200
Madison, WI 53792 USA
Ph: 608.263.6420; Fax: 608.890.8102
adodge@uwhealth.org

Erin L. Marriot MS, RN, CPNP
Department of Pediatrics
University of Wisconsin School of Medicine and Public Health
Madison, WI USA

Amy L.H. Peterson, MD
Department of Pediatrics
University of Wisconsin School of Medicine and Public Health
Madison, WI USA



TRANSFORMING INFORMATION INTO INNOVATION.

The Ward Family Heart Center at Children's Mercy Kansas City advances heart care through innovation. From fetal cardiology to the latest ventricular support devices and heart transplants, our team of dedicated experts is equipped to treat all pediatric heart conditions.

Here, evidence-based care is a reality. Our HeartCenter® database helps us transform information into action. Updated constantly, this real-time, clinical data center allows us to monitor and modify treatments for the best patient outcomes.

Our knowledge base will only continue to grow, thanks to the Cardiac High-Acuity Monitoring Program (CHAMP) App–designed by our cardiac information technology team. The app performs constant home monitoring of pediatric heart patients for immediate response and intervention. As more hospitals begin to use the app, our treasury of clinical data will support improved patient outcomes for our pediatric heart patients.

Advancing pediatric cardiology in real time. It's not just an outcome we pursue–it's a transformation we lead.

Ward Family Heart Center
CHILDREN'S MERCY KANSAS CITY

Find out more about our outcomes and research at **ChildrensMercy.org/heart**

Image of the Month from the Archiving Working Group

Contributors: Robert Anderson, MD; Vera D. Aiello, MD; Diane E. Spicer, BS, MD; Jeffrey P. Jacobs, MD; James St. Louis, MD; Jorge M. Giroud, MD; Charles W. Shepard, MD; Allen Everett, MD

IPCCC:

- Double outlet right ventricle: with doubly committed subarterial ventricular septal defect (01.01.23)

AEPC Derived Term

- Double outlet right ventricle: with doubly committed subarterial ventricular septal defect (01.01.23)

EACTS-STS Derived Term

- VA connection =Double outlet VA connections, Double outlet RV, with doubly committed subarterial VSD (01.01.23)

ICD10 Derived Term

- Double outlet right ventricle (Q20.1)

Commentary

In the images published as our twelfth column from the Archiving Working Group for "Congenital Cardiology Today," Professor Aiello has selected a heart obtained from a patient with double outlet right ventricle in which the interventricular communication is deemed to be doubly committed (Figure 1). Additionally, Dr. Shepard, using CT angiography and in a different patient, demonstrates very similar anatomy (Figure 2). These images generate several aspects worthy of further discussion.

In the first instance, in an earlier commentary, we pointed to the problems that exist in defining the margins of the "Ventricular Septal Defect" in the setting of Tetralogy of Fallot.[1] In that discussion, we emphasized that the curved area around which the surgeon would insert a patch so as to place the overriding aortic root in continuity with the cavity of the left ventricle in the setting of tetralogy was roofed by the muscular outlet septum, or on occasions, its fibrous remnant. We further emphasized that, if this precedent was followed in the setting of double outlet right ventricle, then the channel providing the exit from the left ventricle would better be described as the interventricular communication, rather than the "ventricular septal defect." This is due to the curved surface that is analogous to the area defined as the "ventricular septal defect" in Tetralogy of Fallot is represented, in hearts with double outlet right ventricle, by the locus around which the surgeon would place a patch as to tunnel one or other arterial root into continuity with the cavity of the left ventricle. As is the case in Tetralogy of Fallot, this curved area, when traced in the setting of double outlet right ventricle, would be roofed by the muscular outlet septum, or its fibrous remnant.[2] The outlet septum, be it muscular or fibrous, is of necessity exclusively a right ventricular structure when both arterial trunks arise from the right ventricle, as it is in Tetralogy of Fallot. At the current time, however, most investigators would name the area roofed by the inner heart curvature, rather than the one roofed by the outlet septum, as the "ventricular septal defect" in the various hearts grouped together because they share the ventriculo-arterial connection of double outlet right ventricle. Irrespective of such terminological niceties, it is the location of this channel which, since the investigation of Lev and his colleagues, has usually been employed to distinguish between the variants of this lesion.[3]

This brings into focus the second issue requiring further discussion on the basis of this month's image. Problems exist not only in agreeing how best to describe the channel between the ventricles, but also in determining its relationship to the arterial trunks. Our image of the month shows an autopsied specimen in which both arterial trunks arise

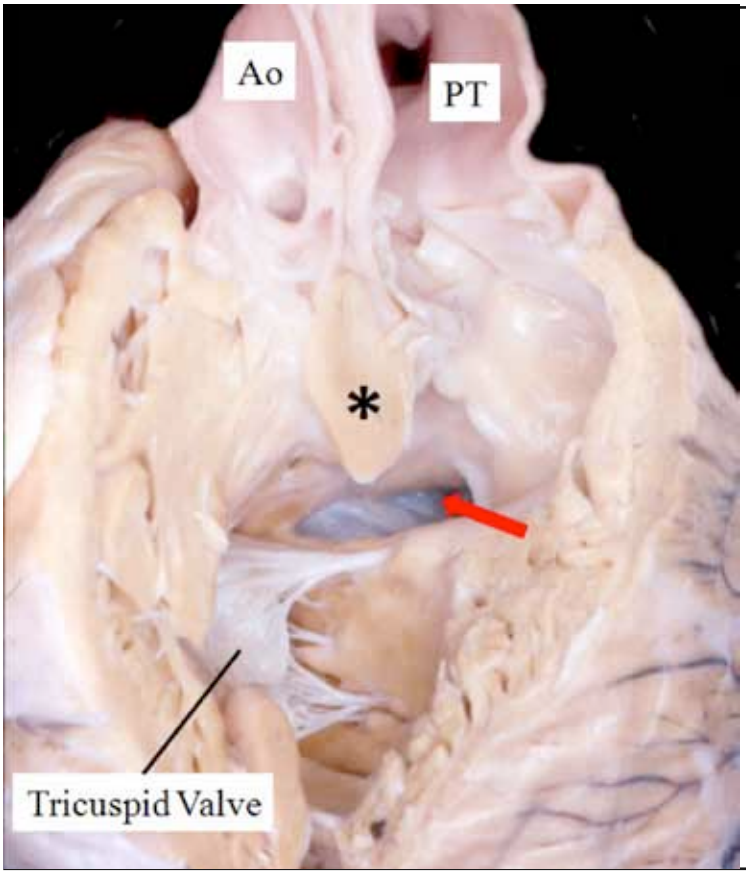

Double Outlet Right Ventricle - Figure 1

Modality: Anatomic specimen
Orientation: Anterior view of the right ventricle
Description: Anterior view of the opened right ventricle showing double outlet. The aorta (Ao) is slightly arterior to the pulmonary trunk (PT) and both arteries are supported by a complete muscular infundibulum. The interventricular communication (arrow) opens anteriorly to the septomarginal trabeculation, is not restrictive and is committable to both of the great arteries. The asterisk marks the extensive muscular outlet septum.

Contributor: Vera D Aiello, MD
Institution: Heart Institute (InCor), São Paulo University School of Medicine

AWG Web Portal Link for This Series of Images: http://ipccc-awg.net/DORV/DORV_VSD/DORV_VSD/DORV_VSD_01_01_23.html

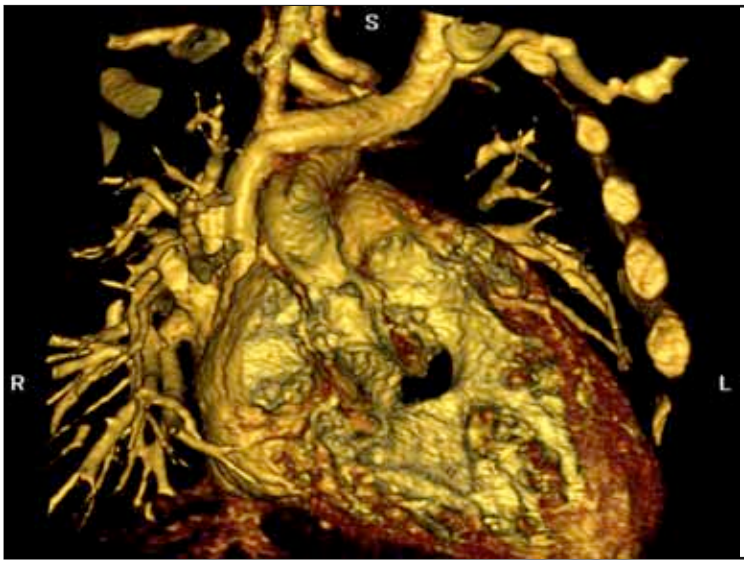

Double Outlet Right Ventricle - Figure 2

Modality: CT Angiogram
Orientation: Anterior view of the right ventricle
Description: Anterior view of the right ventricle demonstrating double outlet with the non-restrictive interventricular communication associated with both arterial trunks. The aorta is slightly anterior to the pulmonary trunk with a complete muscular infundibulum.
Contributor: Charles W Shepard, MD
Institution: University of Minnesota Children's Hospital

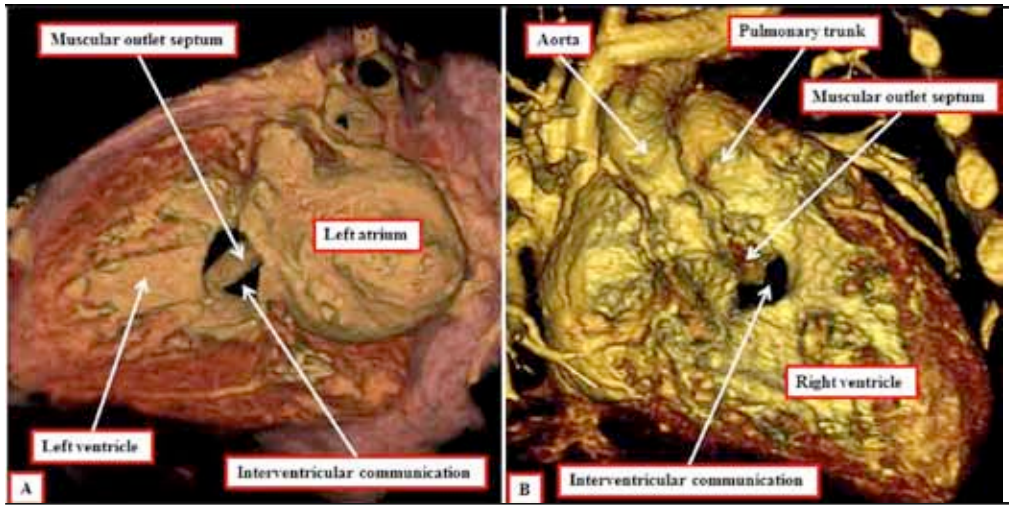

Double Outlet Right Ventricle - Figure 3

The images, obtained using computed tomographic angiography from the same patient from Figure 2, with double outlet right ventricle, show the interventricular communication as viewed (A) from the left ventricle and (B) from the right ventricle. Is the defect truly doubly committed, as potentially suggested by panel A?

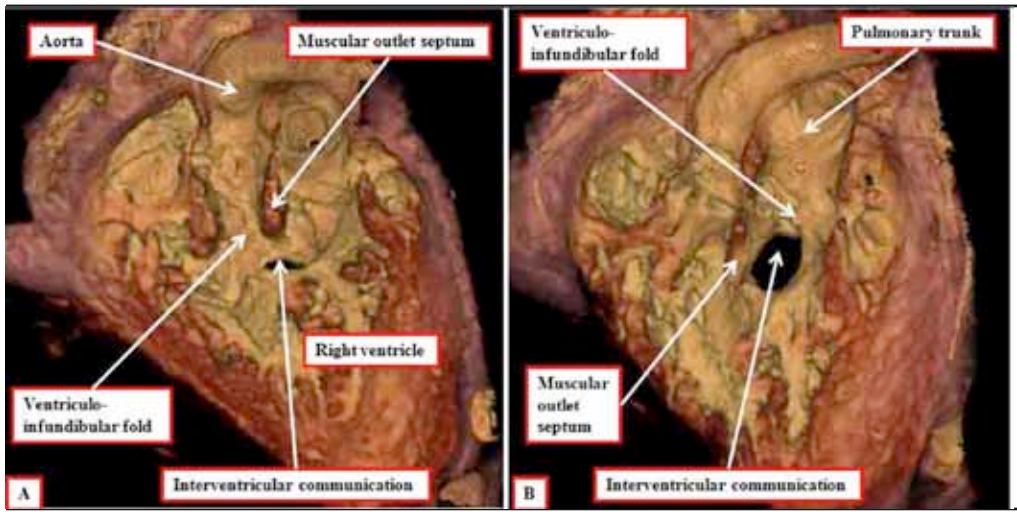

Double Outlet Right Ventricle - Figure 4

Appropriate imaging of the potential pathways from the interventricular communication to the arterial roots in the heart from the same patient reveals that there is a considerable distance between the defect and the anterior aortic root (panel A), whereas it would be an easy matter to create a tunnel to the pulmonary root (panel B).

exclusively above the right ventricle, and with extensive infundibulums supporting the leaflets of both arterial valves. The channel between the ventricles is roofed cranially by these infundibulums, and opens to the right ventricle between the limbs of the septomarginal trabeculation, or the septal band. There is myocardial tissue posteriorly-inferiorly interposing between the leaflets of the tricuspid and mitral valves, so the channel, as viewed from the right ventricle, has exclusively muscular borders. The dilemma is whether the exit from the left ventricle is best described as being subaortic, subpulmonary, doubly-committed, or non-committed? In our image, the heart has been classified as having a doubly-committed defect. Almost always, however, the examples of double outlet right ventricle with doubly-committed defects have fibrous rather than muscular outlet septums. It is then the lack of an extensive infundibular septum which makes it feasible for the surgeon to tunnel the exit from the left ventricle to either arterial root. A case can also be made, nonetheless, for considering the defect to be non-committed, or even subpulmonary or subaortic.

The case in favour of considering the illustrated defect as being non-committed rests on the length of the infundibulums, which lift the leaflets of both the aortic and pulmonary valves away from the base of the heart. Recent surgical experience, nonetheless, has shown that the length of the infundibulum is not a major impediment in creating a tunnel from interventricular communications opening between the limbs of the septal

band to one or other of the arterial roots, even when the defect has been diagnosed prior to surgery to be "non-committed".[4,5] In fact, the anatomic feature that potentially commits the interventricular communication to one or other arterial root is its position between the limbs of the septomarginal trabeculation, or septal band.

Would it be more sensible, therefore, always to seek to determine to which arterial root it is easier to commit the defect during surgical repair? The availability of diagnostic techniques showing three-dimensional relationships during life now shows that these decisions are potentially better made with greater precision during life than in the autopsy room. Recent experience shows the amazing facility of computed tomographic angiography in this respect. In Figure 3 we show the view of the interventricular communication in the same patient from Figure 2, with double outlet right ventricle and a potentially doubly-committed defect. The location of the muscular outlet septum as seen from the left ventricle (Figure 3A) suggests that the defect could be tunnelled to either of the arterial outlets. This is also suggested by the view from the right ventricle (Figure 3B), which shows the similarity between the anatomical image from the autopsied heart (Figure 1) and the clinical images derived from computed tomographic examinations. Further imaging of the patient, however, shows that the anterior position of the aorta, supported by an extensive infundibulum, or conus (Figure 4A), means that there is a significant distance to be bridged so as to bring the interventricular communication into continuity with the aortic root. This is not the case, in contrast, when the patient is imaged so as to show the relationship between the defect and the pulmonary root (Figure 4B). The subpulmonary infundibulum separates the leaflets of the pulmonary and mitral valves, but is shorter than the subaortic infundibulum, and much closer to the interventricular communication. Although there is some justification for considering the defect as being doubly committed, therefore, our preference would be to describe it as being subpulmonary, and considering the patient to have a Taussig-Bing heart.[6] Connecting the defect to the pulmonary root, of course, means that the surgeon would also be required to perform an arterial switch procedure. If the defect were truly doubly-committed, it could be connected directly to the aortic root, obviating the need for the arterial switch. The images suggest, nonetheless, that significant skill would be required, courting the risk of obstruction, if an attempt was made to tunnel the defect to the aorta.

Our images, and commentary, therefore, show the advantages to be gained by describing the channel between the ventricles as the interventricular communication, rather than the "ventricular septal defect." We suggest that the "septal defect" is analogous to the curved area over which the surgeon will place a patch so as to tunnel the defect to one or other outflow tract. To be, potentially, surgically committed, such defects will always open to the right ventricle between the limbs of the septomarginal trabeculation, or septal band. Non-committed defects will be those opening through the inlet or apical parts of the muscular interventricular septum. Whether a committed defect is then deemed to be subaortic, subpulmonary, or doubly-committed will depend on the ease with which the patch can be created so as to restore a direct route from the left ventricle to one or other, or potentially both, of the outflow tracts.

Please visit us at the AWG Web Portal at http://ipccc-awg.net/, and help in the efforts of the Archiving Working Group and the International Society for Nomenclature of Paediatric and Congenital Heart Disease.

The authors would like to acknowledge the Children's Heart Foundation (www.childrensheartfoundation.org/) for financial support of the AWG Web Portal.

References

1. Anderson RH, Aiello VD, Spicer DE, Jacobs JP, Giroud JM. Fallot's tetralogy: Anatomical observations and controversies. Cong Cardiol Today 2013; 11: 10-13.
2. Bailliard F, Spicer DE, Mohun TJ, Henry GW, Anderson RH. The problems that exist when considering the anatomic variability between the channels that permit interventricular shunting. Cardiol Young 2015; 25, 15–28.
3. Lev M, Bharati S, Meng CC, Liberthson RR, Paul MH, Idriss F: A concept of double-outlet right ventricle. J Thorac Cardiovasc Surg 1972; 64: 271-281.
4. Lacour-Gayet F, Haun C, Ntalakoura K, Belli E, Houyel L, Marcsek P, Wagner F, Weil J. Biventricular repair of double outlet right ventricle with non-committed ventricular septal defect (VSD) by VSD rerouting to the pulmonary artery and arterial switch. Eur J Cardiothorac Surg. 2002; 21:,1042-8.
5. Devaney EJ, Lee T, Gelehrter S, Hirsch JC, Ohye RG, Anderson RH, Bove EL. Biventricular repair of atrioventricular septal defect with common atrioventricular valve and double-outlet right ventricle. Ann Thorac Surg 2010; 89: 537-542.
6. Stellin G, Zuberbuhler JR, Anderson RH, Siewers RD. The surgical anatomy of the Taussig Bing malformation. J Thorac Cardiovasc Surg 1987; 93; 560 569.

CCT

Corresponding Author

Vera D. Aiello, MD
Co-Chairman, Archiving Working Group
Heart Institute (InCor), São Paulo University School of Medicine, São Paulo, Brazil
anpvera@incor.usp.br

Robert Anderson, MD
Co-Chairman, Archiving Working Group
Institute of Genetic Medicine, Newcastle University, Newcastle upon Tyne, UK

Diane E. Spicer, BS
Senior Archivist, Archiving Working Group
University of Florida, Department of Pediatrics-Cardiology, Gainesville, Florida and the Congenital Heart Institute of Florida, St. Petersburg & Tampa, FL USA

Jeffrey P. Jacobs, MD
Archiving Working Group
Professor of Surgery, Cardiovascular and Thoracic Surgeon, Johns Hopkins Children's Heart Surgery, All Children's Hospital and Florida Hospital for Children
Saint Petersburg, FL USA

James D. St. Louis, MD
Archiving Working Group
Professor and Surgical Director, Cardiac Transplantation
University of Missouri-KC School of Medicine
Children's Mercy Hospital
Kansas City, MO USA

Charles W. Shepard, MD
Archiving Working Group
University of Minnesota Amplatz Children's Hospital, Department of Pediatrics, Minneapolis, MN USA

Jorge M. Giroud, MD
Co-Chairman, Archiving Working Group
Congenital Heart Institute of Florida & Pediatrix Medical Group
St. Petersburg & Tampa, FL USA

Allen D. Everett, MD
Archiving Working Group
Johns Hopkins University
Helen B. Taussig Heart Center
Charlette R. Bloomberg Children's Center
Baltimore, MD USA

And the members of the Archiving Working Group of the International Society for Nomenclature of Paediatric and Congenital Heart Disease

Preview of the Innovations in Pediatric Heart Failure Symposium To Be Held December 3rd-5th, 2015 at the Loews Coronado Bay Hotel – San Diego, CA USA

By Rakesh K. Singh, MD, MS

Education, Innovation, and Collaboration - these are the guiding principles of the three-day meeting entitled *Innovations in Pediatric Heart Failure Symposium* being held in San Diego this December. This state-of-the-art, interactive program is specifically designed for those involved in the care of patients with pediatric heart disease including: pediatric cardiologists, surgeons, intensivists, nurses and other allied health professionals. This meeting is jointly presented by the Heart Institutes at Rady Children's Hospital/UC San Diego School of Medicine and the Children's Hospital of Orange County (CHOC). Over 50 internationally recognized faculty members from over 20 institutions will cover challenging heart failure topics related to cardiomyopathies, end-stage Congenital Heart Disease (including the failing Fontan), heart transplantation, ventricular assist devices, interventional cardiology, cardiac ICU management, nursing care, genomics, cardiac imaging, pharmacotherapeutics, electrophysiology and more.

The focus of the symposium will be on innovation, and as such, the conference format will be unique! There will be interactive sessions that are case-based and dependent on audience participation. Expert panels will be assembled to help answer the difficult management questions clinicians' face in their practice every day. At least half of every session will be specifically designed to maximize interaction between the speakers and audience. An audience response system will be used to facilitate this interaction. Social media platforms will also be used to allow for real-time conversations with the speakers. Debates will be held on the most controversial topics in the field of pediatric heart failure. Didactic sessions will be limited to short PowerPoint presentations. CME/CEU credits will be provided and discounted registration rates are available for trainees, nurses and allied health professionals.

The meeting begins with a fantastic optional pre-conference academy, followed by 10 sessions over three days. There will be two unique breakout sessions for physicians and nurses. The optional pre-conference academy entitled, "ABC's of MCS," will be held Thursday morning December 3rd, Dr. Scott Auerbach, Colorado Children's Hospital, and Dr. David Morales, Cincinnati Children's Hospital, will lead the hands-on, interactive pre-conference academy on the intricacies of mechanical circulatory support (MCS) in children. The first part of the academy is entitled, "ABC's of MCS: Expanding Your Knowledge," and will focus on reviewing the different types of MCS that are available for children, when you use them, and the importance of patient selection. This 2-hour didactic session will include a lecture by Dr. Denise Suttner, Rady Children's Hospital San Diego, on the use of ECMO in children with heart failure. After a short break, the academy will conclude with "ABC's of MCS: Using your Hands," and will allow for attendees to work directly with the expert faculty at various hands-on stations. Different types of MCS will be available, from ECMO to the newer generation continuous flow devices. The faculty will work one-on-one with attendees on learning the unique aspects of each device.

The main symposium starts Thursday afternoon, December 3rd, and runs through Saturday afternoon December 5th. The meeting begins with a keynote lecture entitled "From Baby Fae to Today: Innovations in Infant Heart Transplant" by Dr. Leonard Bailey, Surgeon-in-Chief at Loma Linda University Children's Hospital. Dr. Bailey is a world-renown pediatric cardiothoracic surgeon most

known for his pioneering work in xenotransplantation. He will provide his unique perspective on advances in infant heart transplantation over the last 30 years. There may even be a special introduction of Dr. Bailey by a surprise guest!

The first general session, entitled "Heart Failure in Cardiomyopathy Patients," will be moderated by Dr. Jeffrey Towbin, Le Bonheur Children's Hospital, and Dr. David Rosenthal, Lucile Packard Children's Hospital Stanford. Dr. Steven Lipshultz, Children's Hospital of Michigan, will discuss what's new in the prevention and treatment of chemotherapy-induced heart failure. Dr. John Lynn Jefferies, Cincinnati Children's Hospital, will then share some exciting new research studies looking at improving

outcomes in neuromuscular patients at risk for heart failure. As technology advances, so does our ability to image our cardiomyopathy patients. Dr. Beth Printz, Rady Children's Hospital San Diego, will share these new modalities. Two more rare forms of cardiomyopathy are arrhythmogenic right ventricular cardiomyopathy (ARVC) and restrictive cardiomyopathy. Dr. Brian Feingold, Children's Hospital of Pittsburgh, will provide updates on these two unique diagnoses. The plenary ends with challenging case presentations to the speakers with audience participation.

Dr. Charles Canter, St. Louis Children's Hospital, and Dr. Yuk Law, Seattle Children's Hospital, will moderate the second general session entitled, "Managing Heart Failure in your Office." With such few randomized clinical trials in pediatric heart failure, how should these patients be managed? Dr. Paul Kantor, Stollery Children's Hospital, will attempt to guide the audience to an answer. The role of exercise stress testing in these patients will be reviewed by Dr. Christopher Davis, Rady Children's Hospital San Diego. Dr. Jeffrey Towbin will tackle the controversies surrounding the use of biomarkers and genetic testing in children with heart failure. With more children with Congenital Heart Disease (CHD) surviving to adulthood, Dr. James Perry will give a timely talk on the unique aspects of heart failure in these adult CHD patients. The session closes with a debate you don't want to miss. Dr. Daphne Hsu, Children's Hospital at Montefiore, and Dr. Robert Shaddy, Children's Hospital of Philadelphia, will go head-to-head to debate the following statement: "Heart Failure Treatments in Children Should be Based on Large, Randomized Adult Studies." A welcome reception will follow this lively debate on the outdoor terrace facing the beautiful San Diego Bay and skyline.

The second day of the symposium, Friday December 4th, begins with another keynote lecture entitled, "Regenerative Medicine: From Stem Cell To Clinical Biology in Pediatric Heart Failure" by Dr. Timothy Nelson, Mayo Clinic. Dr. Nelson will share his exciting stem cell research on heart failure in children including new clinical trial data in patients with Hypoplastic Left Heart Syndrome and systemic ventricular dysfunction.

The third general session, entitled "Challenging Mechanical Circulatory Support Scenarios", will be moderated by Dr. Elizabeth "Betsy" Blume, Boston Children's Hospital, and Dr. Rakesh Singh, Rady Children's Hospital San Diego. Dr. Eric Devaney, Rady Children's Hospital San Diego, will provide a surgeon's perspective on which devices are best for our patients. Dr. David Rosenthal will help clarify whether candidate or device selection affects outcomes the most, while Dr. David Morales will highlight the unique ways MCS has been used in pediatric heart failure patients. Dr. Scott Auerbach will navigate the pitfalls of device complications and give valuable advice on how to avoid them. The plenary session ends with challenging case presentations to the speakers with audience participation. Attendees are encouraged to bring their toughest MCS cases to the conference!

The next 2 concurrent sessions are breakout sessions for physicians and nurses. The physician breakout session will focus on "Heart Failure in the ICU," moderated by Dr. Kevin Maher, Children's Healthcare of Atlanta, and Dr. Anthony Chang, Children's Hospital of Orange County. During this session, speakers will focus on acute decompensated heart failure, right heart failure, fulminant myocarditis, and acute kidney injury. The nursing breakout session will discuss "Heart Failure for the Beginner to the Advanced Practitioner," moderated by Esther Liu, Lucile Packard Children's Hospital Stanford, and Susan Park, Phoenix Children's Hospital. Nursing experts from around the country will review heart failure and cardiomyopathies, inflammatory heart disease, congenital heart disease, and medical therapy.

After lunch on Friday, there will be 2 more concurrent breakout sessions. The physician breakout session is entitled, "From Bench to Bedside: Translational Heart Failure Research," and will be moderated by Drs. Daphne Hsu and Steven Lipshultz. World-renowned pediatric heart failure faculty members will share their cutting-edge research on: adrenergic signaling, circulating microRNA biomarkers, personalized medicine, cardiac mechanics modeling, transplant immunology, and more! The nursing breakout session will focus on "Building a Successful Heart Failure Program: From Hospital to Home," moderated by Kathryn Dodds, Children's Hospital of Philadelphia, and Teresa Gonzalez, Rady Children's Hospital San Diego. Heart failure nurses and nurse practitioners will share their experiences regarding outpatient VAD and inotropic therapy, medications, nutrition, and psychosocial barriers.

Dr. Daniel Bernstein, Lucile Packard Children's Hospital Stanford, and Dr. Robert Shaddy will moderate the fourth general session entitled "Controversies in Heart Failure." Dr. Betsy Blume will share state of the art advancements in palliative care for our pediatric patients with end-stage heart failure. We are honored to have Shelley Bowen, Director of Family Services and Awareness at the Barth Syndrome Foundation, join us to share her personal and professional experiences with heart failure and transplantation in children. Dr. Anthony McCanta, Children's Hospital of Orange County, will help separate fact from fiction when he discusses the role of cardiac resynchronization therapy in children with heart failure. Dr. Elfriede Paul, Ann and Robert Lurie Children's Hospital, will educate us on the ongoing efforts to improve the way pediatric providers transition heart failure patients to our adult colleagues. The second day of our symposium ends with a debate entitled, "Non-compliant Adolescent Patients with End Stage Heart Failure Should Not Be Offered Transplantation or VAD Therapies," and it will be a tag team event! Each side will include 1 physician and 1 nurse practitioner; Dr. Joseph Rossano, Children's Hospital of Philadelphia, and Esther Liu on one side, with Dr. Yuk Law and Susan Park on the other side. The debate will end with a final vote from the audience, so stay tuned!

The symposium resumes on Saturday morning, December 5th, with the fifth general session entitled, "Fontan Failure to Success," moderated by Drs. Elfriede Pahl and Gabrielle Vaughn, Rady Children's Hospital San Diego. Dr. Charles Canter will update the audience on medical treatment options for the failing Fontan patient, while Drs. John Moore and John Lamberti, Rady Children's Hospital San Diego, will discuss interventional and surgical modalities. Dr. Albert Hsiao, University of California San Diego, and Dr. Sanjeet Hegde, Rady Children's Hospital San

"Education, Innovation, and Collaboration - these are the guiding principles of the three-day meeting entitled Innovations in Pediatric Heart Failure Symposium being held in San Diego this December. This state-of-the-art, interactive program is specifically designed for those involved in the care of patients with pediatric heart disease including: pediatric cardiologists, surgeons, intensivists, nurses and other allied health professionals. This meeting is jointly presented by the Heart Institutes at Rady Children's Hospital/UC San Diego School of Medicine and the Children's Hospital of Orange County (CHOC)."

Diego, will demonstrate the "state-of-the-art" technology currently being used to model congenital heart disease, from 3D printing to 4D flow MRI imaging. The session ends with challenging case presentations to the speakers with audience participation, so bring your toughest failing Fontan cases to the conference!

The sixth and final general session is entitled, "The Next 25 Years: What Can We Expect?" and is moderated by Dr. Seema Mital, Hospital for Sick Children and Dr. Steven Webber, Monroe Carell Jr. Children's Hospital at Vanderbilt. This unique session is meant to tantalize the audience with speakers describing their "out of the box" innovative research. Dr. Kevin Maher will discuss nanomedicine and MCS, while Dr. Anthony Chang reviews big data and artificial intelligence. Dr. Daphne Hsu will share her experiences with pharmaceutical drug development for children with heart failure. Dr. Spyro Mousses, Children's Hospital of Orange County, will introduce the emerging role of cardiac pharmacogenomics. The symposium ends with Dr. David Morales and Dr. Steven Zangwill, Phoenix Children's Hospital debating "As Technology Improves, Children with End-Stage Heart Failure Should be Offered VADs as Destination Therapy."

This symposium is being held at the beautiful Loews Coronado Bay Hotel. Perched on its own 15-acre peninsula, the hotel has stunning views of the shimmering bay water and San Diego skyline. The hotel is located on Coronado Island, home to some of the best beaches and restaurants in town. Downtown San Diego is a short car or ferry ride away. We look forward to seeing you in sunny San Diego this December for the *Innovations in Pediatric Heart Failure Symposium*!

For more information, go to: www.SDPedsCardiology.com.

CCT

Rakesh K. Singh, MD, MS
Medical Director of the Heart Failure, Mechanical Circulatory Support & Transplantation Program
Rady Children's Hospital San Diego
Assistant Clinical Professor of Pediatrics
University of California San Diego
3020 Children's Way, MC 5004
San Diego, CA 92123 USA
Tel: 858.966-5855; Fax: 858.966.7903

rsingh@rchsd.org

CONGENITAL CARDIOLOGY TODAY

© 2015 by Congenital Cardiology Today (ISSN 1554-7787-print; ISSN 1554-0499-online). *Published monthly. All rights reserved.*
www.CongenitalCardiologyToday.com

8100 Leaward Way, PO Box 444, Manzanita, OR 97130 USA
Tel: +1.301.279.2005; Fax: +1.240.465.0692

Publishing Management:
- Tony Carlson, Founder, President & Sr. Editor - *TCarlsonmd@gmail.com*
- Richard Koulbanis, Group Publisher & Editor-in-Chief - *RichardK@CCT.bz*
- John W. Moore, MD, MPH, Group Medical Editor - *JMoore@RCHSD.org*
- Virginia Dematatis, Assistant Editor
- Loraine Watts, Assistant Editor
- Caryl Cornell, Assistant Editor
- Chris Carlson, Web Manager
- Rob Hudgins, Designer/Special Projects

Free Subscription to Qualified Professionals: Send your name, title(s), hospital or practice name, work address and url, phone, fax and email to: sub@cct.bz.

Save the Date

Evolution or Revolution?

Disruptive Thinking, Technology and Innovation In the Treatment of Pediatric Cardiac Disease

Biltmore Hotel, Coral Gables, FL

LIVE MEETING
December 3-6, 2015

Virtual Meeting using iLearn®
with Global Transmission Featuring
Simultaneous Spanish Translation

Faculty:

Redmond Burke, MD
Robert Campbell, MD
Aldo R. Castañeda, MD, PhD
Paul Checchia, MD
Mitchell Cohen, MD
John Costello, MD, MPH
Martin Elliott, MD
Jon Epstein, MD
J. William Gaynor, MD
Rani Gereige, MD
Jeff Jacobs, MD
Tom Karl, MD
John Kheir, MD
Terry King, MD
Narendra Kini, MD
Lisa Kohr, MSN, CPNP
Carole Lannon, MD, MPH
Stacey Lihn
Leo Lopez, MD
Brad Marino, MD, MSCE
Juan-Carlos Muñiz, MD
Richard Ohye, MD
Sara Pasquali, MD
Dan Penny, MD, PhD
Andrew Redington, MD
John Rhodes, MD
Anthony Rossi, MD
Jack Rychik, MD
Steve Schwartz, MD
Girish Shirali, MD
Edward Walsh, MD
Gil Wernovsky, MD

SPONSORED BY:

Nicklaus Children's Hospital
MIAMI CHILDREN'S HEALTH SYSTEM
Heart Program

For more information or to register, please visit: **nicklauschildrens.org/heartinnovation**

Accreditation Statement: *The Miami Children's Health System is accredited by the Accreditation Council for Continuing Medical Education to provide continuing medical education for physicians.* ***Designation Statement:*** *The Miami Children's Health System designates this live activity for a maximum of 17 AMA PRA Category 1 Credit(s)™. Physicians should only claim credit commensurate with the extent of their participation in the activity.* ***Faculty/Planner Disclosure Policy:*** *In accordance with the Accreditation Council for Continuing Medical Education's Standards for Commercial Support, all planners, teachers and authors involved in the development of CME content are required to disclose to the accredited provider their relevant financial relationships. Relevant financial relationships will be disclosed to the activity audience.*

NIT-OCCLUD®

COIL SYSTEM FOR PDA CLOSURE

A SAFER, EASIER WAY TO CLOSE

The Nit-Occlud® coil system for PDA closure is designed to match individual morphologies and sizes

The delivery system facilitates optimal device positioning

The Nit-Occlud® PDA coil is repositionable and retrievable prior to release

Tight and compact windings ensure efficient occlusion

The Nit-Occlud® PDA coil was determined to be MRI conditional

Radiopaque

For more information or to place an order, contact your B. Braun Interventional Systems Inc. representative or call 1-877-VENA-CAV (836-2228)

pfmmedical

Manufacturer:
pfm medical, ag
Wankelstraße 60
50996 Köln, Germany
T +49 (0)2236 9641-10
F +49 (0)2236 9641-20

B|BRAUN Interventional Systems

Distributed by:
B. Braun Interventional Systems Inc.
824 Twelfth Avenue
Bethlehem, PA 18018 USA
Tel: 1-877-VENA CAV (836-2228) (USA)
Fax: 1-610-849-1334
www.bisusa.org

Indication: The Nit-Occlud® PDA coil is a permanently implanted prosthesis indicated for percutaneous, transcatheter closure of small to moderate size patent ductus arteriosus with a minimum angiographic diameter less than 4mm. Nit-Occlud Brief Statement: Do not implant the Nit-Occlud PDA into patients who have endocarditis, endarteritis, active infection, pulmonary hypertension (calculated PVR greater than 5 Wood Units), thrombus in a blood vessel through which access to the PDA must be obtained, thrombus in the vicinity of the implantation site at the time of the implanttion or patients with a body weight < 11 lbs (5 kg). An angiogram must be performed prior to implantation for measuring length and diameter of the PDA. Only the pfm medical implantation delivery catheter should be used to implant the device. Administration of 50 units of heparin per kg body weight should be injected after femoral sheaths are placed. Antibiotics should be given before (1 dose) and after implantation (2 doses) in order to prevent infection during the implant procedure. Do not implant the Nit-Occlud PDA in an MR environment. Do not pull the Nit-Occlud coil through heart valves or ventricular chambers. Contrast media should not be injected through the implantation catheter. The catheter must not be connected to high pressure injectors. Patients may have an allergic response to this device due to small amounts of nickel that has been shown to be released from the device in very small amounts. If the patient experiences allergic symptoms, such as difficulty in breathing or swelling of the face or throat, he/she should be instructed to seek medical assistance immediately. Antibiotic prophylaxis should be performed to prevent infective endocarditis during first 6 months after coil implantation. Potential Adverse Events: Air embolism, Allergic reaction to drug/contrast, Apnea, Arrhythmia requiring medical treatment or pacing, Arteriovenous fistula, Bacterial endocarditis, Blood loss requiring transfusion, Chest pain, Damage to the tricuspid or pulmonary valves, Death, Embolization of the occluder, requiring percutaneous or surgical intervention, Endarteritis, False aneurysm of the femoral artery, Fever,Headache/migraine, Heart failure, Hemolysis after implantation of the occluder, Hypertension, Hypotension or shock, Infection, Myocardial infarction, Occluder fracture or damage, Perforation of the heart or blood vessels, Stenosis of the left pulmonary artery or descending thoracic aorta, Stroke/TIA, Thromboembolism (cerebral or pulmonary), Valvular Regurgitation, Vessel damage at the site of groin puncture (loss of pulse, hematoma etc.)