

CONGENITAL CARDIOLOGY TODAY

Timely News and Information for BC/BE Congenital/Structural Cardiologists and Surgeons

Volume 9 / Issue 7

July 2011

North American Edition

IN THIS ISSUE

The Emerging Use of 3-Dimensional Rotational Angiography in Congenital Heart Disease

by Evan Zahn, MD
~Page 1

Special: Watch videos of the 3D rotational
angiography of selected figures online:
www.CHDVideo.com/3D

Trans-catheter Pulmonary Valve Implantation: A Decade of Disruptive Technology

by Louise Coats, MRCP, PhD and
Philipp Bonhoeffer, MD
~Page 14

Special: Watch videos of the Melody®
implantation: www.CHDVideo.com/Valve

DEPARTMENTS

Medical News, Products and Information

~Page 20

CONGENITAL CARDIOLOGY TODAY

Editorial and Subscription Offices

16 Cove Rd, Ste. 200

Westerly, RI 02891 USA

www.CongenitalCardiologyToday.com

© 2011 by Congenital Cardiology Today ISSN:
1544-7787 (print); 1544-0499 (online).
Published monthly. All rights reserved.

PICS~AICS

(Pediatric & Interventional
Cardiac Symposium)

with Live Case Demonstrations

July 24-27 2011; Boston, MA USA

<http://www.picsymposium.com>

ESC

(European Society of
Cardiology) Congress 2011
August 27-31, 2011; Paris, France

[http://www.escardio.org/
congresses/esc-2011/Pages/
welcome.aspx](http://www.escardio.org/congresses/esc-2011/Pages/welcome.aspx)

Recruitment Ads: pages: 13, 18, 19, 20,
21, 22 and 23

The Emerging Use of 3-Dimensional Rotational Angiography in Congenital Heart Disease

By Evan M. Zahn, MD

Angiography of congenital cardiac anomalies has been somewhat limited since its inception by the fact that this technology only allows for two-dimensional imaging (2D) of complex three-dimensional structures. While advances such as axial angiography in the 1970's and digital acquisition in the 1990's greatly improved image quality, angiography has continued to be hampered by its 2-dimensional nature. This has become more and more evident over the past decade as it has become commonplace to view complex cardiac and vascular anatomy in three dimensions through the wide spread utilization of cardiac MRI and CT scanner technology.¹⁻³ These advanced imaging techniques have greatly added to our understanding of both native congenital cardiac anomalies as well as post-surgical anatomy.

Recently the ability to obtain rotational angiograms, which can be rapidly processed to provide 3D-dimensional images in the congenital^{4,5} catheterization laboratory have become commercially available. We believe this emerging technology, which has been widely used by interventional and neuro-radiologists,⁶⁻⁸ has the potential to: improve diagnostic accuracy, provide new information regarding the relationship between adjacent structures, add information regarding the mechanisms responsible for commonly seen lesions and improve assessment following selected interventions. In short, we believe that, in time, this technology will radically change the way cardiac catheterizations and

trans-catheter interventions are performed for patients with congenital and structural heart disease. Herein, we will describe our experience to date with this new imaging modality and use several cases to illustrate how three-dimensional rotational angiography (3DRA) can be of value in the congenital heart catheterization laboratory.

Technique

Obtaining high quality images using 3DRA involves some important technical modifications when compared with standard bi-plane angiography. Fundamental differences include:

- 1) use of a single imaging gantry,
- 2) high speed gantry rotation around the patient during image acquisition,
- 3) a relatively long time needed for acquisition of the data set (typically 4-5s) during which time the area of interest needs to be densely opacified with contrast media and
- 4) understanding that the images obtained are static rather than dynamic (i.e. no variation with the cardiac cycle). The static nature of these images has numerous implications when planning technique and interpreting the final product. For instance, when imaging the branch pulmonary arteries, contrast media that returns to the left atrium via the pulmonary veins during the acquisition may overlie the area of interest and result in unwanted artifact (see below).

With these differences in mind, our current technique is as follows. The lateral flat panel detector is placed in the "parked" position and the area of interest is placed in iso-center of the

CONGENITAL CARDIOLOGY TODAY

CALL FOR CASES AND OTHER ORIGINAL ARTICLES

Do you have interesting research results, observations, human interest stories, reports of meetings, etc. to share?

Submit your manuscript to: RichardK@CCT.bz

NuCLEUS-X™

Percutaneous Transluminal
Valvuloplasty
Catheter

The Center
of It All



B. Braun Interventional Systems Inc.
824 Twelfth Avenue
Bethlehem, PA 18018
Tel: 1-877-VENA CAV (1-86-2228)
Fax: 610-266-3982
www.bbraunusa.com

frontal flat panel detector by placing the spine in the center of the screen on the frontal projection, rotating the gantry 90 degrees and adjusting the table height until the sternum is just at the top of the image. The table is then locked in place and one of several automated 3DRA acquisition programs is selected based on body weight. Our system has an 8 cm frontal detector (Toshiba Infinix-i bi-plane flat panel catheterization, Toshiba, Japan) and was used for acquisition of all images featured in this report. While radiation doses were relatively high when the system was first installed, working with company engineers it was possible to develop a variety of acquisition protocols to minimize radiation exposure while maintaining a high level of image quality similar to the experience described by Glatz, et al.⁵

“We believe this emerging technology [3-Dimensional Rotational Angiography], which has been widely used by interventional and neuro-radiologists,⁶⁻⁸ has the potential to: improve diagnostic accuracy, provide new information regarding the relationship between adjacent structures, add information regarding the mechanisms responsible for commonly seen lesions and improve assessment following selected interventions.”

Currently our typical protocols acquire 100 frames during a 200 degree rotation over a 5 second time frame with a 0.5 second acquisition delay on either end of the rotation. The purpose of these delays is to ensure that an adequate amount of contrast is present in the area of interest throughout the acquisition period. Standard non-ionic contrast media (Optiray 320, Mallinckrodt, St. Louis, MO) is administered in a dose ranging between 0.5-2 cc/kg, via a synchronized power injector (Medrad Avanta, Warrendale, PA). In smaller children contrast is diluted with normal saline (in a ratio ranging between 1:2-3) to obtain an adequate volume to sustain dense opacification of the area of interest over the

entire acquisition period while minimizing contrast load.

Over time we have learned that our best images are obtained when contrast is injected through a multi-side hole catheter positioned proximal to (rather than within) the area of interest (in contra-distinction to standard bi-plane angiography). For example, to best image a stenosis of a proximal branch pulmonary artery, the injection is made in the right ventricle or main pulmonary artery rather than into the branch itself. Image acquisition was not gated to the cardiac or respiratory cycle, however both of these variables were manipulated during acquisition (see below) to minimize artifact and enhance image quality. The rotational 2D data set is automatically transferred to a reconstruction computer and subsequently to a dedicated 3D work-station (Vitrea, Vital Solutions). While the 2D rotational angiogram is available for review immediately, approximately 35 seconds are required until the 3D reconstructed images are available for viewing on the workstation. We have found that the unprocessed 2D rotational angiogram as well as the 3D surface rendered images and reconstructed cross-sectional tomographic images all provide useful diagnostic information that are complimentary to one another.

Typically, 3-5 minutes are spent performing post-processing on the 3D images (currently performed table side using sterile controls), obtaining quantitative vessel analysis from the cross-sectional tomographic slices and selecting reference images which can then be routed into the procedure suite to be used throughout the remainder of the case as roadmaps. The 3D surfaced-rendered images can be rotated in limitless projections including virtual projections that could never be actually obtained using bi-plane angiography. We typically use the 3DRA images to guide gantry position for subsequent 2D angiography and fluoroscopic-guided catheter manipulation during interventions. Importantly, because the data set used for reconstruction of the 3D images is obtained over several seconds, any movement during this acquisition period may result in significant artifact and image degradation. For this reason, we have utilized general anesthesia in nearly all cases performed in children which allows us to suspend respirations during the rotational acquisition. In conscious, cooperative patients this can be replaced with a simple breath-hold. Additionally, we have found that in many cases rapid ventricular pacing (180-280 beats/minute) or bolus injection of adenosine (0.1-0.4 mg/kg) during image acquisition greatly improves image quality (Video 1). These maneuvers transiently depress cardiac output and blood pressure, resulting in delayed passage of contrast media through the area of interest and improved opacification throughout the entire rotation, thereby enhancing image quality. Additionally, these maneuvers reduce

motion artifact caused by cardiac contractility, and when imaging the pulmonary arteries, diminish or eliminate the appearance of contrast in the pulmonary veins and left atrium both of which can cause unwanted artifact. These modifications are particularly important when trying to image more dynamic structures, such as the branch pulmonary arteries after Tetralogy of Fallot repair associated with free pulmonary insufficiency versus more sluggish circulations such as the pulmonary arterial circulation after cavo-pulmonary connection. To date we have used these maneuvers in over 60 cases and on the whole feel they have greatly enhanced the quality of our 3D images while not resulting in any major adverse events. Our current technique and algorithm for obtaining high quality 3DRA are shown in Figure 1.

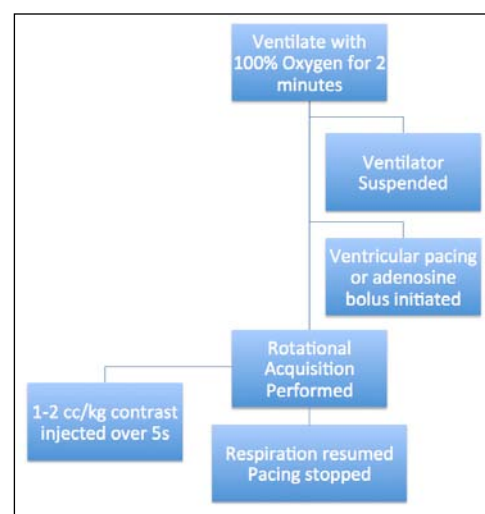


Figure 1. Flow chart describing the current sequence of events used in our laboratory to acquire 3DRA. See video 1 (www.CHDVide.com/3D) to view an acquisition.

Case 1: Improved Imaging of the Right Ventricular Outflow Tract Prior to Trans-catheter Valve Placement

A six-year-old, 22 kg girl born with an initial diagnosis of double outlet right ventricle was taken to the catheterization suite for consideration of Melody valve (Medtronic Inc., Minneapolis, MN) implantation for a primary indication of pulmonary insufficiency. Her previous history was notable for: initial physiologic repair using a 12 mm pulmonary homograft at 11 months of age, requirement for conduit stenting at 16 months of age, conduit replacement with a 19 mm pulmonary homograft at 3.5 years of age and the requirement for stenting of the second conduit at 4.2 years of age. At the time of catheterization, cardiac MRI revealed that she had severe pulmonary regurgitation (PRF =46%), a markedly enlarged RV

(RVEDVI=161 cc/m²) and normal bi-ventricular systolic function (RVEF = 54%). Catheterization was performed under general anesthesia and following hemodynamic assessment, a single 3DRA was performed. After suspending respirations, the right ventricle was paced at 220 beats/min and 60 cc of a 1:2 mix of contrast and saline (1.3 cc/kg of contrast) were injected via an 8F multi-track

catheter positioned over a guide wire into the RVOT.

Figure 2 depicts the 3D volume rendered surface images obtained in this case. These images demonstrate that using this technique, a single injection, provides details of the right heart anatomy from the trabeculations of the right ventricle to the tertiary branch pulmonary arteries. In Panel A, a straight frontal projection, the details of the previously placed conduit stent, as well as its relationship to the sternum (represented by sternal wires) can be seen in striking detail. In Panel B, the image has been rotated to an angle optimized to elongate the conduit and view the bifurcation of the branch pulmonary arteries (in this case a "virtual angle" (RAO 21/CRA 59), not truly obtainable with current equipment). Note the proximal right pulmonary artery stenosis, not visible without extreme cranial angulation. In Panel C, the image has been rotated from a standard "lateral projection" (LAO 90/CRA) typically used for most conduit valve implantations to a more optimal angle (LAO79/CRA22) for visualizing the entire length of the conduit in this patient. Images such as these will be of great value when assessing more irregular right ventricular outflow tracts (e.g. after transannular repair of Tetralogy of Fallot) for suitability of implantation of the next generation of pulmonary valves. From the same data set it is possible to obtain orthogonal slices (axial, longitudinal and coronal) through the

area of interest (in this case the conduit), which can be used to make measurements of the area being considered for intervention (Panel D). These measurements are based on calibration performed during 3D reconstruction of the 2D planar images, and included in the resultant 3D images as pixel spacing. This information is converted to patient coordinates or linear measurements at the Vitrea workstation, thus eliminating the need (and inherent errors associated with) for calibration to a catheter or other object.

This technique is similar to measurement made with MRI or CT scan and recent work from our group (Berman, et al submitted for publication) suggests that measurements obtained in this way and those obtained from 2-D biplane angiography have a very high correlation coefficient, at least in vascular structures with limited pulsatility. We believe, in fact, that measurements made in this fashion which are obtainable in a limitless number of planes and virtually will always "profile" the lesion in question, will be more consistently accurate than those made from traditional 2 dimensional angiography. It is, however, important to remember that measurements made using this technology currently utilize static images and therefore do not reflect variations in dimension seen throughout the cardiac cycle. This issue, which is most important in dynamic circulations, will likely be overcome with the advent of 4D imaging in the next generation of catheterization

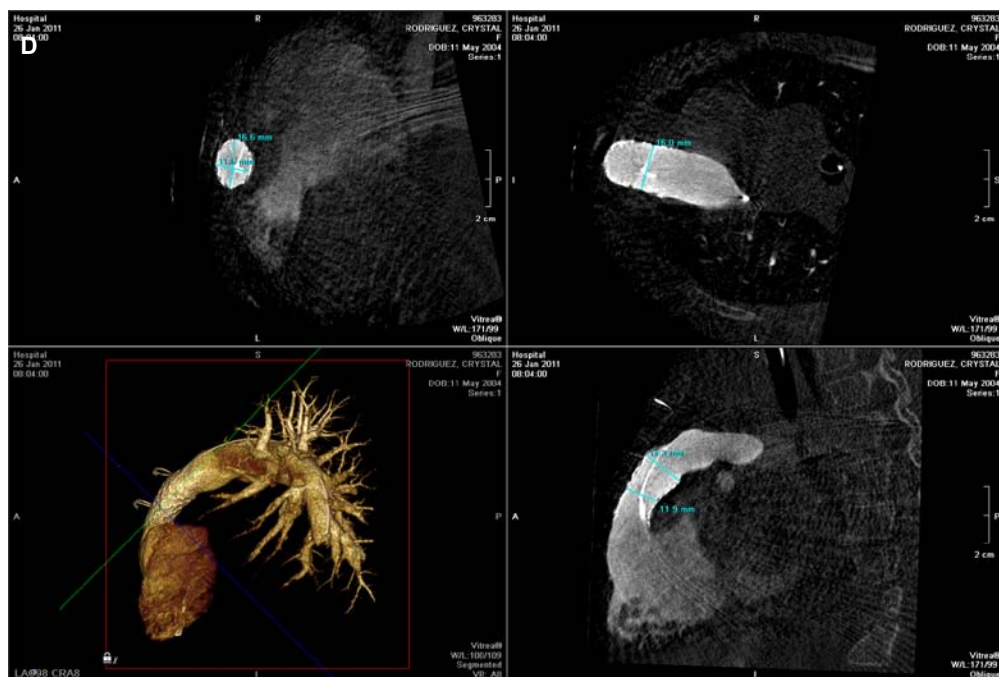
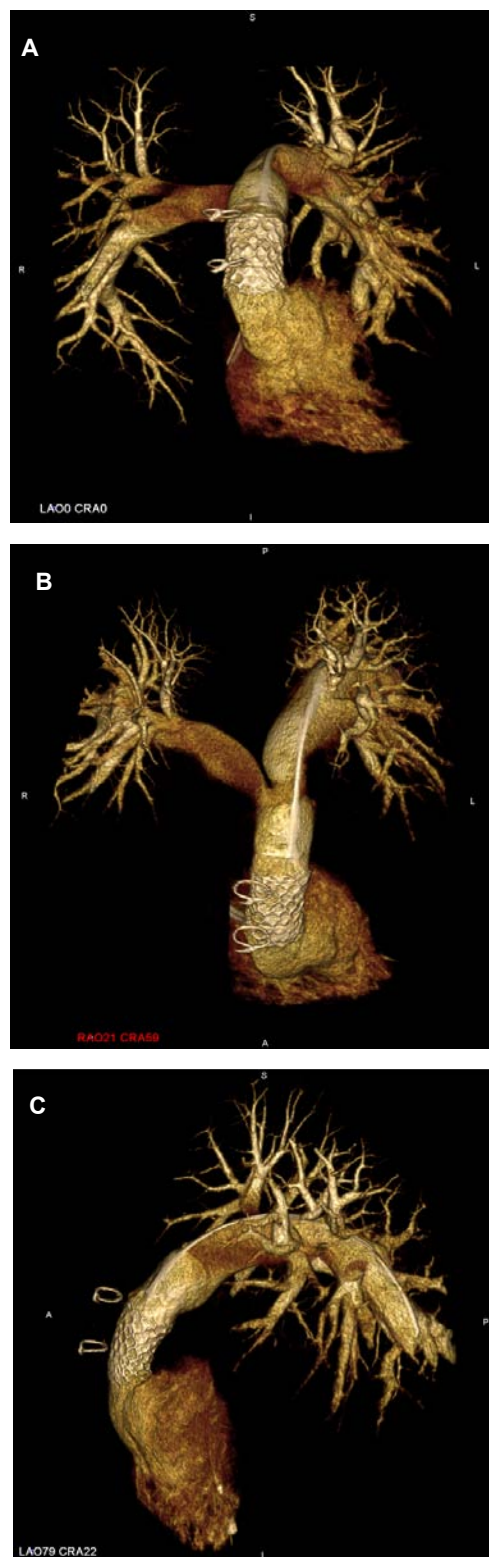


Figure 2. 3DRA images of the right heart in a six- year-old prior to Melody valve insertion. Note the excellent imaging of the PA bifurcation, including a proximal right PA stenosis seen with virtual angulation (B) as well as the ability to obtain diameter measurements in multiple orthogonal planes including cross-sectional plane which is never possible with 2D angiography (D).

Melody® Transcatheter Pulmonary Valve

Ensemble® Transcatheter Valve Delivery System

Indications for Use:

The Melody TPV is indicated for use as an adjunct to surgery in the management of pediatric and adult patients with the following clinical conditions:

- Existence of a full (circumferential) RVOT conduit that was equal to or greater than 16 mm in diameter when originally implanted and
- Dysfunctional RVOT conduits with a clinical indication for intervention, and either:
 - regurgitation: \geq moderate regurgitation, or
 - stenosis: mean RVOT gradient \geq 35 mm Hg

Contraindications: None known.

Warnings/Precautions/Side Effects:

- DO NOT implant in the aortic or mitral position. Preclinical bench testing of the Melody valve suggests that valve function and durability will be extremely limited when used in these locations.
- DO NOT use if patient's anatomy precludes introduction of the valve, if the venous anatomy cannot accommodate a 22-Fr size introducer, or if there is significant obstruction of the central veins.
- DO NOT use if there are clinical or biological signs of infection including active endocarditis.
- Assessment of the coronary artery anatomy for the risk of coronary artery compression should be performed in all patients prior to deployment of the TPV.
- To minimize the risk of conduit rupture, do not use a balloon with a diameter greater than 110% of the nominal diameter (original implant size) of the conduit for pre-dilation of the intended site of deployment, or for deployment of the TPV.
- The potential for stent fracture should be considered in all patients who undergo TPV placement. Radiographic assessment of the stent with chest radiography or fluoroscopy should be included in the routine postoperative evaluation of patients who receive a TPV.
- If a stent fracture is detected, continued monitoring of the stent should be performed in conjunction with clinically appropriate hemodynamic assessment. In patients with stent fracture and significant associated RVOT obstruction or regurgitation, reintervention should be considered in accordance with usual clinical practice.

Potential procedural complications that may result from implantation of the Melody device include: rupture of the RVOT conduit, compression of a coronary artery, perforation of a major blood vessel, embolization or migration of the device, perforation of a heart chamber, arrhythmias, allergic reaction to contrast media, cerebrovascular events (TIA, CVA), infection/sepsis, fever, hematoma, radiation-induced erythema, and pain at the catheterization site.

Potential device-related adverse events that may occur following device implantation include: stent fracture resulting in recurrent obstruction, endocarditis, embolization or migration of the device, valvular dysfunction (stenosis or regurgitation), paravalvular leak, valvular thrombosis, pulmonary thromboembolism, and hemolysis.

For additional information, please refer to the Instructions for Use provided with the product.

CAUTION: Federal law (USA) restricts this device to sale by or on the order of a physician.

Melody and Ensemble are registered trademarks of Medtronic, Inc.



Medtronic

Hope, Restored.

A revolutionary treatment option designed to delay the need for surgical intervention.

Restore hope for your patients with RVOT conduit dysfunction.

www.Melody-TPV.com



Melody®

TRANSCATHETER PULMONARY VALVE (TPV) THERAPY

Humanitarian Device. Authorized by Federal law (USA) for use in pediatric and adult patients with a regurgitant or stenotic Right Ventricular Outflow Tract (RVOT) conduit (\geq 16 mm in diameter when originally implanted). The effectiveness of this device for this use has not been demonstrated.

laboratories. This patient underwent successful Melody valve implantation and was discharged home within 24 hours.

Case 2: Improved Imaging of Multiple Aorto-pulmonary Collaterals (MAPCA's) in a Newborn with Single Ventricle and Pulmonary Atresia

A seven-day-old, 2.7 kg neonate with multiple congenital anomalies was diagnosed by echocardiography as having a complex form of single ventricle, pulmonary atresia, absent central pulmonary arteries and multiple aorto-pulmonary collateral arteries (MAPCA). To best plan his surgical strategy, a catheterization was performed to delineate the precise anatomic location, size and distribution of his MAPCA's. Due to his small size, young age and presumed need for several future cardiac catheterizations, we felt it was important to minimize his radiation and contrast exposure at this initial catheterization without sacrificing diagnostic precision. A 4F pigtail catheter was placed into his distal transverse aortic arch and rotational angiography performed using 15 cc of a 1:2 contrast/saline mixture (1.9 cc/kg of contrast). As this case was early in our experience, respirations were held; however, overdrive pacing was not performed.

The most pertinent images are shown in Figure 3. As seen in panel A, a simple frontal projection, this single injection provided visualization of all MAPCA's, their relationship to one another, relative size and distribution and areas of stenosis. With the ability to rotate the image to views which are unobtainable with standard 2D angiography (note the "down the barrel" view of the thoracic aorta in Panel E) and segment and

selectively colorize individual MAPCA's (panels B-D) we were able to confirm the individual vessel origins from the anterior

thoracic aorta and follow the tortuous course of each complex overlapping MAPCA (something that is not always

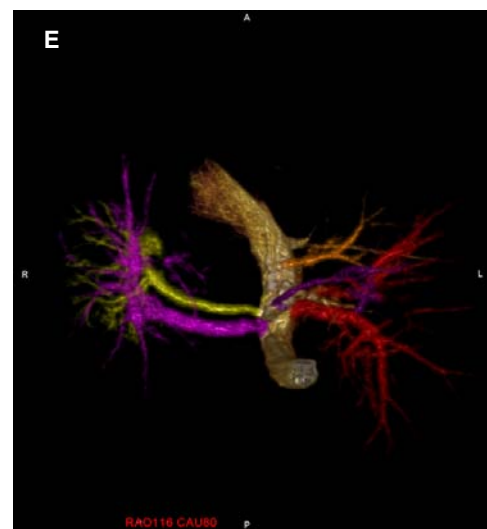
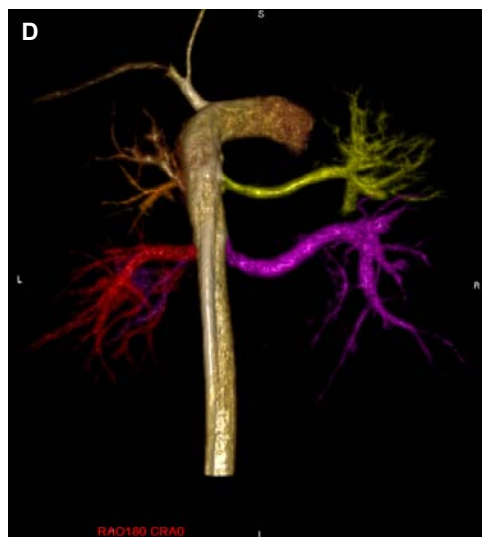
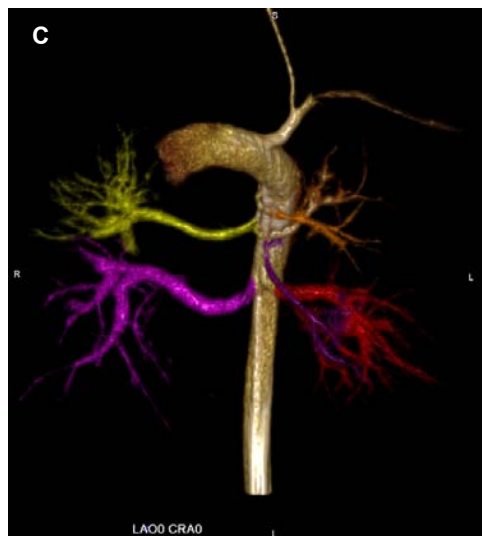
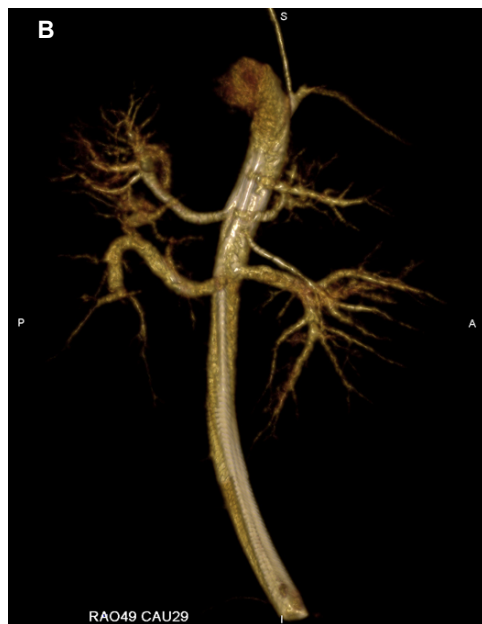
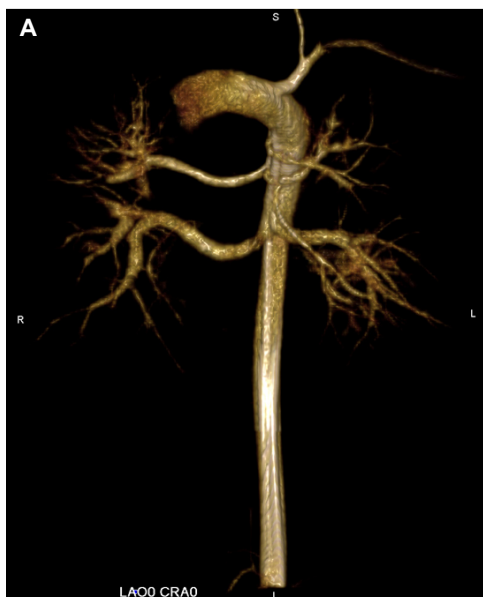
Figure 3. 3DRA aortography in a newborn with MAPCA's. In Panels C-D segmentation has been used to isolate the individual MAPCA's and in this case colorize them for easy identification and tracking. This technique also allows for individual post-processing of various segments to maximize diagnostic quality as well temporarily "remove" segments to eliminate overlay when needed.

easily done with 2D angiography). It is important to note that since these are static images the ability to diagnose single or dual supply to individual lung segments through the observance of contrast "wash-in" or "wash-out" is not currently possible with 3DRA alone and selective 2D injections may still be required. However, cannulation of these small and tortuous vessels is greatly simplified with a 3DRA road map to guide gantry angulation and catheter movement. Four months later, this baby underwent palliative stent placement into one of the MAPCA's after a diagnosis of severe stenosis by 3DRA was associated with worsening cyanosis. Currently the baby is stable with this form of palliation.

Case 3: Improved Imaging of Complex Pulmonary Artery Stenoses after Fontan Completion

A four-year-old, 16 kg patient with an initial diagnosis of Hypoplastic Left Heart Syndrome underwent a Stage 1 Norwood reconstruction as a newborn, followed by a bi-directional cavo-pulmonary anastomosis and further surgical reconstruction of his aortic arch at 6 months of age. Prior to completion of his fenestrated extra-cardiac Fontan, he was noted by 3DRA to have bilateral branch

PA stenosis, with the mechanisms being an acute take-off of the right PA (mild) from the superior vena cava and a torsion lesion of the left PA (Figure 4, A and B). During surgery a large-sized vascular stent was placed into the proximal left PA under direct vision, however, in the post-operative period the patient continued to suffer from excessive cyanosis. Seventeen days after surgery he was taken to the catheterization laboratory where 3DRA performed via the right internal jugular vein (secondary to bilateral femoral venous obstruction) and utilizing retrograde RV pacing, revealed what was now significant proximal right PA stenosis and a more distal LPA

stenosis, past where the operatively placed stent ended (Figure 4, C and D). Note how the proximal RPA, notoriously hard to visualize after extra-cardiac Fontan, is well seen from a virtual posterior vantage point (LAO 138). Following bilateral stent placement, SVC and right upper lobe angioplasty, full thickness MIP projections clearly demonstrated the final result, in particular, the complex relationship between the proximal stents and the cavo-pulmonary anastomosis (Figure 4E). Following these interventions, the patient made a rapid recovery and was discharged home a few days later with oxygen saturations in the high 80's.

Case 4: Assessing Complex Post-operative Aortic Obstruction

A 17-month-old born prematurely (30 weeks, 1.8 kg) with Hypoplastic Left Heart Syndrome underwent a Hybrid Stage 1 palliation and followed by operative adjustment of her PA bands x 2 as well as PDA stent enlargement and placement of a retrograde distal aortic arch stent. At five months of age she underwent a comprehensive Stage 2 operation consisting of aortic arch reconstruction, removal of stent material, bi-directional cavo-pulmonary anastomosis, PA reconstruction and atrial septectomy.

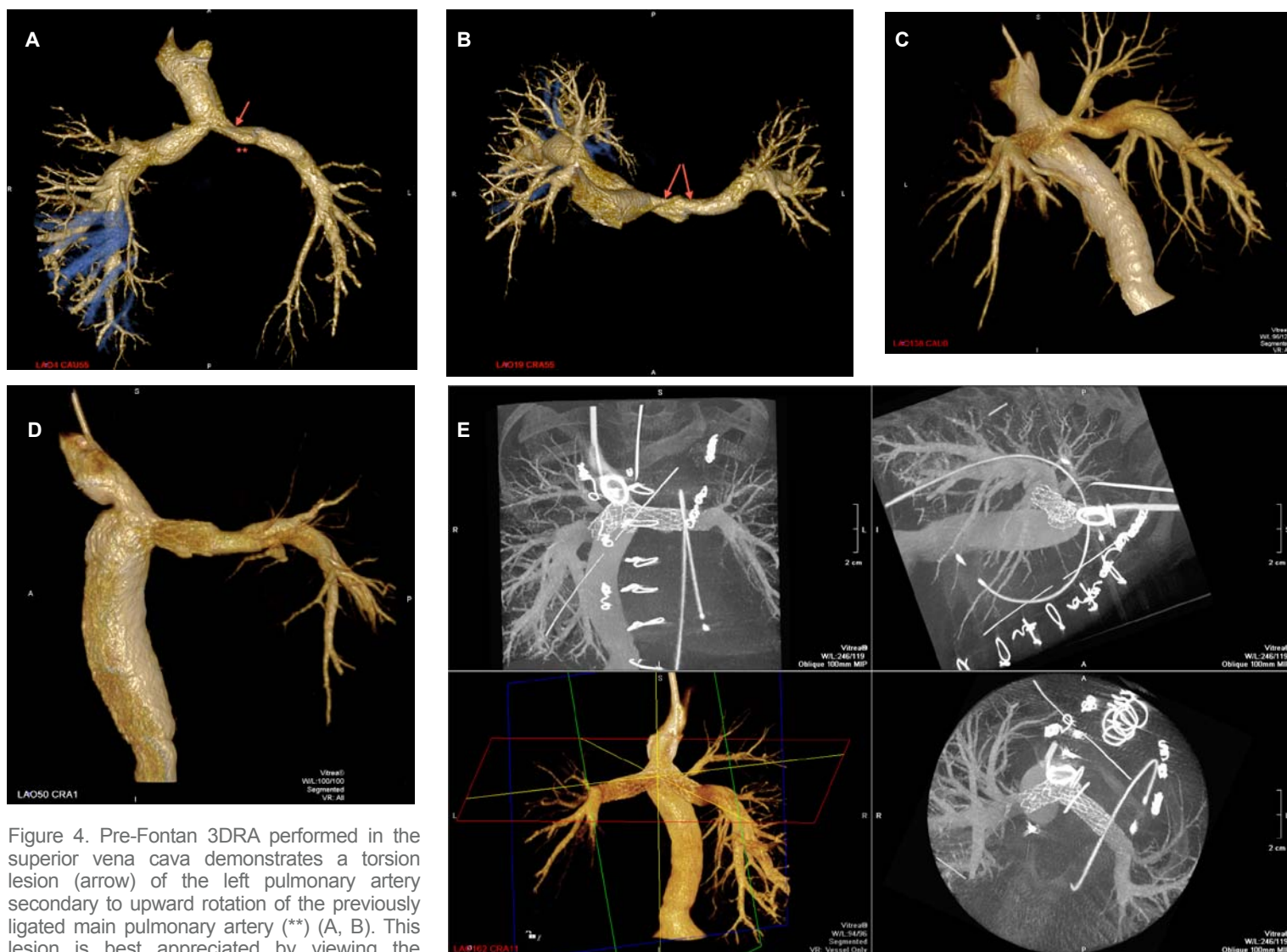


Figure 4. Pre-Fontan 3DRA performed in the superior vena cava demonstrates a torsion lesion (arrow) of the left pulmonary artery secondary to upward rotation of the previously ligated main pulmonary artery (**) (A, B). This lesion is best appreciated by viewing the structures from virtual angles from nearly directly above and/or below the lesion. The blue-segmented structures are the right pulmonary veins which drain faster than the left veins likely due to the LPA stenosis. As these structures overlay the area of interest (the right pulmonary artery), they have been segmented, colorized and made transparent. Following the Fontan procedure (C-E), the importance of the proximal right PA stenosis which appears more significant than prior to the operation, can only be appreciated by virtually viewing the Fontan from the back (C, LAO 138). The distal left PA stenosis (D) is visualized best by segmenting and removing the right pulmonary artery and thereby eliminating overlap in this steep projection (LAO 50). After implantation of 2 stents to treat these lesions, full thickness transparent MIP images (E) can be rotated in multiple planes to gain a better understanding of the result and the relationship of these stents to the one another and the entrance of the superior vena cava.

The current catheterization was performed at 7 months of age (6.2 kg), primarily to further delineate a suspected ascending aortic obstruction detected by echocardiography and explore the possibility of treatment with catheter intervention. Hemodynamic evaluation confirmed an important obstruction prior to the take-off of the head and neck vessels. Via hepatic venous access, a Berman angiographic catheter was positioned in the neo-ascending aorta and with respirations suspended, 30 cc of diluted contrast (1:2) were injected at 6cc/second.

Although 2D angiography demonstrated the obstruction, it was not possible to tell the relationship of this stenosis to the hypoplastic native aortic root (i.e. coronary blood supply) or the single origin of the head and neck vessels. By rotating the 3DRA surface-volume rendered images

and using software to obliquely “cut through” the image, we were able to clearly show that stent placement across this obstructive fold would by necessity come in close proximity and/or cover the origin of the native aorta and head and neck vessels (Figure 5). After discussion with her surgeon it was decided to take the patient back to the operating room where she underwent successful relieve of this complex obstruction.

“By rotating the 3DRA surface-volume rendered images and using software to obliquely “cut through” the image, we were able to clearly show that stent placement across this obstructive fold would by necessity come in close proximity and/or cover the origin of the native aorta and head and neck vessels (Figure 5).”

Case 5: Previously Unrecognized Clinically Important Branch Pulmonary Artery Stenosis late after Fontan Operation

A 10 year old (27 kg) born with an initial diagnosis of tricuspid atresia, transposed great arteries and coarctation of aorta underwent a modified Norwood procedure followed by a bidirectional caval pulmonary anastomosis and an extra-cardiac Fontan procedure. Following the Fontan procedure he required implantation of a large stent across the anastomosis of his Fontan conduit and inferior vena cava to treat persistent lower body edema.

The current catheterization was performed for worsening exercise intolerance. Hemodynamic evaluation was unrevealing as was 2-dimensional angiography of his Fontan circulation with the exception of what appeared to be diffuse hypoplasia of his left pulmonary artery (Figure 6). With respirations suspended, RA was performed with an injection in the Fontan conduit using 60 cc of diluted contrast (2:1) injected at 12 cc/second. Surface volume rendered images rotated to virtual angles essentially looking up through the Fontan circulation from the feet towards

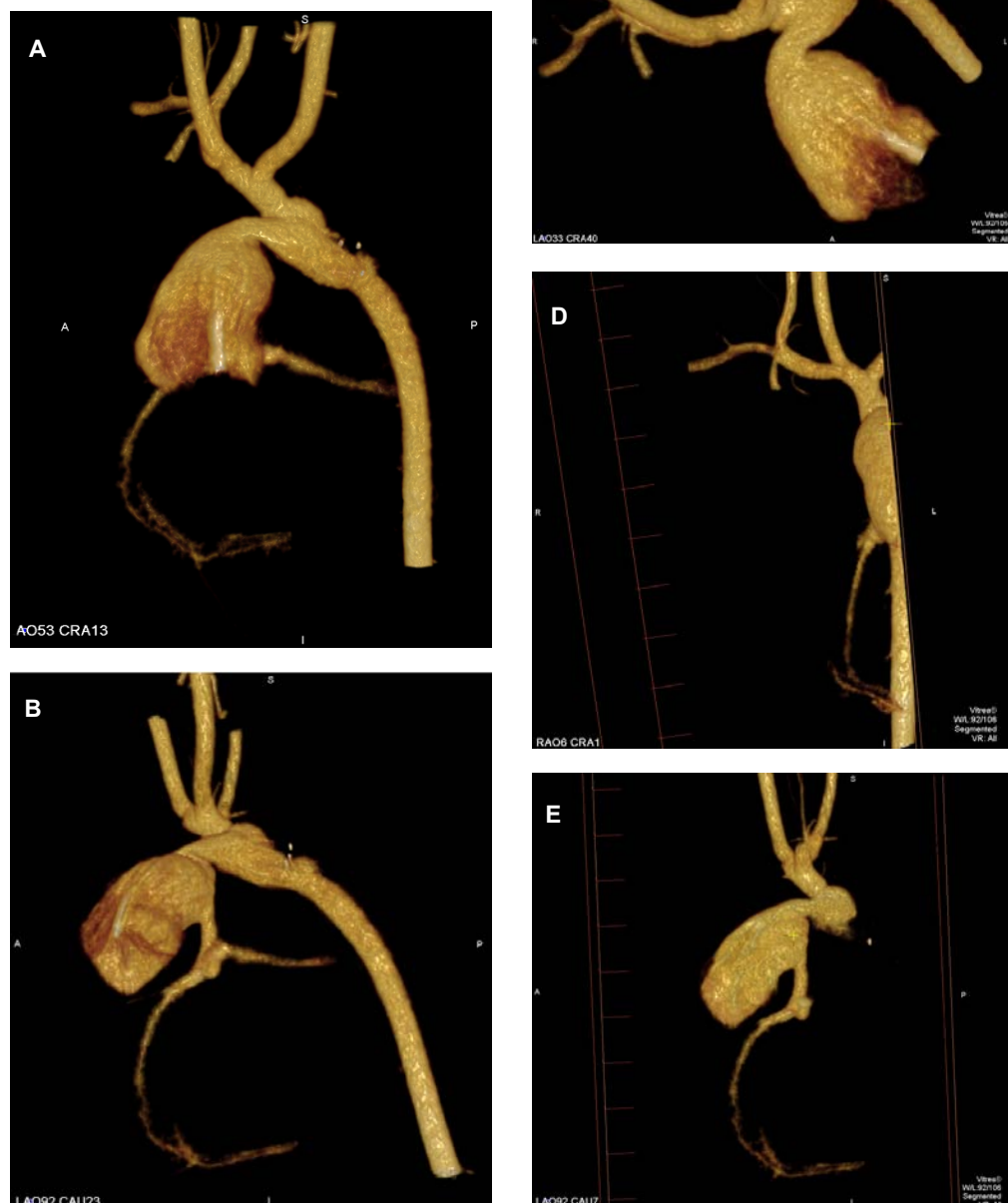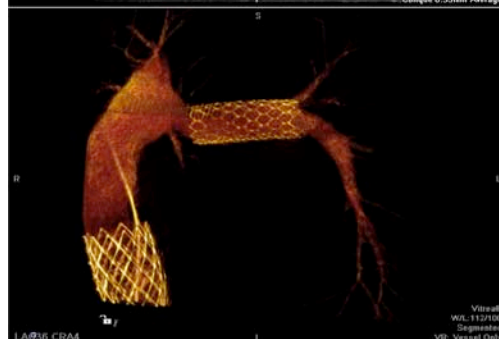
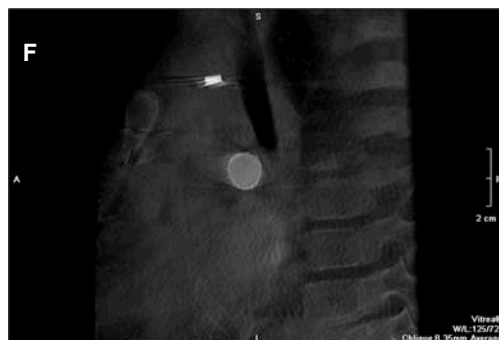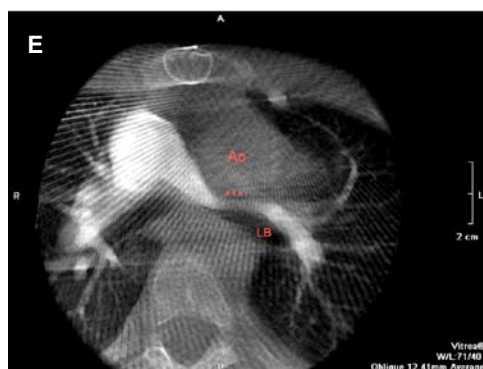
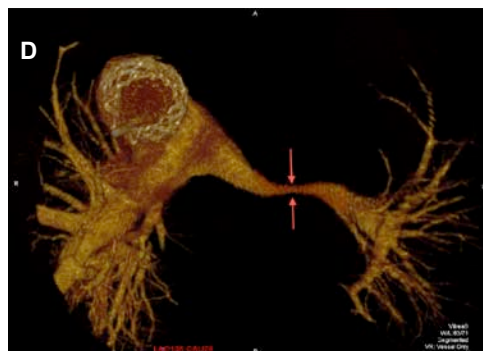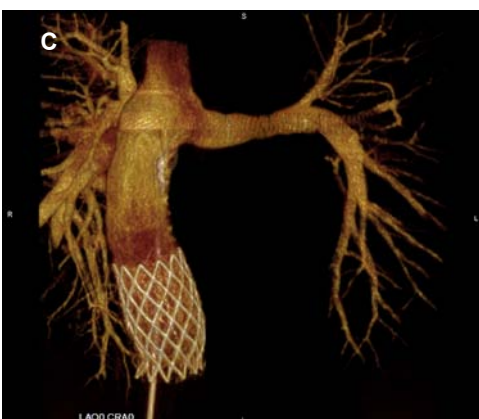


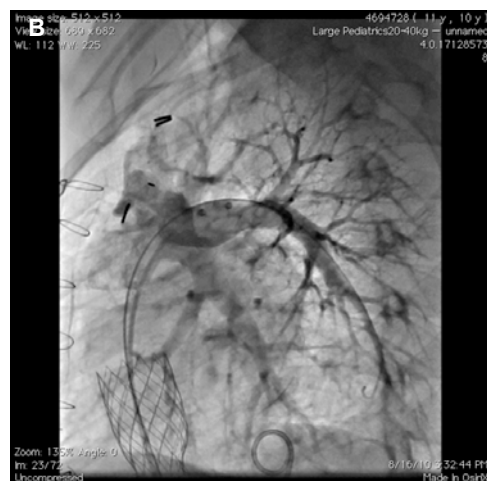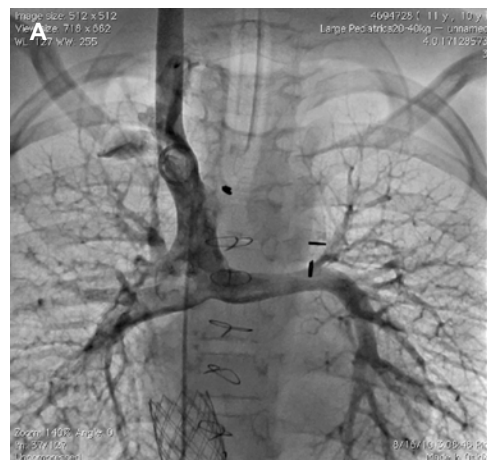Figure 5. 3DRA aortography illustrating an unusual ascending aortic arch obstruction following Norwood-type aortic reconstruction. The lesion appears to be a fold (A-C) in close proximity to the takeoff of both the single vascular origin of the head and neck vessels, as well as the hypoplastic native ascending aorta which in this circulation acts as a single coronary artery. Using software features which allows for planar “cutaways” of the 3D surface rendered image (D, E) it is clear that to successful stent this lesion, the origins of both of these structures will need to be crossed. Figure D is meant to show the reader where the planar cutaway has been made, and Figure E the diagnostic image obtained by rotating this image roughly 90 degrees.

the head, revealed an important stenosis of the left pulmonary artery where 2D angiography had suggested hypoplasia. Evaluation of the axial tomographic images clearly showed the lesion to be secondary to compression from a dilated

ascending aorta. Following implantation of an adult-sized stent, repeat 3DRA not only showed resolution of the lesion in all planes but also the impact of this intervention on the posterior wall of the aorta. Whether this slight deformation of

the aortic wall will be of importance clinically is unknown, but there is little argument that knowledge of this relationship is beneficial in long term follow-up.



“The current catheterization was performed for worsening exercise intolerance. Hemodynamic evaluation was unrevealing as was 2-dimensional angiography of his Fontan circulation with the exception of what appeared to be diffuse hypoplasia of his left pulmonary artery (Figure 6).”

Figure 6. (A,B) AP and Lateral 2-dimensional angiography performed with injections in the superior vena cava as well as selective left pulmonary artery (LPA) fail to demonstrate a discrete obstruction to flow in the LPA. Similarly, a 3D volume surface rendered image in the frontal projection shows what appears to be diffuse hypoplasia of the LPA (C). It is not until the image is rotated to the virtual view of LAO 135/CAUDAL 78 that a severe narrowing of the LPA in the anterior-posterior direction is seen (D, arrows). An axial MIP (E) clearly demonstrates the mechanism of stenosis to be a result of anterior compression (***) of the LPA by a dilated reconstructed aorta (Ao). Note the proximity of the left main stem bronchus (LB) to the stenosis. Following stent placement, repeat 3DRA shows improvement in LPA diameter in multiple planes as well as the slight flattening of the posterior wall of the aorta caused by stent placement (***). Importantly, there does not appear to be any compression of the left bronchus (++) by the stent.

Case 6: Creating a Roadmap for Accessing Complex Pulmonary Arterial Anatomy

A 20-month-old born with pulmonary atresia, ventricular septal defect (PAVSD), multiple aorto-pulmonary collaterals (MAPCA's) and absent central pulmonary arteries underwent a series of staged procedures including unifocalization of MAPCA's to a conduit followed by several interventional catheterizations which

culminated in surgical VSD closure and placement of a new Contegra (Medtronic, MN) conduit.

Two months following surgery a planned interventional catheterization was undertaken to assess the surgical results and perform any PA rehabilitation, which might be required. Hemodynamic assessment revealed that right ventricular pressure was elevated near systemic levels secondary to what was suspected

to be numerous proximal and distal branch pulmonary artery stenoses. In view of this infant's previous history of significant radiation exposure (secondary to numerous radiologic procedures including cardiac catheterization), as well as the complexity of her reconstructed pulmonary arterial anatomy, we began our angiographic assessment with 3DRA (Figure 7). With respirations suspended, 0.6 mg of adenosine were injected centrally and 30 cc of diluted contrast (1:2) were injected into the right ventricular outflow tract over at 6cc/second. In this case a single rotational angiogram and reconstruction provided enough detailed diagnostic information regarding areas of proximal and distal branch pulmonary artery stenosis, and the relationships of the various reconstructed branches to one another, that no other angiograms were needed prior to performance of a series of interventions aimed at further rehabilitating the branch pulmonary arteries. Importantly, this single RA injection provided roadmaps and gantry angles for performance of this complex case, greatly facilitating catheter and wire passage and contributing to the safety and efficacy of this procedure. Following a lengthy intervention right heart hemodynamics improved and the child was discharged home the following day.

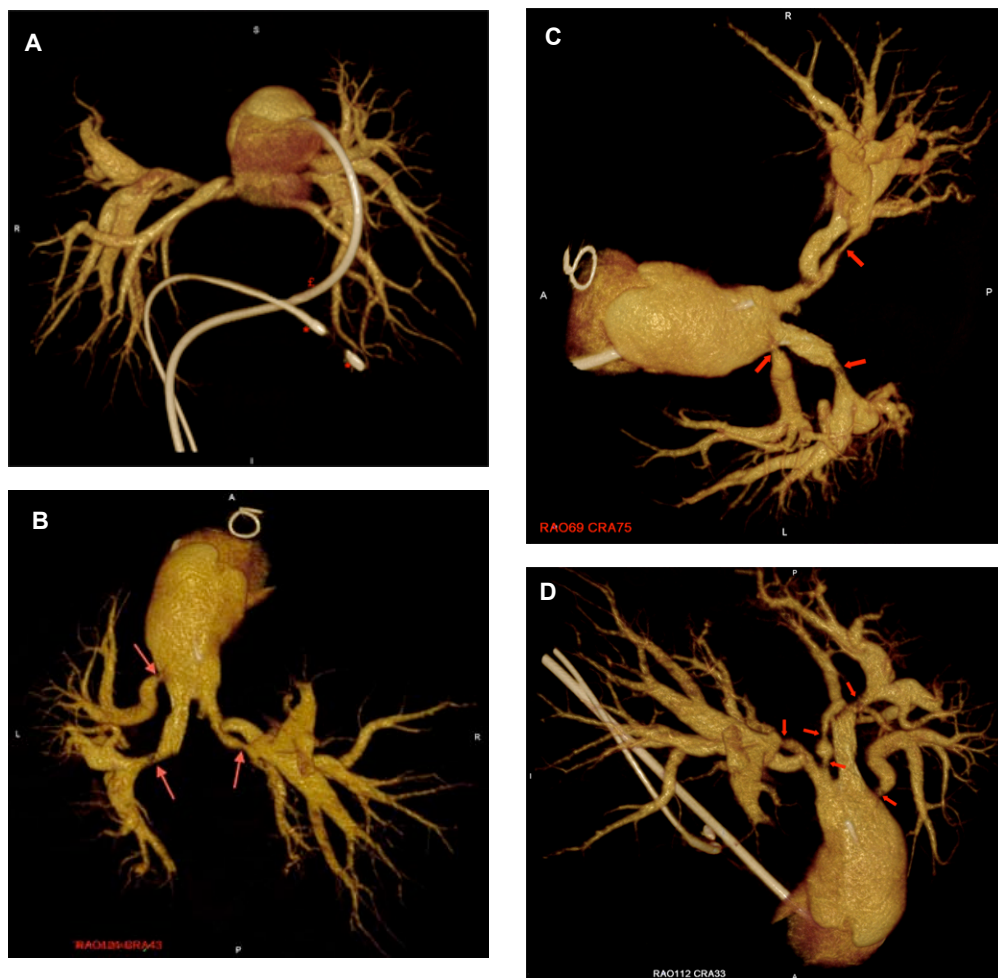

Figure 7. 3DRA of complex unifocalized pulmonary arterial anatomy after physiologic repair using an RV-PA conduit. Note the catheter in the RV apex used for overdrive pacing (*) as well as the angiographic catheter in the RV outflow tract (£). While a straight frontal projection (A) reveals little information, rotating the 3DRA volume rendered image in multiple planes reveals multiple stenoses (arrows), each of which can be seen using a single injection (B-D). Despite the complexity of these lesions and their proximity to one another, rotation of the volume rendered image allows each lesion to be perfectly profiled for the purposes of measurements and planning intervention.

In view of this infant's previous history of significant radiation exposure (secondary to numerous radiologic procedures including cardiac catheterization), as well as the complexity of her reconstructed pulmonary arterial anatomy we began our angiographic assessment with 3DRA (Figure 7)."

Scientific
Software
Solutions

Introducing

PedCath8 Congenital Cath Reporting

now compatible with

IMPACT Registry™

www.PedCath.com - tel. 434.293.7661

Case 7: Imaging Complex Intra-cardiac Baffle Obstruction with 3DRA

A 3.5-year-old, 19 kg patient with an initial diagnosis transposition of the great arteries, VSD and pulmonic stenosis underwent initial palliation with a PDA stent and subsequent Rastelli repair at age 13 months.

“Hemodynamics revealed systemic right ventricular pressure secondary to severe conduit stenosis and a peak gradient between 10-20 mmHg across the sun-aortic baffle (left ventricular outflow tract). Two separate rotational acquisitions were performed in the left and right ventricles utilizing breath-holding and RV overdrive pacing.”

The current catheterization was undertaken due to suspicions raised on echocardiography of worsening conduit stenosis as well as narrowing of the intra-ventricular tunnel from the left ventricle to the aorta. Hemodynamics revealed systemic right ventricular pressure secondary to severe conduit stenosis and a peak gradient between 10-20 mmHg across the sun-aortic baffle (left ventricular outflow tract). Two separate rotational acquisitions were performed in the left and right ventricles utilizing breath holding and RV overdrive pacing. The images of the left ventricular outflow tract were particularly revealing in that the anatomic degree of stenosis could be assessed in multiple planes (Figure 8). In fact, using standard projection angles (30 degrees RAO, 60

degrees LAO with 20 degrees cranial), the degree of baffle stenosis appeared rather minimal and only when the image

was rotated to unobtainable angles was the severity of the lesion appreciated.

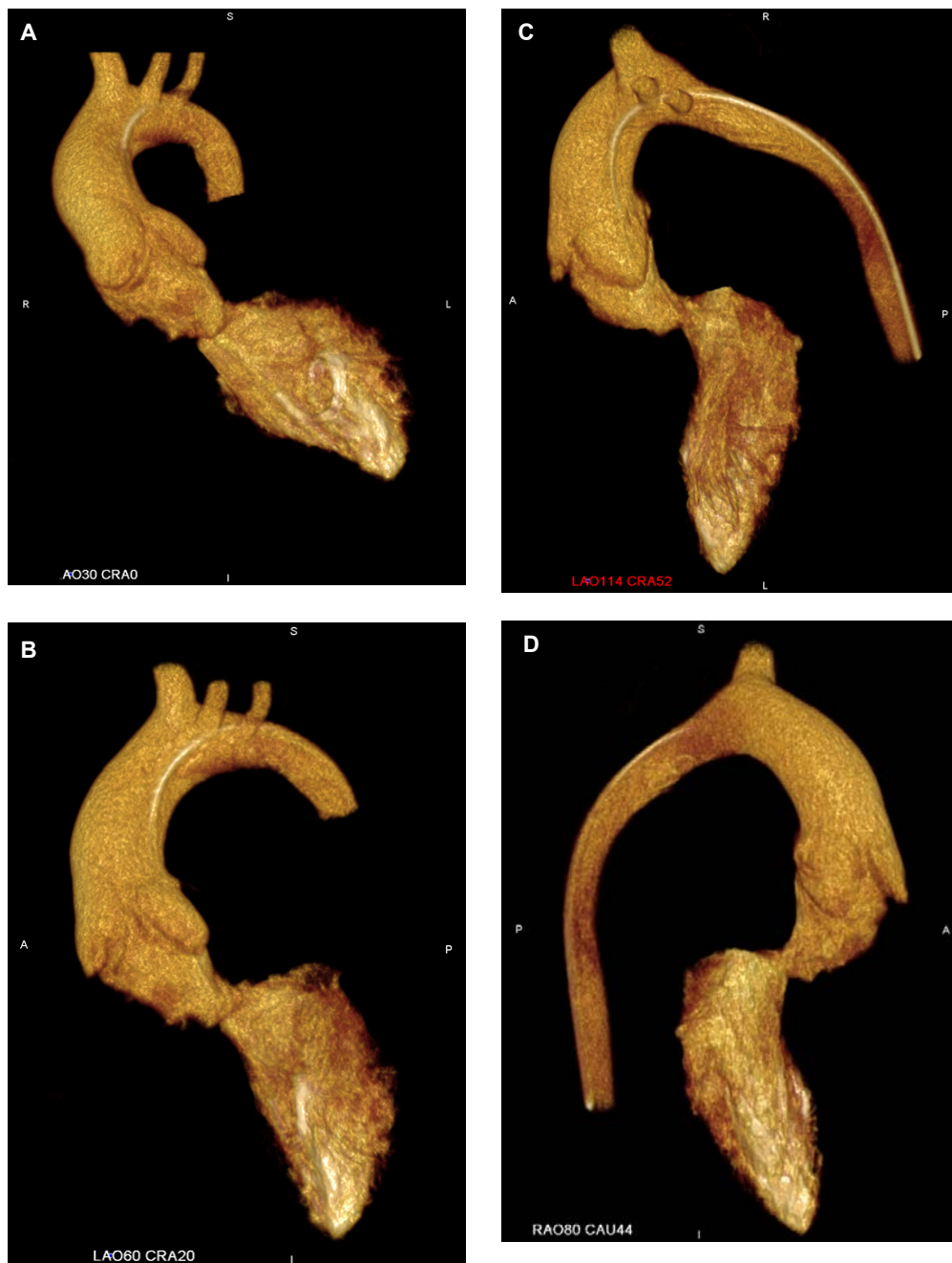


Figure 8. 3DRA performed in the left ventricle to assess the left ventricular outflow tract after Rastelli operation. Using standard projections (A, B) the obstruction appears mild. It is not until the image is rotated to virtual angles that the true potential severity of the lesion can be appreciated (C, D).

PedCath8 Congenital Cath Reporting

now compatible with **IMPACT Registry™**

Introducing

Scientific
Software
Solutions

www.PedCath.com - tel. 434.293.7661

The patient underwent successful bare metal stent placement into the RV-PA conduit with a plan for future transcatheter valve implantation and careful monitoring of the left ventricular outflow tract obstruction.

Summary

In summary, we believe that the ability to perform 3D rotational angiography in the catheterization laboratory represents a paradigm shift in angiographic imaging of congenital heart lesions. This technology provides significantly more information regarding the exact mechanisms underlying stenotic lesions, a limitless amount of “views” from a single injection, information about the influence and effect of surrounding structures on the areas of interest, the ability to perform quantitative vessel analysis without the inaccuracies inherent to calibration and a

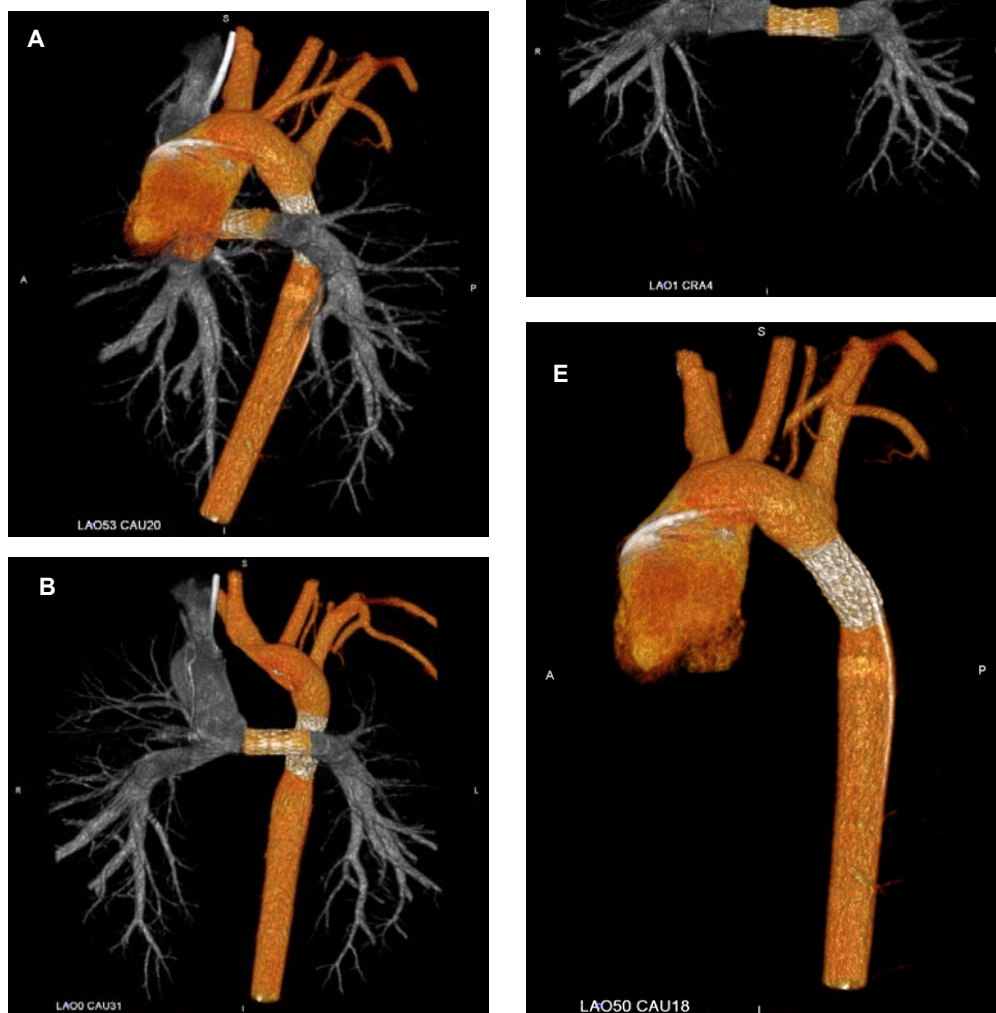


Figure 9. Simultaneous injections into the superior vena cava and aorta in this 3.5 year old that had undergone aortic arch reconstruction and a cavo-pulmonary anastomosis were performed. Through segmenting the various structures, this single injection allows for imaging all of the pertinent anatomy as one (A), as partial images (B) (i.e., removing the ascending aorta to better visualize the LPA stent) or as individual structures (C, D). The ability to see the relationship between stent vessels is greatly enhanced with this technique.

more precise way to evaluate the results of various interventions.

Currently available software programs which allow for segmentation (Figure 9), vessel drive through and oblique peel-away imaging will increase our level of understanding of complex cardiac and vascular anatomy beyond what is possible with 2 dimensional angiography. With minor modifications to acquisition protocols, radiation exposure can be brought down to acceptable levels (approximately equal to a 2D acquisition using 15 fps bi-plane); and the dose of contrast media is comparable to standard 2 injections. Finally, it is our belief that as this technology evolves and gets increasingly integrated into the congenital cardiac catheterization laboratory (e.g. the ability to use 3D for roadmaps, 3D fluoroscopy, etc), the time will come when a single-plane system with the ability to perform high quality 3DRA may be preferable to a bi-plane system for the imaging of most congenital heart lesions.

References

1. Chung KJ, Simpson IA, Newman R, Sahn DJ, Sherman FS, Hesselink JR. Cine magnetic resonance imaging for evaluation of congenital heart disease: role in pediatric cardiology compared with echocardiography and angiography. *J Pediatr*. 1988 Dec;113(6):1028-35.
2. Gutierrez FR, Siegel MJ, Fallah JH, Poustchi-Amin M. Magnetic resonance imaging of cyanotic and noncyanotic congenital heart disease. *Magn Reson Imaging Clin N Am*. 2002 May;10(2):209-35. Review.
3. Samyn MM. A review of the complementary information available with cardiac magnetic resonance imaging and multi-slice computed tomography (CT) during the study of congenital heart disease. *Int J Cardiovasc Imaging*. 2004 Dec;20(6):569-78.
4. Kapins CEB, Coutinho RB, Barbosa FB, Silva, CMC, Lima, VC, Carvalho AC. Use of Rotational 3D (3D-RA) in Congenital Heart Disease Patients: Experience with 53 cases. *Rev Bras Cardiol Invasiva*. 2010;18(2):199-203.
5. Glatz AC, Zhu X, Gillespie MJ, Hanna BD, Rome JJ. Use of angiographic CT imaging in the cardiac catheterization laboratory for congenital heart disease. *JACC Cardiovasc Imaging*. 2010 Nov;3(11):1149-57.
6. Heran NS, Song JK, Namba K, Smith W, Niimi Y, Berenstein A. The

- utility of DynaCT in neuroendovascular procedures. JNR Am J Neuroradiol. 2006 Feb;27(2):330-2.
7. van Rooij WJ, Sprengers ME, de Gast AN, Peluso JP, Sluzewski M. 3D rotational angiography: the new gold standard in the detection of additional intracranial aneurysms. Am J Neuroradiol. 2008 May;29(5):976-9.
 8. Kim HC, Chung JW, Park JH, An S, Son KR, Seong NJ, Jae HJ. Transcatheter arterial chemoembolization for hepatocellular carcinoma: prospective assessment of the right inferior phrenic artery with C-arm CT. J Vasc Interv Radiol. 2009 Jul;20(7):888-95. Epub 2009 May 28.

CCT



*Evan M. Zahn, MD
Director, Cardiology
Head, Cardiac Catheterization
Laboratory
Miami Children's Hospital
3100 SW 62nd Ave.
Miami, FL 33155 USA*

Phone: 786.624.4285

Evan.Zahn@mch.com

Editor's Note: Congenital Cardiology Today is hosting videos provided by the author of the 3D rotational angiography - Figures 2, 3, 4, 6, 7, and 9, and referenced Video 1 in this article. Go to www.CHDVideo.com/3D and select the videos you wish to view.

Conversion of the video files for the web is compliments of Digisonics (www.Digisonics.com).



Pediatric Cardiologist Wilmington, NC

The Division of Pediatric Cardiology at the University of North Carolina at Chapel Hill is recruiting for an open-rank clinical faculty position. The successful candidate will live and work primarily in Wilmington, NC, at the Division's established community-based practice and will provide consultative and echocardiographic support to our regional partner, the Betty H. Cameron Women's and Children's Hospital at the New Hanover Regional Medical Center. Opportunities for collaboration, mentorship, CME, and cross-coverage will be available through close professional association with faculty colleagues at the North Carolina Children's Heart Center in Chapel Hill. Candidates must be Board-Certified or Board-Eligible in Pediatric Cardiology. UNC is an Equal Opportunity/ADA Employer.

For consideration apply online at <http://jobs.unc.edu/2501166> and attach CV with cover letter to:

Dr. John Cotton
Division of Pediatric Cardiology
NC Children's Heart Center
7232
101 Manning Drive
Chapel Hill, NC, 27599

CONGENITAL CARDIOLOGY TODAY

© 2011 by Congenital Cardiology Today (ISSN 1554-7787-print; ISSN 1554-0499-online). Published monthly. All rights reserved.

Headquarters: 824 Elmcroft Blvd., Rockville, MD 20850 USA

Publishing Management:

Tony Carlson, Founder & Senior Editor - TCarlsonmd@gmail.com
Richard Koulbanis, Publisher & Editor-in-Chief - RichardK@CCT.bz
John W. Moore, MD, MPH, Medical Editor - JMoore@RCHSD.org

Editorial Board: Teiji Akagi, MD; Zohair Al Halees, MD; Mazeni Alwi, MD; Felix Berger, MD; Fadi Bitar, MD; Jacek Bialkowski, MD; Philipp Bonhoeffer, MD; Mario Carminati, MD; Anthony C. Chang, MD, MBA; John P. Cheatham, MD; Bharat Dalvi, MD, MBBS, DM; Horacio Faella, MD; Yun-Ching Fu, MD; Felipe Heusser, MD; Ziyad M. Hijazi, MD, MPH; Ralf Holzer, MD; Marshall Jacobs, MD; R. Krishna Kumar, MD, DM, MBBS; Gerald Ross Marx, MD; Tarek S. Momenah, MBBS, DCH; Toshio Nakanishi, MD, PhD; Carlos A. C. Pedra, MD; Daniel Penny, MD, PhD; James C. Perry, MD; P. Syamasundar Rao, MD; Shakeel A. Qureshi, MD; Andrew Redington, MD; Carlos E. Ruiz, MD, PhD; Girish S. Shirali, MD; Horst Sievert, MD; Hideshi Tomita, MD; Gil Wernovsky, MD; Zhuoming Xu, MD, PhD; William C. L. Yip, MD; Carlos Zabal, MD

FREE Subscription: Congenital Cardiology Today is available free to qualified professionals worldwide in pediatric and congenital cardiology. International editions available in electronic PDF file only. Send an email to Subs@CCT.bz. Include your name, title, organization, address, phone and email.

Statements or opinions expressed in Congenital Cardiology Today reflect the views of the authors and sponsors, and are not necessarily the views of Congenital Cardiology Today.



Our Mission: To provide financial, logistical and emotional support to families facing a complex Congenital Heart Defect (CHD) who choose to travel for a Fetal Cardiac Intervention and follow up care to treat this defect.

Phone: 952-484-6196

Trans-catheter Pulmonary Valve Implantation: A Decade of Disruptive Technology

By Louise Coats, MRCP, PhD and Philipp Bonhoeffer, MD

Introduction

Technological developments in medicine usually occur in an incremental manner with gradual and rational improvements made to existing therapies. Occasionally, an innovation is introduced that completely disrupts the status quo and transforms patient management.

The story of the Melody® valve (Medtronic, Inc., MN) represents a pivotal moment in the history of Congenital Cardiology, leading to a rethink on how we should manage the growing population of children and adults with repaired congenital heart disease. It details how feasibility, safety and efficacy of a new device can be successfully achieved alongside a necessary shift in conventional clinical wisdom. Further, it highlights the difficulties associated with introducing new therapies into the clinical arena and the crucial importance of a multi-disciplinary team approach. Trans-catheter pulmonary valve implantation is now carried out in more than 150 centers worldwide with over 2,500 patients treated.

History

The concept of placing an expandable valve in the circulation by a trans-catheter approach was first developed in the early 1950s, before the era of cardiopulmonary bypass. Charles Hufnagel implanted a prosthetic heart valve in the descending aorta of a patient in an attempt to relieve the effects of severe chronic aortic insufficiency.¹ At about the same time, development of the extracorporeal circulation was taking place and it was this success that ensured native valve replacement via a surgical approach, became the conventional treatment in subsequent decades.

With rapid progress in cardiac catheterisation during the nineteen-eighties and nineties, the notion of a percutaneously-delivered valve was revived and, in 2000, the first trans-catheter valve was implanted into the dysfunctional right ventricle-to-pulmonary artery conduit of a 12-year-old boy by one of the authors.² Subsequently, a programme of pulmonary valve implantation was carried out, first at the Necker Hospital and latterly at Great Ormond Street Hospital, that showed feasibility and early efficacy underpinning later industry-sponsored trials and regulatory submissions.^{3,4} The 100th patient was treated with the Melody® valve in September 2005 and CE Mark and Canadian regulatory approval was granted the following year. Implantation in the United States began in 2007 with the 1,000th patient treated in 2009 and FDA Approval under HDE was achieved in 2010, some ten years after the first pioneering case.

Indications for Trans-catheter Pulmonary Valve Implantation

Trans-catheter pulmonary valve implantation is now performed primarily to prolong the lifespan of right ventricle to pulmonary artery conduits, postponing and reducing the need for repeated open-heart surgery in children and adults with repaired congenital heart disease. It is intended for use as an adjunct to surgery in the management of pediatric and

adult patients with at least moderate regurgitation or a mean gradient ≥ 35 mmHg in a circumferential right ventricular outflow tract conduit (original diameter ≥ 16 mm) and a clinical indication (usually symptoms) for intervention. Typical conditions include repaired Tetralogy of Fallot, pulmonary atresia with ventricular septal defect, truncus arteriosus and arterial transposition with either a Rastelli or arterial switch repair. Early experience with Melody® quickly established the unsuitability of the device for patients with trans-annular patches although in selected cases implantation has been successful.^{3,5}

Contraindications to the Melody® trans-catheter valve include: unsuitable venous anatomy, unfavourable right ventricular outflow tract morphology including anomalous coronary arteries at risk of occlusion, severe right ventricular outflow obstruction not responsive to balloon dilatation, and clinical or biological signs of infection.

Adults with congenital heart disease are a rapidly growing population; many have had to undergo multiple open heart operations in childhood.⁶ Whilst surgical pulmonary valve replacement is relatively safe with low morbidity and mortality, the chance to delay repeated surgery and thereby reduce the total number of re-operations an individual may require during a lifetime is attractive both to patient, cardiologist and surgeon. Additionally, trans-catheter pulmonary valve implantation offers an option for intervention in patients who would conventionally be considered too high risk for surgery such as those with thoracic wall abnormalities, pulmonary hypertension or cardiogenic shock.⁷ The optimal timing for pulmonary valve replacement has been greatly debated; limited longevity of available bio-prosthetic valves has necessitated acceptance of a degree of valve dysfunction in order to avoid too many surgical procedures. Trans-catheter valve implantation has provided a new opportunity to study the potential for recovery of the chronically volume and pressure overloaded right ventricle. Results tend to support the growing inclination for earlier intervention in asymptomatic patients with significant hemodynamic lesions; more work is needed, however, before this is fully clarified.^{8,9,10} Nevertheless, a 'lifetime management' strategy has now emerged where trans-catheter and surgical valve replacement are seen as complementary rather than competing therapies. Individual case discussion in a multi-disciplinary setting which includes cardiologists and surgeons is therefore strongly advocated prior to proceeding with intervention.

Assessment prior to trans-catheter pulmonary valve implantation should include cardiopulmonary exercise testing ($\text{VO}_2\text{max} < 65\%$ considered significant), trans-thoracic echocardiography (to assess right ventricular outflow tract dysfunction and right heart dilatation/dysfunction) and where at all possible cardiac magnetic resonance to further qualify cardiac function, define the suitability of the implantation site in terms of dimensions and outline the coronary anatomy.

The Device and Delivery System

The Melody® valve is a bovine jugular venous valve sutured inside a platinum iridium frame (Figure 1). It is 28mm in length, with a crimped diameter of 6mm that can be extended up to 22mm on re-expansion.



ACHA - 6757 Greene Street, Suite 335 - Philadelphia, PA, 19119
P: (888) 921-ACHA - F: (215) 849-1261

A nonprofit organization which seeks to improve the quality of life and extend the lives of congenital heart defect survivors.

<http://achaheart.org>

The suturing is clear for all points except at the device outflow line, which is blue. This aids correct orientation of the device on the delivery system and thus successful deployment. The Balloon-In-Balloon delivery system (Ensemble®, available with balloon diameters of 18, 20 or 22 mm) has a 22Fr outer diameter and an overall length of 100cm; a retractable sheath covers the Melody® valve once it is frontloaded and crimped over the balloon (Figure 1).

Since the first device was deployed in a clinical setting, the structural integrity of both valve and delivery system has been scrutinised. Various modifications have subsequently occurred, notably to deal with the unforeseen 'Hammock Effect' and to improve the flexibility of the delivery system. A new appreciation of the heterogeneity of surgically-repaired right-ventricular outflow tract morphology has highlighted the limitations of pre-clinical bench testing and the lack of relevant animal models in percutaneous device design.^{11,12,13}

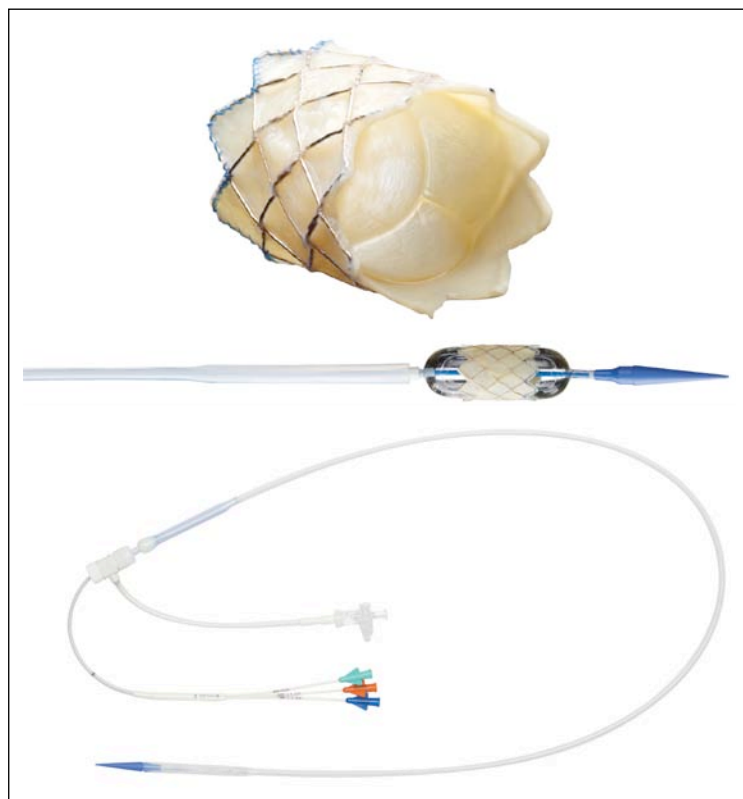


Figure 1. The Melody® trans-catheter valve and Ensemble® delivery system.

Other Trans-catheter Pulmonary Valves

In the wake of Melody®, a variety of other devices for implantation in the pulmonary position, most notably the Edwards SAPIEN™ valve (Edwards Lifesciences LLC, Irvine, CA), have emerged. This bovine pericardial valve mounted inside a balloon-expandable stainless steel stent has the advantage of being available in diameters of 23 and 26mm, with 20mm and 29mm prototypes also under development. Early feasibility data is encouraging with the outcome of the COMPASSION safety and efficacy trial awaited.¹⁴ One further benefit of this device is a lower frequency of stent fractures in the stainless steel frame.

In the pre-clinical arena, much interest surrounds the development of valved stents with infinite durability, comparable performance and no requirement for anticoagulation. Experimental trans-catheter implantation of such tissue-engineered valves in the pulmonary position has recently been reported.¹⁵

The Procedure

Melody® implantation is typically performed from a femoral approach under general anaesthesia with the guidance of biplane angiography (Figure 2). Standard right heart hemodynamics are measured at the outset and angiographic assessment of the pulmonary regurgitation is carried out. If there is any concern regarding dimensions of the proposed implant site from prior magnetic resonance imaging or if this investigation has not been carried out, balloon sizing of the outflow tract is undertaken. Similarly, if the existing conduit is not circumferential or a patch is present further information concerning the distensibility of the site should be sought. Aortic root angiography should be performed in all cases to define the relationship between the coronaries and the right ventricular outflow tract. If the coronary arteries appear at risk of potential compression, selective coronary angiography with simultaneous high-pressure balloon inflation at the implantation site should be performed and a decision to proceed made on the basis of this evaluation.

The Melody® device is hand-crimped and front loaded onto the delivery system, where a sheath is advanced over it to provide protection prior to arrival at the implantation site. Training for implanting physicians is provided by industry sponsored peer-to-peer training before a centre may begin performing this procedure. Once in situ, the sheath is retracted and positioning confirmed with contrast prior to deployment of the valve. Detailed procedural technique has been described elsewhere.¹⁶

Pre-dilatation of the implantation site with a high-pressure balloon can facilitate passage of the delivery system and positioning of the device. The risk of conduit rupture whilst rare, must, however, be considered if undertaking this manoeuvre prior to placing the Melody® valve, which can act like a covered stent. Increasingly, experience with Melody® supports pre-stenting the implantation site with a bare metal stent. This guides device delivery, provides anchorage, improves early hemodynamic results, particularly in those with moderate to severe obstruction and reduces the risk of future stent fractures (Figure 3).^{12,17} In the presence of a residual gradient, multiple post-dilatations of the device can be performed; valve integrity does not appear to be affected.

Although not mandatory, Melody® implantation is best undertaken in centers with availability of autotransfusion kits, ECMO and experienced congenital heart disease surgeons, so that rare, but serious complications can be adequately managed.

Clinical Results

The Paris/London Series

The index clinical series of Melody® implantation was undertaken on an individual patient basis, according to traditional surgical criteria, with humanitarian exemption approval from the relevant regulatory body. As such, the population was relatively heterogeneous and, with the clinical procedure in its infancy, many referrals were for patients in whom surgery was high risk or not possible. Implantation was attempted in a few patients with native outflow tracts or transannular patches, but these were exceptional. Concomitant procedures such as ventricular septal defect closure, paravalvular leak closure and coarctation stenting were also performed.

Despite these limitations it was evident from an early stage that deployment of the device was feasible in the vast majority. Valve competency and durability during early follow-up were excellent and reduction in outflow tract gradient and right ventricular pressure achievable.⁴ Furthermore, valve implantation was associated with symptomatic and functional improvement, as well as better cardiac output as assessed by magnetic resonance imaging.¹⁸ Nevertheless a clear learning curve, particularly with regards to procedural complications, was evident with many of the recommended procedural maneuvers and selection criteria, outlined above, developing as a direct result of this experience with individual cases.

The United States Experience

The United States Melody® valve trial, provided safety and short-term efficacy data to support the Humanitarian Device Exemption Application to the FDA. In total, 150 patients received a Melody® implant in this trial between January 2007 and January 2010, and will be followed for five years. A recent publication reported results of trans-catheter pulmonary valve implantation at five centers in the United States between January 2007 and August 2009.¹⁹ Of the total 150 patients in this series, one-year follow-up is now available on two-thirds of the patient group.²⁰ Inclusion and exclusion criteria were fundamentally those described above. Melody® implantation was not attempted in those under the age of 5 years or less than 30kg in weight.

The median age of those treated was 22 years (range 7-53) with the predominant primary diagnosis being Tetralogy of Fallot (48%) followed by the Ross operation (21%). Most had dysfunctional homografts (76%) with a mixture of bioprosthetic and synthetic conduits accounting for the remainder. Forty-four percent of patients had undergone more than one surgical revision of their right ventricular to pulmonary artery conduit previously, and 22% had had previous bare metal stenting. In total, 166 patients were catheterized, with only 150 proceeding to valve implantation. The procedure was abandoned in some due to unsuitable right ventricular outflow tracts (7), risk of coronary artery compression (6), and issues related to branch pulmonary artery stenosis and pulmonary artery stenting. Of the 150 implants, one patient required explant within 24 hours due to homograft rupture; there have been two late deaths, one further explant and two patients lost to follow-up. At one year, freedom from reoperation was 98.7%, freedom from re-intervention was 96.9%, mean right ventricular outflow tract gradient was 21.2 mmHg and 93.3% had no or trace pulmonary regurgitation.

The German Experience

The most recent series of trans-catheter pulmonary valve implantation is from two centers carrying out the intervention in Germany.²¹ One hundred-

two patients, with a similar demographic profile to the United States series, were treated. Importantly, in this series pre-stenting of the outflow tract was carried out in 95%. Excellent haemodynamic results were seen, at a median follow-up of just under a year, with one procedural death due to coronary artery compression and one late explant for endocarditis reported. The conclusion, is therefore, that whilst technically challenging, trans-catheter pulmonary valve implantation can be performed by experienced interventionalists with similar results to those achieved in the index group

Complications and Their Avoidance

Combined data from the Paris/London series (n=242), the US Melody® valve trial (n=124) and the German Experience (n=102) permits a reasonable estimation as to the expected frequency of various complications.^{19,21}

Procedure-Related Adverse Events

Major procedural complications have occurred in just under 6% of patients and have included: homograft rupture (8), device dislodgement (2); hypercarbia necessitating ventilation (1); coronary artery compression (2); coronary artery dissection (1); major arrhythmia (1); femoral vein thrombosis (1); obstruction or damage to branch pulmonary artery (n=5) and tricuspid valve entrapment (n=6). In total, bailout surgery has been required in 7 patients with no associated mortality.

Accurate measurement of the implantation site, assessment of outflow tract distensibility and a stepwise approach to the assessment of coronary anatomy are now a standard component of Melody® implantation (Figure 2). Damage to distal pulmonary artery branches can be minimized by ensuring stable guidewire positioning at all times and avoidance of damage to the tricuspid valve can be achieved by use of a balloon flotation catheter when crossing for the first time. Homograft rupture remains the most difficult complication to predict, and therefore, avoid. Aggressive post-dilatation after deployment of the valve may reduce the risk of severe bleeding. If bleeding occurs, auto-transfusion should be

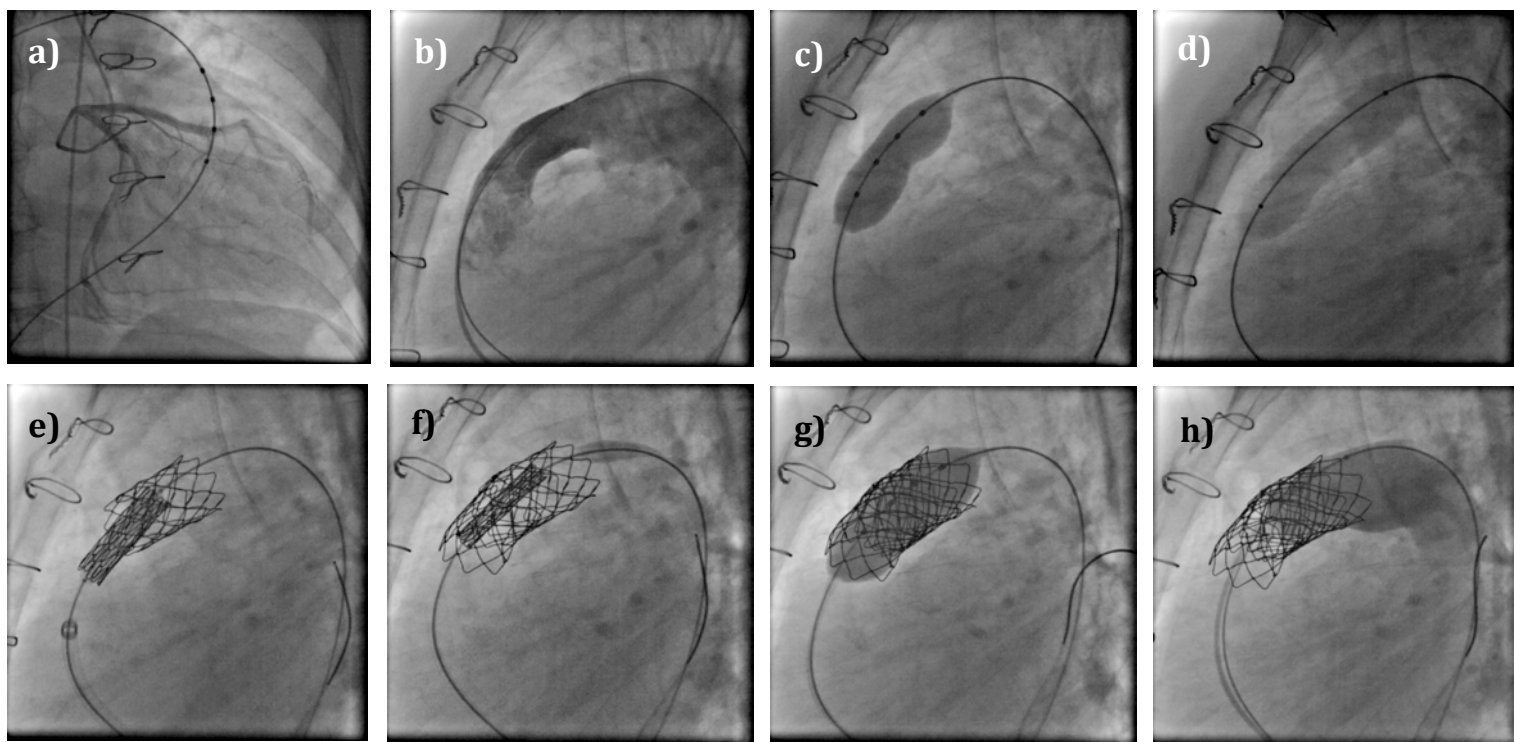


Figure 2. Melody® Implantation: a) Left anterior oblique view of the left coronary artery with a PTS sizing-balloon catheter placed in the right ventricular outflow tract. Lateral views demonstrating b) angiography of the stenosed mildly regurgitant conduit with the multi-track catheter, c) assessment of conduit dimensions with sizing balloon, d) pre-dilatation of conduit with an Atlas PTA balloon catheter, e) pre-stenting of the conduit with two CP stents, f) positioning of Melody® inside the stented conduit, g) outer balloon inflation leading to Melody® deployment and h) a competent valve with relief of conduit stenosis.

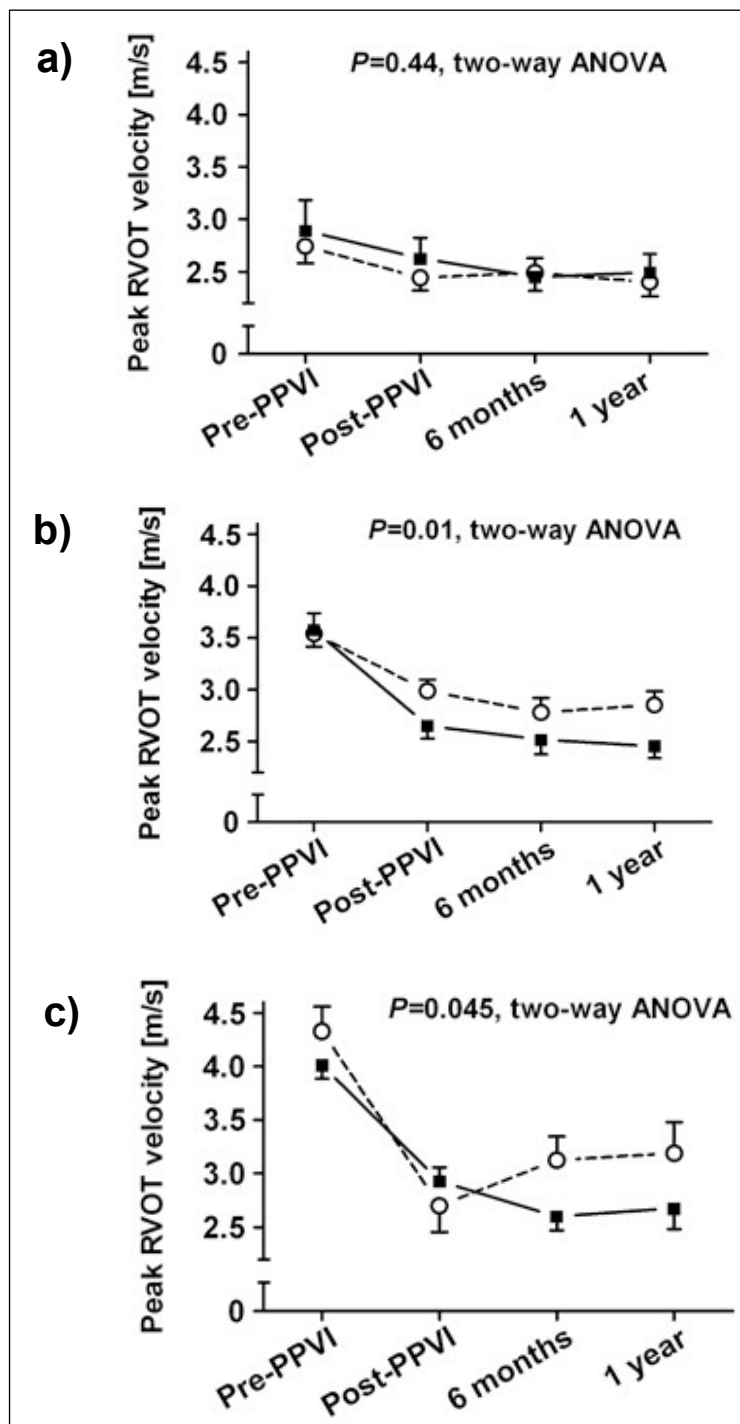


Figure 3. The effect of pre-stenting with a bare metal stent on trans-catheter pulmonary valve implantation in patients with a) mild, b) moderate and c) severe right ventricular outflow tract obstruction (Adapted from Nordmeyer J et al. *Heart* 2011;97:118-123).

initiated as soon as possible to re-establish a sufficient circulation for further intervention or 'watchful waiting.' Acute thoracotomy is not advised, since decompression of the chest may exacerbate bleeding and lead to later difficulty locating the source.

Device Related Adverse Events

- **The 'Hammock Effect'** describes an in-stent stenosis resulting from blood passing between the wall of the vein and the recipient outflow tract. This problem predominantly affected the initial cohort of patients

and led to a revision of the suturing within the device. In theory it may still occur in the context of stent fractures or suture rupture where adherence of the venous wall to the stent becomes disrupted.

- **Stent Fractures** are a potential complication of all cardiovascular stent applications. In the United States series, freedom from Melody® stent fracture at one year was 81.5% with freedom from device dysfunction 93.5%. Implantation into a "native" RVOT, absence of RVOT calcification and qualitative recoil of the valve just after implantation are predictive of stent fracture.¹² Pre-stenting with a bare metal stent reduces the risk of stent fracture (Figure 3).¹⁷ Minor fractures with no loss of stent integrity can be managed conservatively; however, major fractures that lead to restenosis should be considered for repeat Melody® implantation or surgery. Embolization, which to date has only been seen in one case, inevitably necessitates surgery. Serial radiographic and echocardiographic follow-up is essential to detect and monitor stent fractures and facilitate timely re-intervention. Fluoroscopy is a useful adjunct to assess device stability.

Repeat Melody® implantation (and in some cases a third device) has been performed for the 'Hammock effect,' stent fracture and residual stenosis. The procedure is feasible and has excellent and sustained haemodynamic results.²² In the future, it is to be expected that repeat Melody® procedures will be performed for late valvar degeneration in the index device.

- **Haemolysis** is rare having occurred in only one reported case with unrelieved obstruction in a small conduit; patient subsequently underwent surgical explantation of the device.³ Routine screening is not performed.
- **Endocarditis** has been documented on both the venous wall and the valve itself. It may or may not result in device dysfunction and surgical or medical management strategies should be employed accordingly. Various organisms have been reported.
- **Thromboembolism** has not been reported. In the United States clinical study, no new pulmonary emboli were identified among 63 patients who underwent six-month follow-up computerised tomography pulmonary angiograms or in 32 subjects who underwent scans at one year. Lifelong Aspirin is recommended.

Late Follow-up

Whilst ten-year follow-up is now available in the Paris/London cohort, actuarial survival and freedom from re-intervention in this group is strongly influenced by the impact of the "learning curve," and thus should be interpreted cautiously.⁴ Nevertheless, the availability of this data in itself supports the premise that if patients are selected correctly and an optimal procedure is performed, a long-lasting trans-catheter result is achievable.

Wider Implications and Future Developments

Implantation of Melody® has been combined very successfully with other trans-catheter procedures to treat structural heart disease. In addition, the device has also been used to treat other dysfunctional conduits, such as in the Bjork modification of the Fontan palliation.²³ Application in the dilated right ventricular outflow tract is beginning to reach clinical practice.¹³ Finally, the success of this clinical program has led the way for many other trans-catheter valve interventions, most notably aortic valve replacement.

Conclusions

Trans-catheter pulmonary valve implantation is rapidly becoming part of the standard armamentarium for treatment of dysfunctional right-ventricular-to-pulmonary-artery conduits in the growing population of patients with repaired congenital heart disease. The challenge, over the coming years, will be to provide a percutaneous option to all those with a clinical indication irrespective of the nature of their outflow tract.

Acknowledgements

We are grateful to Dr. Ingo Daehnert, University of Leipzig, Heart Center for the angiographic images.

References

1. Hufnagel CA, Harvey WP, Rabil P, McDermott TF. Surgical correction of aortic valve insufficiency. *Surgery*. 1954; 35: 673–80.
2. Bonhoeffer P, Boudjemline Y, Saliba Z, Merckx J, Aggoun Y, Bonnet D, Acar P, Le Bidois J, Sidi D, Kachaner J. Percutaneous replacement of pulmonary valve in a right-ventricle to pulmonary-artery prosthetic conduit with valve dysfunction. *Lancet*. 2000;356 (9239):1403-5.
3. Khambadkone S, Coats L, Taylor A, Boudjemline Y, Derrick G, Tsang V, Cooper J, Muthurangu V, Hegde SR, Razavi RS, Pellerin D, Deanfield J, Bonhoeffer P. Percutaneous pulmonary valve implantation in humans: results in 59 consecutive patients. *Circulation*. 2005; 112: 1189-97.
4. Lurz P, Coats L, Khambadkone S, Nordmeyer J, Boudjemline Y, Schievano S, Muthurangu V, Lee TY, Parenzan G, Derrick G, Cullen S, Walker F, Tsang V, Deanfield J, Taylor AM, Bonhoeffer P. Percutaneous pulmonary valve implantation: impact of evolving technology and learning curve on clinical outcome. *Circulation*. 2008;117(15):1964-1972.
5. Momenah TS, El Oakley R, Al Najashi K, Khoshhal S, Al Qethamy H, Bonhoeffer P. Extended application of percutaneous pulmonary valve implantation. *J Am Coll Cardiol*. 2009;53(20):1859-63.
6. Marelli AJ, Mackie AS, Ionescu-Ittu R, Rahme E, Pilote L. Congenital heart disease in the general population: changing prevalence and age distribution. *Circulation*. 2007;115(2):163-72.
7. Lurz P, Nordmeyer J, Coats L, Taylor AM, Bonhoeffer P, Schulze-Neick I. Immediate clinical and haemodynamic benefits of restoration of pulmonary valvar competence in patients with pulmonary hypertension. *Heart*. 2009;95(8):646-50.
8. Coats L, Khambadkone S, Derrick G, Sridharan S, Schievano S, Mist B, Jones R, Deanfield JE, Pellerin D, Bonhoeffer P, Taylor AM. Physiological and clinical consequences of relief of right ventricular outflow tract obstruction late after repair of congenital heart defects. *Circulation*. 2006;113:2037-2044.
9. Coats L, Khambadkone S, Derrick G, Hughes M, Jones R, Mist B, Pellerin D, Marek J, Deanfield JE, Bonhoeffer P, Taylor AM. Physiological consequences of percutaneous pulmonary valve implantation: the different behaviour of volume- and pressure-overloaded ventricles. *Eur Heart J*. 2007;28(15):1886-93.
10. Lurz P, Nordmeyer J, Giardini A, Khambadkone S, Muthurangu V, Schievano S, Thambo JB, Walker F, Cullen S, Taylor AM, Bonhoeffer P. Early Versus Late Functional Outcome after Successful Percutaneous Pulmonary Valve Implantation – Are the Acute Effects of Altered Right Ventricular Loading All We Can Expect? *J Am Coll Cardiol*. 2011;57(6):724-31.
11. Schievano S, Coats L, Migliavacca F, Norman W, Frigiola A, Deanfield J, Bonhoeffer P, Taylor AM. Variations in right ventricular outflow tract morphology following repair of congenital heart disease: implications for percutaneous pulmonary valve implantation. *J Cardiovasc Magn Reson* 2007; 9(4): 687-695.
12. Nordmeyer J, Khambadkone S, Coats L, Schievano S, Lurz P, Parenzan G, Taylor AM, Lock JE, Bonhoeffer P. Risk stratification, systematic classification, and anticipatory management strategies for stent fracture after percutaneous pulmonary valve implantation. *Circulation* 2007; 115(11): 1392-1397.
13. Schievano S, Taylor AM, Capelli C, Coats L, Walker F, Lurz P, Nordmeyer J, Wright S, Khambadkone S, Tsang V, Carminati M, Bonhoeffer P. First-in-man implantation of a novel percutaneous



Opportunities available in all facets of Pediatric Cardiology

HCA, the largest healthcare company in the US, owns and/or manages over 160 hospitals in 20 states. We have opportunities available for Pediatric Cardiologists, Cardiovascular Surgeons and specialties associated with Pediatric Cardiology in most of our markets.

Whether you are looking for your first position or somewhere to complete your career, chances are we have something that will fit your needs. Call or email today for more information.



Kathy Kyer

Pediatric Subspecialty Recruitment Manager

Kathleen.Kyer@HCAHealthcare.com

937.235.5890



Dedicated to improving diagnosis, treatment and quality of life for children affected by cardiomyopathy

Children's Cardiomyopathy Foundation

toll free: 866.808.CURE | www.childrenscardiomyopathy.org

- valve: a new approach to medical device development. *EuroIntervention*. 2010;5(6): 745-50.
14. Boone RH, Webb JG, Horlick E, Benson L, Cao QL, Nadeem N, Kiess M, Hijazi ZM. Transcatheter pulmonary valve implantation using the Edwards SAPIEN transcatheter heart valve. *Catheter Cardiovasc Interv* 2010;75(2):286-94.
 15. [Metzner A, Stock UA, Iino K, Fischer G, Huemme T, Boldt J, Braesen JH, Bein B, Renner J, Cremer J, Lutter G. Percutaneous pulmonary valve replacement: autologous tissue-engineered valved stents. *Cardiovasc Res*. 2010;88(3): 453-61.
 16. Coats L, Bonhoeffer P. Pulmonary and Tricuspid Valve Interventions. In: *Interventional Cardiology* (6th Edition). Ed: Topol E. 2011 In Press.
 17. [17] Nordmeyer J, Lurz P, Khambadkone S, Schievano S, Jones A, McElhinney DB, Taylor AM, Bonhoeffer P. Pre-stenting with a bare metal stent before percutaneous pulmonary valve implantation: acute and 1-year outcomes. *Heart*. 2011;97(2):118-23.
 18. Khambadkone S, Coats L, Taylor A, Boudjemline Y, Derrick G, Tsang V, Cooper J, Muthurangu V, Hegde SR, Razavi RS, Pellerin D, Deanfield J, Bonhoeffer P. Percutaneous pulmonary valve implantation in humans: results in 59 consecutive patients. *Circulation*. 2005;112 (8):1189-97.
 19. McElhinney DB, Hellenbrand WE, Zahn EM, Jones TK, Cheatham JP, Lock JE, Vincent JA. Short- and medium-term outcomes after transcatheter pulmonary valve placement in the expanded multicenter US melody valve trial. *Circulation*. 2010;122(5):507-16.
 20. Personal Communication.
 21. Eicken A, Ewert P, Hager A, Peters B, Fratz S, Kuehne T, Busch R, Hess J, Berger F. Percutaneous pulmonary valve implantation: two-centre experience with more than 100 patients. *Eur Heart J*. 2011 Jan 27.
 22. Nordmeyer J, Coats L, Lurz P, Lee TY, Derrick G, Rees P, Cullen S, Taylor AM, Khambadkone S, Bonhoeffer P. Percutaneous pulmonary valve-in-valve implantation: a successful treatment concept for early device failure. *Eur Heart J*. 2008;29(6):810-5.
 23. Butcher CJ, Plymen CM, Walker F. A novel and unique treatment of right ventricular inflow obstruction in a patient with a Bjork modification of the Fontan palliation before pregnancy. *Cardiol Young*. 2010;20(3): 337-8.

CCT

Corresponding Author

Louise Coats, MRCP, PhD
Academic Clinical Lecturer in Adult
Congenital Heart Disease
Cardiology Department
Freeman Hospital
Freeman Road
High Heaton
Newcastle upon Tyne, UK
Tel: +44 (0)191 2336161
lecoats@doctors.org.uk

Philipp Bonhoeffer, MD, FSCAI
Recipient of the ETHICA Award
Grand Scientific Prize of
Lefoulon - Delalande de
L'Institute de France
Interventional Cardiologist
London, UK
bonhop1705@googlemail.com

Editor's Note: Congenital Cardiology Today is hosting videos provided by the authors of the Melody® implantation. Go to www.CHDVideo.com/Valve.

Conversion of files for the web is compliments of Digisonics (www.Digisonics.com).



Pediatric Cardiology Research Fellowships

The Labatt Family Heart Centre, at The Hospital for Sick Children in Toronto, is pleased to invite applications for four newly endowed Research Fellowships in Cardiovascular Science.

The fellowships will provide salary support for 1-3 year programs of clinical, translational, or basic research. Applicants should have completed their core clinical training in a relevant sub-specialty (paediatric cardiology, paediatric cardiac surgery, paediatric cardiac critical care, adult congenital heart disease, etc), and ideally will have some preexisting research experience. These posts are open to MD and non-MD trainees, and registration for postgraduate degrees will be possible for appropriately trained individuals. Small amounts of start-up funding may be available from the Heart Centre, but projects will be expected to garner additional peer-reviewed funding where necessary.

Applicants are encouraged to communicate with potential research supervisors within the Heart Centre (<http://www.sickkids.ca/Centres/heart-centre/Our-members/index.html>), prior to or coincident with their application. Alternatively, de-novo applications can be made, but should include a brief research plan with clearly defined aims and objectives so that they can be directed to potential supervisors.

Please include a full curriculum vitae and research plan with all applications. The closing date for applications is August 31, 2011. Remuneration - commensurate with status, to be negotiated.

All qualified candidates are encouraged to apply; however Canadian citizens and permanent residents will be given priority. The Hospital for Sick Children hires on the basis of merit and is committed to equity in employment.

Inquiries and applications should be made to:
Bernadette Stanton-Meijer, MA
Manager, Clinical Research
Labatt Family Heart Centre
Hospital for Sick Children
Toronto, ON
CANADA
Tel (416) 813-7798; Fax (416) 813-8528
bernadette.stanton-meijer@sickkids.ca

Medical News, Products & Information

Early Clinical Experience With EDWARDS INTUITY™ Valve System Demonstrates Promise of New Technology

Edwards Lifesciences Corporation (NYSE: EW), a global leader in the science of heart valves and hemodynamic monitoring, announced that interim data from a multi-center European prospective study of the investigational EDWARDS INTUITY™ Valve System showed promising results for patients undergoing surgical aortic valve replacement (AVR). The results generally reflect those found in traditional open-heart surgery, but demonstrate reduced cross-clamp and bypass times as compared to those of The Society of Thoracic Surgeons' (STS) National Database, according to a presentation during the Emerging Technologies and Techniques Forum at the May *American Association for Thoracic Surgery's 91st Annual Meeting* in Philadelphia.

These data are from the TRITON clinical study, evaluating the feasibility, safety and performance of the EDWARDS INTUITY™ Valve System, which is based on Edwards' market-leading pericardial tissue valve design. These data are intended to support the company's CE Mark application for European commercial approval.

In this first clinical experience, surgeons at five centers achieved a technical success rate (the valve was implanted as intended) of 94 percent. A total of 90 patients with severe, symptomatic aortic stenosis or stenosis-insufficiency received the EDWARDS INTUITY™ Valve System in an isolated AVR or AVR with a concomitant procedure. For the isolated AVR procedures, mean aortic cross-clamp times were reduced by 43%, and mean bypass times by 41%, compared to the STS National Database. Comparable data for concomitant procedures are not available. Published studies indicate that a shorter duration of aortic cross-clamping is associated with a reduction in mortality and morbidity after AVR.

"We are encouraged by these interim results and the promise of this new technology. Implantation using the EDWARDS INTUITY™ Valve System may enable smaller incisions for isolated valve cases, which we believe could result in clinically significant benefits for patients," said Prof. Axel Haverich, MD, Head of the Department of Cardiothoracic Transplantation and Vascular Surgery at Hannover Medical School in Germany and lead investigator of the study. "At three months' follow-up, these patients demonstrated sustained clinical status improvement and the valve provided excellent hemodynamic performance."

The EDWARDS INTUITY™ Valve System leverages the proven design of Edwards' pericardial valve platform, which features aortic valves with nearly 30 years of clinical experience, and includes an innovative balloon-expandable frame. The valve system enables rapid valve deployment and is designed to reduce procedural complexity. It is an investigational device limited by law to investigational use only, and is not yet available commercially in any country.

Edwards Lifesciences is the global leader in the science of heart valves and hemodynamic monitoring. Driven by a passion to help patients, the company partners with clinicians to develop innovative technologies in the areas of structural heart disease and critical care monitoring that enable them to save and enhance lives. Additional company information can be found at www.edwards.com.

This news release includes forward-looking statements within the meaning of Section 27A of the Securities Act of 1933 and Section 21E of the Securities Exchange Act of 1934. These forward-looking statements include, but are not limited to, Prof. Haverich's statements and statements regarding potential clinical results and benefits of the EDWARDS INTUITY™ Valve System, the potential for reduced mortality and morbidity, and the potential timing and results of regulatory submissions and approvals for the valve.

PEDIATRIC CARDIOLOGY

Geisinger Health System is seeking a BC/BE Pediatric Cardiologist to join its collaborative team of 4 Pediatric Cardiologists and 1 Pediatric Cardiovascular Surgeon at Geisinger's Janet Weis Children's Hospital, an exceptional tertiary referral center, located on the campus of Geisinger Medical Center in Danville, PA.

This position involves working within a large multidisciplinary group, providing inpatient care in our children's hospital and outpatient care locally and at outreach locations. It provides opportunities to practice state-of-the-art medicine, teach students and residents, benefit from a fully digital echo system, and work with others providing comprehensive advanced cardiac care. Research opportunities are available.

Janet Weis Children's Hospital is a dedicated children's hospital within a hospital, with an ICAEL-certified Echocardiography laboratory, an

advanced cardiac imaging center, an Interventional Cardiac Catheterization program, ECMO, a 12-bed PICU and a 38-bed Level III NICU, with all sub-specialties well represented.

Geisinger Health System serves nearly 3 million people in Northeastern and Central Pennsylvania and is nationally recognized for innovative practices and quality care. A mature electronic health record connects a comprehensive network of 2 hospitals, 38 community practice sites and more than 700 Geisinger primary and specialty care physicians.

For more information or to apply for this position, please contact:
Robert Mangano, MD, c/o
Kathy Kardisco, Department
of Professional Staffing,
at 1-800-845-7112,
email:
kkardisco@geisinger.edu



Learn more at Join-Geisinger.org/150/PedCard



GEISINGER
Janet Weis Children's Hospital®

One of America's Top Hospitals. Make Cleveland Clinic Your Choice.



Director of Non-Invasive Imaging

Cleveland Clinic is seeking a Director of Non-Invasive Imaging for the Pediatric Cardiology Department within the Institute of Pediatrics and the Cleveland Clinic Children's Hospital.

The successful candidate would join our staff of 4 Pediatric Echocardiographers and one advanced non-invasive imaging fellow in training in a busy clinical and academic practice. Our main campus facility is expanding to 4 echo labs with an additional dedicated lab for sedated echos. We currently are involved in performing over 6,500 echocardiograms and over 100 cardiac MRI's annually. The Echo lab is ICAEL accredited. We have an active fellowship program with funding available for a 4th year non-invasive fellowship.

A faculty appointment at a rank commensurate with experience will be with the Cleveland Clinic Lerner College of Medicine of Case Western Reserve University. The Department deservedly enjoys a national reputation for excellence in clinical care and patient outcomes. With strong leadership, the program has tremendous growth potential. Desirable interests should include clinical and/or basic science research as well as an interest in adult congenital heart disease.

Cleveland Clinic Children's Health System has approximately 400 beds and three neonatal intensive care units staffed by 250 physicians and over 400 nursing professionals. The Children's Hospital on the main campus is a 125-bed hospital within a hospital including a PICU and NICU that are staffed 24-hours a day with senior staff. The Pediatric Intensive Care Unit (PICU) is a 25 bed multi-disciplinary unit. The PICU admits over 1,000 patients per year and provides state-of-the-art care including ECMO, cardiac devices, CRRT, and organ transplantation.

Gerard Boyle, MD
Department Chairman, Pediatric Cardiology
Medical Director, Pediatric Heart Failure & Transplant Program
 boyleg@ccf.org

Interested candidates should submit an application online by going to www.clevelandclinic.jobs

Cleveland Clinic is an equal opportunity employer and is committed to increasing the diversity of its faculty. It welcomes nominations of and applications from women and members of minority groups, as well as others who would bring additional dimensions to its research, teaching, and clinical missions. Cleveland Clinic is a smoke/drug free work environment.



Visit us at PICS-ACIS
Booth #10



Never Miss a Beat!

Web-based Image Interpretation and Reporting

- Pediatric and fetal specific reports
- Trend plots with z-scores
- Configurable pediatric normal range tables
- Fully functional web-based access for image review & reporting
- HemoLink interface to hemodynamics systems
- DigiDraw - edit customizable congenital diagrams
- Auto-report dissemination
- HIPAA compliant with e-signature



#1 in Cardiology*

*Digisonics DigiView, 2008, 2009 & 2010
 Top 20 Best in KLAS Awards: Software & Professional Services, www.KLASresearch.com



Opt-in Email marketing and e-Fulfillment Services
email marketing tools that deliver
 Phone: 800.707.7074
www.GlobalIntelliSystems.com



Pediatric Cardiologist

The Division of Pediatric Cardiology at the University Of Utah School Of Medicine is recruiting a pediatric cardiologist with a major interest in **Adult Congenital Heart Disease**. The candidate should have a strong clinical background in all areas of pediatric cardiology with expertise in caring for adults with congenital heart disease. The candidate will be joining a 24-member division of Pediatric Cardiology including one pediatric cardiologist currently running the Adult Congenital Heart Disease Program. The Division has a very active clinical program, currently seeing a large volume of adults with congenital heart disease. The Division also has a very active clinical research program and is one of the participating centers in the Pediatric Heart Disease Clinical Research Network funded by the NIH. There will be protected time for clinical research with mentoring available within the Division for clinical research studies. This faculty position will be involved in a very active academic teaching program.

The successful candidate will receive a faculty appointment at the University of Utah. The Pediatric Cardiology Division is based at Primary Children's Medical Center, a tertiary referral center for a three-state area located on the hills overlooking Salt Lake City. Adults with congenital heart disease are seen at the children's hospital and at nearby 'adult' hospitals. The area offers an excellent quality of life with immense cultural and recreational opportunities close and available.

The University of Utah is an Affirmative Action/Equal Opportunity employer and does not discriminate based upon race, national origin, color, religion, sex, age, sexual orientation, gender identity/ expression, disability, or status as a Protected Veteran. Upon request, reasonable accommodations in the application process will be provided to individuals with disabilities. To inquire about the University's nondiscrimination policy or to request disability accommodation, please contact: Director, Office of Equal Opportunity and Affirmative Action, 201 S. Presidents Circle, Room 135, (801) 581-8365.

Interested individuals should send or email a cover letter and curriculum vitae to:

Lloyd Y. Tani, M.D.
Chief, Division of Pediatric Cardiology
University of Utah School of Medicine
100 N. Mario Capecchi Drive
Salt Lake City, UT 84113
Email: lloyd.tani@iemail.org



Save the Date

JULY 24-27, 2011

WESTIN BOSTON WATERFRONT HOTEL

PICS-AICS BOSTON

PEDIATRIC AND ADULT INTERVENTIONAL CARDIAC SYMPOSIUM



COURSE DIRECTORS: Ziyad M. Hijazi, MD, John P. Cheatham, MD, Carlos Pedra, MD & Thomas K. Jones, MD

- **FOCUSING ON THE LATEST ADVANCES IN INTERVENTIONAL THERAPIES FOR CHILDREN AND ADULTS** with congenital and structural heart disease, including the latest technologies in devices, percutaneous valves, stents and balloons.
- **SPECIAL SESSIONS** will be dedicated to the care of adults with congenital and structural heart disease.
- **HOT DAILY DEBATES** between cardiologists and surgeons on controversial issues in intervention for congenital and structural heart disease.
- The popular session of "MY NIGHTMARE CASE IN THE CATH LAB"
- **LIVE CASE DEMONSTRATIONS** featuring approved and non-approved devices, valves, and stents, and will be transmitted daily from cardiac centers from around the world. During these live cases, the attendees will have the opportunity to interact directly with the operators to discuss the management options for these cases.
- **BREAKOUT SESSIONS** for cardiovascular nurses and CV technicians.
- **MEET THE EXPERT SESSION** will give attendees the opportunity to discuss difficult cases with our renowned faculty.
- **ORAL & POSTER ABSTRACT PRESENTATIONS**
- **ONE DAY SYMPOSIUM** dedicated to the field of IMAGING in congenital and structural cardiovascular interventional therapies.

ACCREDITATION The Society for Cardiovascular Angiography and Interventions is accredited by the Accreditation Council for Continuing Medical Education (ACCME) to sponsor continuing medical education for physicians.


Rush University College of Nursing is an approved provider of continuing nursing education by the Illinois Nursing Association, an accredited approver by the American Nurses Credentialing Center's Commission on Accreditation.

Abstract Submission Deadline is March 25, 2011

For registration and abstract submission go online to www.picsymposium.com



For information on PFO detection go to: www.spencertechnologies.com





Your Search Ends Here.

Pediatric Cardiology is a national provider of outpatient and inpatient cardiology care of the fetus, infant, child and adolescent, as well as adults with congenital heart disease.

We have an opportunity for you, whether you're a recent graduate looking to gain experience or a seasoned pediatric cardiologist seeking a leadership role. With a wide variety of services and a presence in several states, you can choose the practice environment and location that best suits you.

Our Pediatric Cardiologists enjoy:

- Competitive salaries
- Health (choice of two PPO options), life, vision, dental and disability insurance
- 401(k) with potential company percentage match
- Annual CME allowance
- Potential for relocation assistance
- Employee stock purchase plan
- Stability in an organization with more than 30 years of health care industry experience
- Opportunities to participate in clinical quality improvement initiatives and clinical research
- Professional liability insurance
- Assistance with mandatory hospital credentialing and state licensing, and reimbursement of associated fees

More than 90 pediatric cardiologists have chosen to join our team to pursue their personal and professional goals. Now it's your turn.

Please contact us to learn more about pediatric cardiology positions in:

Phoenix, AZ • Springfield, MO
Austin, TX • El Paso, TX • Fairfax, VA





TINY HEARTS INSPIRED HYBRID LABS WITH ACCESS FOR BIG TEAMS.

Fixing a heart from birth through adulthood takes big teams working together. So we examined the needs of leading clinicians when designing our hybrid solutions. The result: our Infinix™-i with 5-axis positioners and low profile detectors, stays out of the way, but right where needed, providing the best possible access to patients. To lead, you must first listen.

medical.toshiba.com

TOSHIBA
Leading Innovation >>>



2010 Top 20 Best In KLAS Awards: Medical Equipment

Ranked #1: Xario™ Ultrasound-General Imaging, Aquilion® CT-64 Slice +, Vantage MRI 1.5T.

Category Leader: Infinix-i Angio in CV/IR x-ray, Aquilion 32 in CT-Under 64 Slice.

www.KLASresearch.com ©2010 KLAS Enterprises, LLC. All rights reserved.