



## Table of Contents

- 1 **The Renata Minima Stent, a Low-Profile Stent for Infants Designed to Reach Adult Sizes, Completes Pivotal Trial Enrollment**  
*Patrick M Sullivan, MD, MS;*  
*Evan Zahn, MD;*  
*Darren P. Berman, MD*
  
- 10 **The PICS Society: The Early Career Development Academy**  
*Kamel Shibbani, MD*
  
- 12 **Medical News**
  - UltraNav System Enables Safer and More Cost-Effective Transseptal Procedures by Aligning Catheter and Ultrasound
  - Edwards Evoque Transcatheter Tricuspid Valve Replacement System Receives CE Mark
  - Celebrating Dr. Gary Webb
  
- 15 **Meeting Calendar**  
**Career Opportunities Throughout**

## The Renata Minima Stent, a Low-Profile Stent for Infants Designed to Reach Adult Sizes, Completes Pivotal Trial Enrollment

*Patrick M Sullivan, MD, MS; Evan Zahn, MD; Darren P. Berman, MD*

### The Problem

Substantial challenges in the design, testing, and regulatory approval of devices used to treat pediatric patients with Congenital Heart Disease (CHD) have contributed to the dearth of available technology to treat this specific population.<sup>1</sup> An analysis of US FDA premarket approval and humanitarian device exemption data revealed that only 16 (3.8%) of the 418 high-risk cardiovascular devices approved between 1977 and 2021 were approved for patients under 18 years of age. Furthermore, fewer than half of the devices labelled for pediatric use were approved based on trials that included pediatric patients.<sup>2</sup> The unmet need for cardiac devices designed specifically for pediatric patients is particularly stark in the cardiac catheterization lab, where it is common to repurpose devices developed for other disease processes and anatomical locations and tested in adult patients.<sup>3</sup> In published data from a large-volume US pediatric cardiac center, approved devices were used for an off-label application in 63% of patients in the catheterization lab and 50% of transcatheter interventions.<sup>4</sup> Repurposed devices tend to lack design features that are important in addressing congenital heart lesions in pediatric patients. These deficiencies can preclude the off-label transcatheter use of devices in many small patients who may instead require open surgical interventions and face exposure to associated physical and neurodevelopmental sequelae.

Vascular stent technology designed for pediatric patients is particularly lacking. Even though balloon-mounted stents have been used to relieve congenital and post-operative vascular obstructions in pediatric patients, even infants, since the late 1980s,<sup>5-9</sup> there is still no FDA approved stent designed and tested for use in infants and children<sup>10</sup> and virtually all stents implanted in the pediatric cardiac catheterization lab are repurposed and used off-label.<sup>4</sup> Ideally, a pediatric vascular stent would have, among other features, a low-profile delivery system safe for small vessels, conformability to unique and highly variable anatomical features, and the capacity to reach adult size while maintaining structural integrity as the patient grows. As of now, there is no available product with these features.

For example, the Cheatham Platinum stent systems (NuMED, Hopkinton, NY, USA) have been FDA approved for treatment of coarctation of the aorta based on data from older children and adults enrolled in the COAST and COAST II trials. But the available stent sizes and the relatively large delivery system required for this technology prohibits its use in infants and small children in most circumstances. The Palmaz Mullins XD stent (Cordis, Miami Lakes, FL, USA) recently became the first stent to be granted FDA approval for implantation in children, specifically for the treatment of pulmonary artery stenosis in patients larger than 10 kg. This approval was based on a review of retrospective off-label implantations from multiple pediatric centers across the US and represents a unique and promising path to approval for devices commonly repurposed for the treatment of CHDs. However, this stent, like many implanted by pediatric interventional cardiologists, was originally designed for adult biliary interventions and its length, profile, and other features make it inappropriate for the treatment of many lesions



## TABLE OF CONTENTS

### 1 **The Renata Minima Stent, a Low-Profile Stent for Infants Designed to Reach Adult Sizes, Completes Pivotal Trial Enrollment**

*Patrick M Sullivan, MD, MS; Evan Zahn, MD; Darren P. Berman, MD*

### 10 **The PICS Society: The Early Career Development Academy**

*Kamel Shibbani, MD*

### 12 **Medical News**

- UltraNav System Enables Safer and More Cost-Effective Transseptal Procedures by Aligning Catheter and Ultrasound
- Edwards Evoque Transcatheter Tricuspid Valve Replacement System Receives CE Mark
- Celebrating Dr. Gary Webb

### 15 **Meeting Calendar**

#### **Career Opportunities Throughout**



**ONOCOR**  
Advancing Safety First

Interventional Systems  
**B | BRAUN**  
SHARING EXPERTISE

Plan Beyond.

## ONO™ Retrieval Device

Plan beyond what was previously in reach with the ONO Retrieval Device. This enabling technology is designed to receive, align, compress and remove material from the vascular system.

For more information or to place an order, contact your B. Braun Interventional Systems Representative or call 877-836-2228.

Rx only  
ONO and ONOCOR are trademarks of ONOCOR LLC.  
Distributed by: B. Braun Interventional Systems Inc. | Part of the B. Braun Group of Companies.  
Bethlehem, PA 18018 | USA | Tel 877-836-2228 | [www.bisusa.com](http://www.bisusa.com)



# Medtronic


Harmony™  
Transcatheter Pulmonary Valve

# Made for this

.....

Treating congenital heart disease patients with native or surgically repaired RVOT and severe pulmonary regurgitation takes focus. The Harmony TPV is made for this moment. It's the first FDA approved minimally invasive valve specifically designed for the native RVOT.

[Learn more at medtronic.com/madeforthis](https://www.medtronic.com/madeforthis)



## Indications

The Harmony™ transcatheter pulmonary valve (TPV) system is indicated for use in the management of pediatric and adult patients with severe pulmonary regurgitation (i.e., severe pulmonary regurgitation as determined by echocardiography and/or pulmonary regurgitant fraction  $\geq 30\%$  as determined by cardiac magnetic resonance imaging) who have a native or surgically-repaired right ventricular outflow tract and are clinically indicated for surgical pulmonary valve replacement.

## Contraindications

The following are contraindications for the use of this device: active bacterial endocarditis or any other active infections, known intolerance to Nitinol (titanium or nickel), or an anticoagulation/antiplatelet regimen.

## Warnings

General: Implantation of the Harmony TPV system should be performed only by physicians who have received Harmony TPV system training. The transcatheter pulmonary valve (TPV) is to be used only in conjunction with the Harmony delivery catheter system (DCS). This procedure should only be performed where emergency pulmonary valve surgery can be performed promptly. Do not use any of the Harmony TPV system components if any of the following has occurred: it has been dropped, damaged, or mishandled in any way, or if the use-by date has elapsed.

Transcatheter pulmonary valve (TPV): This device was designed for single use only. Do not reuse, reprocess, or resterilize the TPV. Reuse, reprocessing, or resterilization may compromise the structural integrity of the device and/or create a risk of contamination of the device, which could result in patient injury, illness, or death. Do not resterilize the TPV by any method. Exposure of the device and container to irradiation, steam, ethylene oxide, or other chemical sterilants renders the device unfit for use. The device is packaged with a temperature sensor. Do not freeze the device. Do not expose the device to extreme temperatures. Do not use the device if the arrow on the sensor points to the symbol that indicates that the temperature limit has been exceeded. Do not use the device if any of the following have occurred: the tamper-evident seal is broken, the serial number tag does not match the container label, the arrow on the sensor points to the symbol that indicates that the temperature limit has been exceeded, or the device is not completely covered by the storage solution. Do not contact any of the Harmony TPV system components with cotton or cotton swabs. Do not expose any of the Harmony TPV system components to organic solvents, such as alcohol. Do not introduce air into the catheter. Do not expose the device to solutions other than the storage and rinse solutions. Do not add or apply antibiotics to the device, the storage solution, or the rinse solution. Do not allow the device to dry. Maintain tissue moisture with irrigation or immersion. Do not attempt to repair a damaged device. Do not handle the valve leaflet tissue or use forceps to manipulate the valve leaflet tissue. Do not attempt to recapture the device once deployment has begun. Do not attempt to retrieve the TPV if any one of the outflow TPV struts is protruding from the capsule. If any one of the outflow TPV struts has deployed from the capsule, the TPV must be released from the catheter before the catheter can be withdrawn. Do not attempt post-implant balloon dilatation (PID) of the TPV during the procedure, which may cause damage to or failure of the TPV leading to injury to the patient resulting in reintervention.

Delivery catheter system (DCS): This device was designed for single use only. Do not reuse, reprocess, or resterilize the DCS. Reuse, reprocessing, or resterilization may compromise the structural integrity of the device and/or create a risk of contamination of the device, which could result in patient injury, illness, or death. Do not reuse or resterilize the DCS. If resistance is met, do not advance the guidewire, DCS, or any other component without first determining the cause and taking remedial action. Do not remove the guidewire from the DCS at any time during the procedure.

## Precautions

General: Clinical long-term durability has not been established for the Harmony TPV. Evaluate the TPV performance as needed during patient follow-up. The safety and effectiveness of Harmony TPV implantation in patients with pre-existing prosthetic heart valve or prosthetic ring in any position has not been demonstrated. The Harmony TPV system has not been studied in female patients of child-bearing potential with positive pregnancy.

Before use: Exposure to glutaraldehyde may cause irritation of the skin, eyes, nose, and throat. Avoid prolonged or repeated exposure to the chemical vapor. Use only with adequate ventilation. If skin contact occurs, immediately flush the affected area with water (for a minimum of 15 minutes) and seek medical attention immediately. The TPV and the glutaraldehyde storage solution are sterile. The outside of the TPV container is nonsterile and must not be placed in the sterile field. The TPV and DCS should be used only in a sterile catheterization laboratory (cath lab) environment. Ensure that sterile technique is used at all times. Strictly follow the TPV rinsing procedure. For TPV 25: Ensure that all green sutures have been removed from the attachment suture loops on the TPV before loading onto the DCS. Prevent contamination of the TPV, its storage solution, and the DCS with glove

powder. Verify the orientation of the TPV before loading it onto the DCS. The inflow end of the TPV with attachment suture loops must be loaded first. Do not place excessive pressure on the TPV during loading. Inspect the sealed DCS packaging before opening. If the seal is broken or the packaging has been damaged, sterility cannot be assured. Proper functioning of the DCS depends on its integrity. Use caution when handling the DCS. Damage may result from kinking, stretching, or forceful wiping of the DCS. This DCS is not recommended to be used for pressure measurement or delivery of fluids. Carefully flush the DCS and maintain tight DCS connections to avoid the introduction of air bubbles.

During use: The TPV segment is rigid and may make navigation through vessels difficult. Do not advance any portion of the DCS under resistance. Identify the cause of resistance using fluoroscopy and take appropriate action to remedy the problem before continuing to advance the DCS. Careful management of the guidewire is recommended to avoid dislodgement of the TPV during DCS removal. Once deployment is initiated, retrieval of the TPV from the patient is not recommended. Retrieval of a partially deployed valve may cause mechanical failure of the delivery catheter system or may cause injury to the patient. Refer to the section below for a list of potential adverse events associated with Harmony TPV implantation. During deployment, the DCS can be advanced or withdrawn prior to the outflow struts protruding from the capsule. Once the TPV struts contact the anatomy during deployment, it is not recommended to reposition the device. Advancing the catheter forward once the TPV struts make contact with the anatomy may lead to an undesired deployment or may cause damage to or failure of the TPV and injury to the patient. Refer to the section below for a list of potential adverse events associated with the Harmony TPV implantation. Physicians should use judgment when considering repositioning of the TPV (for example, using a snare or forceps) once deployment is complete. Repositioning the bioprosthesis is not recommended, except in cases where imminent serious harm or death is possible (for example, occlusion of the main, left, or right pulmonary artery). Repositioning of a deployed valve may cause damage to or failure of the TPV and injury to the patient. Refer to the section below for a list of potential adverse events associated with the Harmony TPV implantation. Ensure the capsule is closed before DCS removal. If increased resistance is encountered when removing the DCS through the introducer sheath, do not force passage. Increased resistance may indicate a problem and forced passage may result in damage to the device and harm to the patient. If the cause of resistance cannot be determined or corrected, remove the DCS and introducer sheath as a single unit over the guidewire, and inspect the DCS and confirm that it is complete. If there is a risk of coronary artery compression, assess the risk and take the necessary precautions. Endocarditis is a potential adverse event associated with all bioprosthetic valves. Patients should make their healthcare providers aware that they have a bioprosthetic valve before any procedure. Post-procedure, administer appropriate antibiotic prophylaxis as needed for patients at risk for prosthetic valve infection and endocarditis. Prophylactic antibiotic therapy is recommended for patients receiving a TPV before undergoing dental procedures. Post-procedure, administer anticoagulation and/or antiplatelet therapy per physician/clinical judgment and/or institutional protocol. Excessive contrast media may cause renal failure. Preprocedure, measure the patient's creatinine level. During the procedure, monitor contrast media usage. Conduct the procedure under fluoroscopy. Fluoroscopic procedures are associated with the risk of radiation damage to the skin, which may be painful, disfiguring, and long term.

## Potential Adverse Events

Potential risks associated with the implantation of the Harmony TPV may include, but are not limited to, the following: • death • valve dysfunction • tissue deterioration • hematoma • heart failure • cerebrovascular incident • perforation • rupture of the right ventricular outflow tract (RVOT) • compression of the aortic root • compression of the coronary arteries • sepsis • pseudoaneurysm • erosion • stent fracture • arrhythmias • device embolization or migration • pulmonary embolism • occlusion of a pulmonary artery • laceration or rupture of blood vessels • device misorientation or misplacement • valve deterioration • regurgitation through an incompetent valve • physical or chemical implant deterioration • paravalvular leak • valve dysfunction leading to hemodynamic compromise • residual or increasing transvalvular gradients • progressive stenosis and obstruction of the implant • hemorrhage • endocarditis • thromboembolism • thrombosis • thrombus • intrinsic and extrinsic calcification • bleeding • bleeding diathesis due to anticoagulant use • fever • pain at the catheterization site • allergic reaction to contrast agents • infection • progressive pulmonary hypertension • progressive neointimal thickening and peeling • leaflet thickening • hemolysis. General surgical risks applicable to transcatheter pulmonary valve implantation: • abnormal lab values (including electrolyte imbalance and elevated creatinine) • allergic reaction to antiplatelet agents, contrast medium, or anesthesia • exposure to radiation through fluoroscopy and angiography • permanent disability.

Please reference the Harmony TPV system instructions for use for more information regarding indications, warnings, precautions, and potential adverse events.

**CAUTION:** Federal law (USA) restricts these devices to the sale by or on the order of a physician.

# Medtronic

710 Medtronic Parkway  
Minneapolis, MN 55432-5604  
USA  
Tel: (763) 514-4000  
Fax: (763) 514-4879  
Toll-free: (800) 328-2518

**LifeLine**  
**CardioVascular Technical Support**  
Tel: (877) 526-7890  
Tel: (763) 526-7890  
Fax: (763) 526-7888  
rs.structuralheart@medtronic.com

©2022 Medtronic.  
All rights reserved.  
Medtronic and the Medtronic logo  
are trademarks of Medtronic.  
All other brands are trademarks  
of a Medtronic company.

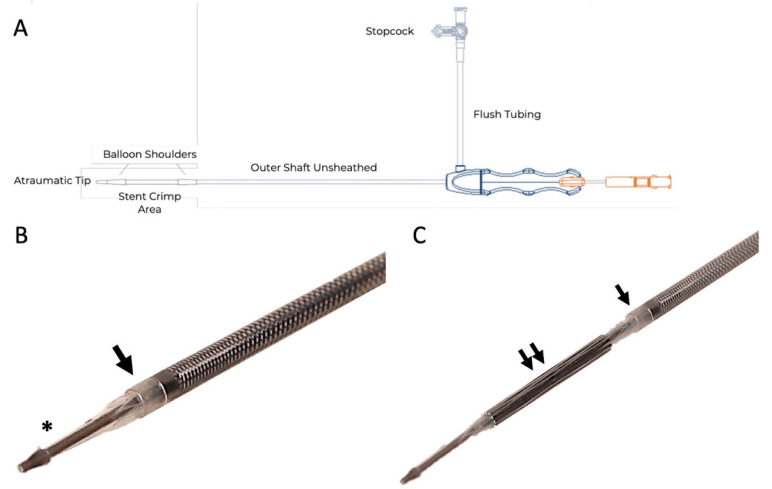


in small patients. Its approval did not necessarily address the unmet need for a truly pediatric stent. Operators have published techniques for tailoring available stents to fit the anatomy of small CHD patients<sup>11</sup> and fracturing or ‘unzipping’ small stents once the vessel has outgrown the stent’s expansion capacity,<sup>12-14</sup> and bioresorbable stents have been proposed and investigated, but these approaches have drawbacks and have not become standard.

**The Device**

Renata Medical (Newport Beach, CA, USA) was founded with the goal of focusing on the unmet need for cardiovascular devices designed to treat pediatric CHD patients. Their first product to enter clinical trials is the Minima stent, a 16.8 mm long closed-cell, balloon-expandable, cobalt-chromium stent with a cell design that provides structural integrity and radial strength over a wide range of achievable diameters from 5 mm to 24 mm. The stent requires serial expansions with balloon angioplasty to keep up with somatic and vessel growth until adulthood and has a predictable amount of progressive foreshortening as it is expanded (**Figure 1**).

The stent is pre-mounted on a 63 cm covered balloon catheter with the same outer diameter as a 4 Fr sheath, which is a size typically suitable for neonate arteries and veins. The system is designed so that the balloon catheter tip acts as a tapered dilator with a smooth transition to the outer covering. This protects the front-loaded stent and allows the system to be introduced directly into the access vessel without the need for a long sheath and to track smoothly over a .014” or .018”

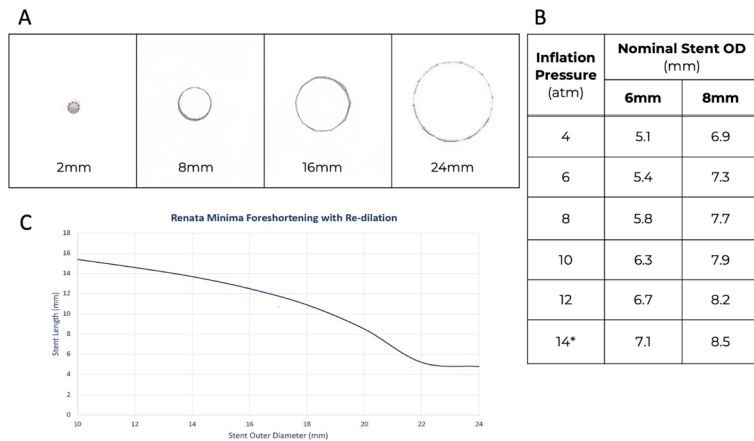


**FIGURE 2 The Renata Minima Stent Delivery System** A) The stent is pre-mounted on a 4-French 63 cm covered balloon catheter, schematically depicted here, that tracks over a .014” or .018” wire. The handle on the back end of the system has flush tubing for saline or contrast and mechanisms for locking, unlocking and retracting the outer sheath over the stent for deployment. B) The balloon catheter tip (\*) acts a tapered dilator with a smooth transition to the outer covering (Arrow). This protects the front-loaded stent and allows the system to be smoothly introduced through the skin if needed. C) Unlocking and retraction of the outer sheath (single arrow) exposes the pre-mounted stent (double arrow) for deployment.

guide wire. There is a handle on the back end of the system with mechanisms for flushing saline or contrast through the outer sheath and for retracting the outer sheath over the stent when the stent is ready to be deployed (**Figure 2**). The delivery system is currently available with a 6 mm or 8 mm compliant balloon allowing for implant diameters between 5 mm and 8.5 mm.

Results from animal testing of the Renata Minima stent system in neonate-sized piglets were published in 2021.<sup>15</sup> Twenty-two stents were implanted in the aortas, pulmonary arteries, and jugular veins in the piglets at an average weight of 4.6 kg. The stents were dilated to an average diameter of about 7 mm on initial implantation with an average recoil of about 10%. Reassuringly, the stents responded reliably to further balloon dilation from infant to adult size during follow up in the rapidly growing porcine model and did not show signs of in-stent restenosis, loss of structural stent integrity, or important vessel wall injury.

An early feasibility study of human implantations began in February 2022, with enrollment of ten patients at four centers. Based on reassuring safety and efficacy data, a pivotal study was expanded to 42 patients at seven centers, and enrollment was complete by August of 2023 (ClinicalTrials.gov ID:NCT05086016). This single-arm, prospective, non-randomized, multi-center study was open to neonates, infants, and small children with native, acquired, or recurrent coarctation of the aorta or branch pulmonary artery stenosis. Patients with a known or suspected underlying genetic arteriopathy like Williams, Alagille, or Turner syndromes, were excluded. Primary endpoints include measures of acute relief of stenosis, freedom



**FIGURE 1 The Renata Minima Stent** A) The 16.8 mm long closed-cell stent provides structural integrity and radial strength over a wide range of achievable diameters from 5 mm to 24 mm. This image shows the low-profile stent crimped for delivery through small vessels (left), followed by serial benchtop expansion to 8 mm, 16 mm, and 24 mm, from left to right. B) The stent is pre-mounted on either a 6mm or 8 mm compliant balloon for initial implantation and can achieve a range of initial diameters to fit the anatomy of the vessel depending on the pressure delivered by the implanter. C) The stent requires serial expansions with balloon angioplasty to keep up with vessel growth and has a predictable amount of foreshortening as it is expanded.

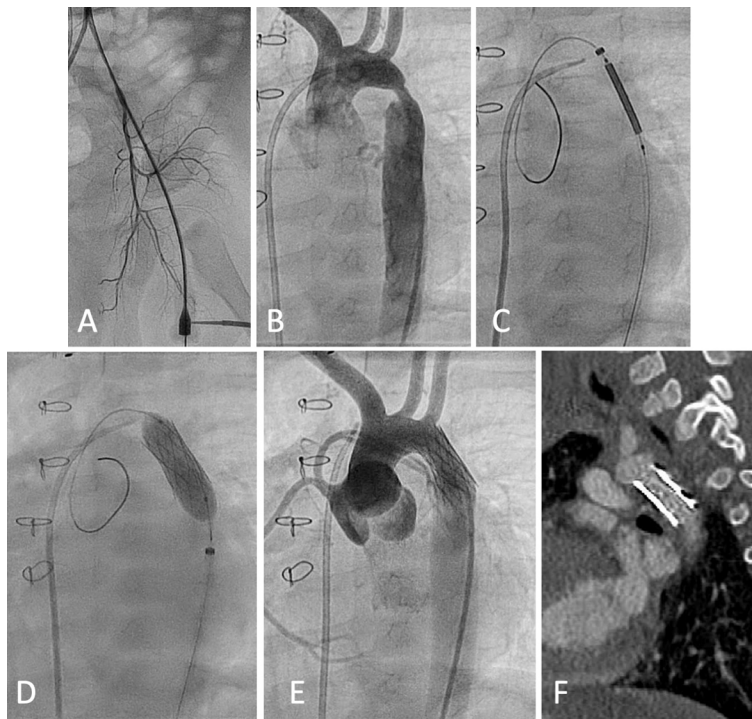


from open surgical intervention to treat stent dysfunction through six months of follow-up, and maintenance of stent lumen diameter as measured on CT angiography six months after implantation. The study also aims to track the success of any repeat balloon dilations of the stents during the study period. Early results from the trial were presented at the most recent Pediatric and Congenital Interventional Cardiovascular Society (PICS) late-breaking clinical trials session in Washington, DC. We are currently awaiting completion of six-month follow up and outcomes data before submission for FDA approval and publication of results. Subjects will be followed for up to five years as part of the study.

## Case Examples

### Case 1: Coarctation of the Aorta in an Infant

A five-month-old, 6.5 kg infant with a history of surgically repaired d-transposition of the great arteries and coarctation of the aorta was referred to our catheterization lab for treatment of a severe recurrent coarctation of the aorta. He had previously undergone transcatheter balloon aortic angioplasty using a 6 mm balloon at two months of age that resulted in a residual 20 mmHg aortic arch gradient. The gradient and appearance of the coarctation progressively worsened on follow-up



**FIGURE 3** Renata Minima Stent Delivery and Implantation for Recurrent Coarctation of the Aorta in a 5-month-old, 6.5 kg Infant **A)** The patient is accessed via the left femoral artery, which measures 2.4 mm in diameter. **B)** Angiography in the aortic arch shows a severe coarctation of the aorta. **C)** The pre-mounted and front-loaded Renata Minima stent system is delivered via the femoral artery and **D)** dilated within the coarctation **E)** resolving the lesion. **F)** CT angiography 6 months after stent implantation shows stable patency and integrity of the stented aorta.

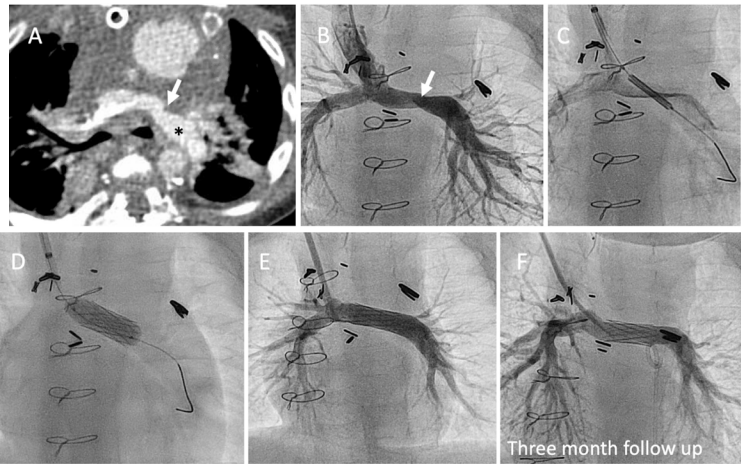
echocardiography. At the time of his referral, there was a severe discrete recurrent coarctation of the aorta with peak and mean Doppler gradients of 122 mmHg and 56 mmHg, respectively. We considered the patient's inadequate and short-lived response to prior angioplasty a failure and felt that primary stent implantation was likely necessary. The anatomy was thought to be appropriate for the Renata Minima stent based on the echo and prior angiography. The patient's family consented to participate in the study prior to the catheterization.

We placed a 4 Fr sheath in the femoral artery, which measured 2.4 mm in caliber (**Figure 3A**). Baseline hemodynamics showed normal cardiac output and a peak-to-peak pressure gradient of 48 mmHg across the coarctation. Angiography showed a severe coarctation measuring 2.3 mm in caliber compared to 7.7 mm in the distal transverse arch (**Figure 3B**). These measurements fell within the target range for Minima stent implantation, so we proceeded with primary stenting using the 8mm Minima stent system with a target dilation pressure of 10 atm to achieve a stent implantation diameter of 7.9 mm. We positioned a .018" Hi-Torque Steelcore Guide Wire (Abbott Cardiovascular, Plymouth, MN, USA) across the coarctation from the femoral artery and exchanged the access sheath for the Minima delivery system, which was easily advanced directly through the access site to the coarctation (**Figure 3C**). We unsheathed the stent and dilated it to the target pressure and diameter (**Figure 3D**) and then exchanged the delivery system for the original access sheath to repeat angiography and pressures, which showed excellent expansion of the coarctation, no vascular injury, and a minimal 3 mmHg residual pressure gradient (**Figure 3E**). The patient was discharged the following day with normal lower extremity pulses after post-procedure echo showed improved peak and mean Doppler gradients of 22 mmHg and 8 mmHg, respectively.

On follow-up, his six-month post-procedure CTA showed stable stent caliber and integrity with no aortic wall injury or significant in-stent restenosis (**Figure 3F**). He has had no stent fractures on chest radiography. At the one year follow-up, he had no blood pressure cuff gradient from upper to lower extremities and echo showed stable Doppler velocities across the stent. On his most recent follow-up, he is 23-months-old and weighs 12.4 kg. He has a 20 mmHg blood pressure cuff gradient on exam now and increasing peak and mean echo Doppler gradients of 62 mmHg and 35 mmHg, respectively, in the descending aorta with blunted pulsation of the abdominal aortic waveform. We plan on repeating a catheterization two years after initial stent implantation to further expand the stent to keep pace with somatic growth.

### Case 2: Left Pulmonary Artery Stenosis in an Infant with Single Ventricle CHD after Glenn Anastomosis

A medically complex eight-month-old, 6 kg infant with hypoplastic left heart syndrome presented one month after Glenn anastomosis and pulmonary arterioplasty with concern for worsening LPA stenosis. A CT scan (**Figure 4A**) showed significant narrowing in the proximal native LPA measuring about



**FIGURE 4** Renata Minima Stent Implantation for Left Pulmonary Artery (LPA) Stenosis in a 6 kg Infant After Glenn Anastomosis. **A)** CT scan characterized a suspected narrowing of the proximal native LPA (arrow), which measured 3mm compared to the 7 mm distal vessel (\*). **B)** On transcatheter angiography, there is a narrowing and twisting in the LPA. **C)** The Minima stent system is delivered through a 6 Fr sheath and contrast injections through the delivery system's flushport allows for accurate positioning of the stent after the outer sheath is retracted. **D)** The stent is dilated on the 6mm balloon to a target pressure and size of 14 atms and 7.1 mm, respectively. **E)** Appears improved on repeat angiography, measuring about 7.1 mm at either end of the stent. **F)** On follow up angiography three months after initial implantation, the stent remains intact and in stable position and without obvious in-stent restenosis.

3 mm compared to about 7mm in the distal vessel. The vessel size and length of the lesion were appropriate for the Renata Minima stent and the patient's family consented to participate in the study prior to the catheterization.

In the cath lab, we placed a 6 Fr sheath in the right internal jugular vein. There was a mild pressure gradient across the LPA and angiography (**Figure 4B**) showed a narrowing with some twisting. The measurements of the stenosis and surrounding vessel were similar to the CT scan. We selected the 6mm Renata Minima stent system with the intention to dilate it to a pressure of 14 atms to target a final stent diameter of 7.1 mm. We positioned the delivery system over the .018" Steelcore Guide Wire (Abbott Cardiovascular, Plymouth, MN, USA) through the 6 Fr sheath that was already in the jugular vein. Small contrast injections through the device's flushport allowed us to accurately position the stent after the outer sheath had been retracted (**Figure 4C**) and we dilated the stent to the intended size (**Figure 4D**). After deployment, the stent measured 6.3 mm at its narrowest and the intended 7.1 mm at either end (**Figure 4E**).

The patient underwent repeat cardiac catheterization three months later to evaluate the aortic arch after follow-up echocardiography showed worsening arch obstruction and single ventricle dysfunction. There was no pressure gradient across the LPA and angiography showed an intact stent in stable position and no obvious in-stent restenosis or vessel wall injuries (**Figure 4F**). CT angiography six months after implantation showed stable findings.

## Conclusions

The Renata Minima stent has shown early promising clinical results supporting optimism that this may be the first vascular stent developed for, systematically tested in, and potentially approved for use in infants and small children with congenital heart disease. While there remains an enormous unmet need for bespoke technologies and devices for children with congenital heart disease, this experience provides an encouraging example of how close collaboration between clinician innovators, biomedical engineers, industry, and government regulatory agencies can begin to fill this long-overlooked void.

## References

1. Beekman RH 3rd, Duncan BW, Hagler DJ, Jones TK, Kugler JD, Moore JW, Jenkins KJ; Workgroup on Pediatric Cardiac Devices, Section on Cardiology and Cardiac Surgery, American Academy of Pediatrics. Pathways to approval of pediatric cardiac devices in the United States: challenges and solutions. *Pediatrics*. 2009 Jul;124(1):e155-62.
2. Wunnava S, Miller TA, Narang C, Nathan M, Bourgeois FT. US Food and Drug Administration Approval of High-risk Cardiovascular Devices for Use in Children and Adolescents, 1977-2021. *JAMA*. 2022 Aug 9;328(6):580-582.
3. Jenkins KJ, Beekman RH, Vitale MG, Hennrikus WL; American Academy of Pediatrics Section on Cardiology and Cardiac Surgery and Section on Orthopaedics. Off-label use of medical devices in children. *Pediatrics*. 2017;139(1):e20163439.
4. Sutherell JS, Hirsch R, Beekman RH III. Pediatric interventional cardiology in the United States is dependent on the off-label use of medical devices. *Congenit Heart Dis*. 2010;5(1):2-7.
5. O'Laughlin MP, Perry SB, Lock JE, Mullins CE. Use of endovascular stents in congenital heart disease. *Circulation*. 1991;83(6): 1923-39.
6. O'Laughlin MP, Slack MC, Grifka RG, Perry SB, Lock JE, Mullins CE. Implantation and intermediate-term follow-up of stents in congenital heart disease. *Circulation*. 1993;88(2): 605-14.
7. Mullins CE, O'Laughlin MP, Vick GW 3rd, Mayer DC, Myers TJ, Kearney DL, Schatz RA, Palmaz JC. Implantation of balloon-expandable intravascular grafts by catheterization in pulmonary arteries and systemic veins. *Circulation*. 1988 Jan;77(1):188-99.
8. Hatai Y, Nykanen DG, Williams WG, Freedom RM, Benson LN. Endovascular stents in children under 1 year of age: acute impact and late results. *Br Heart J*. 1995 Dec;74(6):689-95.
9. Stanfill R, Nykanen DG, Osorio S, Whalen R, Burke RP, Zahn EM. Stent implantation is effective treatment of vascular stenosis in young infants with congenital heart disease: acute implantation and long-term follow-up results. *Catheter Cardiovasc Interv*. 2008 May 1;71(6):831-41.




10. Peters B, Ewert P, Berger F. The role of stents in the treatment of congenital heart disease: Current status and future perspectives. *Ann Pediatr Cardiol.* 2009 Jan;2(1):3-23.
11. Sullivan PM, Liou A, Takao C, Justino H, Petit CJ, Salazar JD, Ing FF. Tailoring stents to fit the anatomy of unique vascular stenoses in congenital heart disease. *Catheter Cardiovasc Interv.* 2017 Nov 15;90(6):963-971.
12. Morray BH, McElhinney DB, Marshall AC, Porras D. Intentional Fracture of Maximally Dilated Balloon-Expandable Pulmonary Artery Stents Using Ultra-High-Pressure Balloon Angioplasty: A Preliminary Analysis. *Circ Cardiovasc Interv.* 2016 Apr;9(4):e003281.
13. Ing FF, Fagan TE, Kearney DL. A new "open-ring" stent (abstr). *Circulation.* 1996;94:1-57.
14. Ewert P, Riesenkampff E, Neuss M, Kretschmar O, Nagdyman N, Lange PE. Novel growth stent for the permanent treatment of vessel stenosis in growing children: an experimental study. *Catheter Cardiovasc Interv.* 2004 Aug;62(4):506-10.
15. Zahn EM, Abbott E, Tailor N, Sathanandam S, Armer D. Preliminary testing and evaluation of the renata minima stent, an infant stent capable of achieving adult dimensions. *Catheter Cardiovasc Interv.* 2021 Jul 1;98(1):117-127.




**PATRICK M SULLIVAN, MD, MS**

Assistant Professor of Pediatrics, Keck School of Medicine of USC  
Attending Cardiologist, Children’s Hospital Los Angeles Heart Institute  
Los Angeles, CA, USA  
323.361.2461  
[Psullivan@chla.usc.edu](mailto:Psullivan@chla.usc.edu)



**EVAN ZAHN, MD**

Director, Guerin Family Congenital Heart Program and Division of Pediatric Cardiology Consultant, Pediatric Cardiology  
Cedars Sinai Medical Center  
Los Angeles, CA, USA



**DARREN P. BERMAN, MD**

Associate Professor of Pediatrics, Keck School of Medicine of USC  
Director, Congenital Interventional Catheterization, Children’s Hospital Los Angeles Heart Institute  
Los Angeles, CA, USA



## Outpatient Imaging Cardiologist

The Ward Family Heart Center at Children’s Mercy Kansas City seeks a pediatric cardiologist at the assistant or associate professor level who would have equal roles in echocardiography and general outpatient cardiology. The successful candidate would join an existing group of 28 cardiologists (25 in Kansas City, 2 in Wichita, KS and 1 in Topeka, KS), 4 CV surgeons, 30 APNs. Experience and interest in peri-operative and peri-procedural TEE is a must. Proficiency in 3D and stress echocardiography is preferred. Training/knowledge in MR/CT imaging is preferred but not required. Trainees in their final year are welcome to apply. In addition to providing echocardiography coverage, the successful candidate will be expected to spend one-two days per week in our local general outpatient clinics and serve as attending on cardiology inpatient or consult service 4-6 weeks/year.

Candidates must be board-certified or board-eligible in Pediatric Cardiology. Strong communication skills are key. There are ample opportunities for clinical/translational research and teaching (medical students, residents and Pediatric Cardiology fellows). Salary and academic rank are commensurate with experience.

Our Heart Center serves a population of over 5 million in the heart of the U.S.A. We perform over 500 cardiac operations, 600 cardiac catheterizations including over 200 invasive EP procedures, 18,000 outpatient visits, and more than 20,000 echocardiograms annually. Our two state-of-the-art catheterization labs are both hybrid labs and equipped with the latest 3D imaging and EP technology. Telehealth is available and facilitates our outreach clinics. We have video-conferencing capabilities that are routinely used by providers from distant locations to dial into our conferences for patient care and education. In 2022, the Ward Family Heart Center program was ranked #19 nationally by USNWR.

Our super-specialty resources include Electrophysiology (which includes Clinical EP, pacing and Genetic Arrhythmia), Cardiac Transplantation/Heart Failure, Interventional Cardiology and Advanced Cardiac Imaging (fetal echo, 3D echo, trans-esophageal echo, CT, MRI and 3D printing). We also provide specialized, team-based care in Fetal Cardiology (with on-site delivery services for high-risk neonates), Interstage Monitoring (CHAMP), Preventive Cardiology, Cardiac Genetics, Cardio-oncology, Single Ventricle Survivorship, Pulmonary Hypertension, a dedicated POTS clinic and Cardiac Neurodevelopmental Services.

**Please submit CV and cover letter to:**  
<https://faculty-childrensmercykc.icims.com/jobs/27456/physician/job>

**For more information:**  
Aliessa Barnes MD  
Co-Director, Ward Family Heart Center; Chief, Section of Cardiology  
816.983.6225, [apbarnes@cmh.edu](mailto:apbarnes@cmh.edu)

For more information about Children’s Mercy Kansas City and about Kansas City itself, visit [cmkc.link/TakeYourPlace](https://cmkc.link/TakeYourPlace).





# The Congenital Heart Collaborative

University Hospitals  
Rainbow Babies & Children's  
Nationwide Children's Hospital

## General Pediatric Cardiologist

The Congenital Heart Collaborative (TCHC), an affiliation between University Hospitals Rainbow Babies & Children's Hospital (Cleveland OH) and Nationwide Children's Hospital (NCH, Columbus OH) heart programs, seeks candidates in **Pediatric Cardiology** for a faculty position in our expanding group at UH Rainbow Babies & Children's Hospital. The successful candidate will join a group of physicians that model teamwork, collaboration and dedication to their patients and partners and be a part of an innovative clinical and educational program, representing the section in the community, nationally, and internationally. The Section consists of nine board-certified pediatric cardiologists including interventionalists, electrophysiologist, advanced imaging cardiologists, fetal cardiologists, general cardiologist, and 2 cardiovascular surgeons. This position is to replace a vacancy created by a relocating faculty member. The candidate will have opportunities to participate in quality improvement initiatives, clinical research, education of medical students, residents, and fellows and clinical time devoted to imaging, outpatient and inpatient care, including outreach clinic sessions.

Qualified applicants must have an MD, DO or MD/PhD degree, be BE/BC in Pediatric Cardiology. The rank and appointment will be commensurate with the candidate's credentials and experience.

The successful candidate will be well-supported at a world-class children's hospital that has over 60 years of experience in the care of pediatric and ACHD patients; an outstanding educational and research enterprise at Case Western Reserve University School of Medicine, and an internationally recognized program partner with the NCH Heart Center. TCHC is a dedicated service line with a common executive administration and functions as one program on two campuses with the commitment to expand access to high-quality comprehensive cardiac care along with a scholarly and educational mission. TCHC provides excellent cardiothoracic surgical, interventional, electrophysiologic, and non-invasive services.

Please send letter and curriculum vitae to **Harinder Singh, MD**, Section Chief, Pediatric Cardiology at Rainbow Babies & Children's Hospital, [harinder.singh@uhhospitals.org](mailto:harinder.singh@uhhospitals.org). In employment, as in education, Case Western Reserve University is committed to equal opportunity and diversity. Women, veterans, members of underrepresented minority groups and individuals with disabilities are encouraged to apply.

Among the nation's leading academic medical centers, University Hospitals Case Medical Center is the primary affiliate of Case Western Reserve University School of Medicine, a nationally recognized leader in medical research and education.



# The Early Career Development Academy

Kamel Shibbani, MD

The PICS Society is getting ready to launch a fantastic new project aimed at advancing professional development of early career pediatric and congenital interventional cardiologists globally. This two-year hybrid program will have virtual and in-person components and will encompass didactic sessions, team learning activities, mentorship, research, and much more. Kamel Shibbani (KS) had the fortune of chatting with the Co-Directors of the Early Career Development Academy, Drs. Gianfranco Butera (GB) and Aimee Armstrong (AA), to learn more about this wonderful project!

**KS: Thank you both for taking time from your busy schedules to talk to us about this extremely exciting project. Can you tell us more about the Early Career Development Academy?**

**GB:** The Early Career Development Academy is our effort to create a global program for interventional cardiologists who are still in the early parts of their career. The idea is to bring together 25 people from across the globe and divide them into teams, with each team having a mentor. We have chosen very senior interventional cardiologists to act as mentors. The program will take place over a two-year period during which there will be regular talks for the attendees as well as assigned projects or “challenges” for the teams.

There will be roughly one webinar a month on different subjects covering a wide range of technical issues, procedures, and devices in congenital interventional cardiology. There will also be three dedicated in-person sessions at both the PICS meeting and the CSI meeting. In addition, we will have talks about soft skills, team building, dealing with complications, and much more. We will have people from other fields give us talks about issues that overlap with our own field such as the importance of checklists, resilience, leadership, and how to create a healthy work-life balance.

Regarding the “challenges,” these will include preparing a review paper, creating a research or QI project, and writing a case presentation from each team. These, of course, will all be done under the guidance of the mentor and have been crafted in a way to promote collaboration within each team.

**“One of the goals of the Early Career Development Academy and the Early Career Development Committee of the PICS Society is to build a global community for early career interventionalists where people can help each other and learn from each other.”**

– Gianfranco Butera

**AA:** The Early Career Development committee of the PICS Society recently sent out a global survey, spearheaded by Dr. Varun Aggarwal, to interventional training programs to get a sense of the current state of interventional training around the world. Some of the feedback we got from program directors is that early career interventionalists continue to need ongoing professional development and development of clinical skills. This Academy is crafted with the intention of supporting the professional development of early career interventionalists through didactics, discussions, and formal mentorship.



*Drs. Gianfranco Butera and Aimee Armstrong, Co-Directors of the Early Career Development Academy*

**KS: Can you talk more about the faculty that will be involved in the Early Career Development Academy?**

**AA:** We have more than 60 faculty that have agreed to participate in the academy in some capacity! For the most part, the talks will be given by senior interventional cardiologists from around the world. The mentors are very senior leaders in our field and include Drs. Lee Benson, Mario Carminati, John Cheatham, Ziyad Hijazi, and Shakeel Qureshi.

**KS: This sounds like a wonderful opportunity! It sounds like there was an intentional effort to include junior interventionalists from around the world?**

**GB:** Absolutely. We want this to be an opportunity for early career interventionalists from every country in the world! One of the goals of the Early Career Development Academy and the Early Career Development committee of the PICS Society is to build a global community for early career interventionalists where people can help each other and learn from each other.



**AA:** Yes, that is very important to us! And we have actually outlined that we want to have participants from each continent. We will likely vary the times of the didactic lectures to ensure that people in different time zones will get to participate in most of the lectures. This will be a great opportunity for participants to get in contact with senior mentors and faculty from around the world and for early career interventionalists to network with peers in their group from different countries.

**KS:** Can you tell us more about the application process?

**GB:** We want the participants to have completed their CHD interventional training within the past five years or less. There will be no tuition charge or other fees for applicants and enrollees, and the applicants will submit a CV, a recommendation letter, and a completed application form.

**KS:** What is the timeline for launching the Early Career Development Academy?

**AA:** The plan is to get started with the applications process in the first quarter of 2024!

**KS:** Thank you both so much for your time! This sounds like an amazing opportunity that will undoubtedly attract interest from early career interventionalists worldwide!



## Announcing the PICS Early Career Development Academy

### OVERVIEW OF THE ACADEMY

The PICS Early Career Development Academy will advance professional development of early career pediatric/congenital interventional cardiologists globally. The Academy is an innovative global two-year program blending mentor supervision and team-based learning. This new program meets a need expressed by training directors for such a program following completion of formal training programs (or equivalent according to local training pathways and board committee evaluation).

### WHO SHOULD APPLY?

If you trained as a pediatric/congenital interventional cardiologist and completed formal training within the past 5 years, this program has been designed for you.

### HOW IS THE ACADEMY STRUCTURED?

- Hybrid program: online & in-person
- Didactic instruction plus team activities
- 25 early career physicians to be selected
- 70 faculty from centers worldwide
- 5 teams: 5 participants and 1 mentor per team. Participants from around the globe
- Program Directors: Drs. Gianfranco Butera & Aimee Armstrong
- Each team will be assigned a 2-year research project
- Mentors: Drs. Lee Benson, Mario Carminati, John Cheatham, Ziyad Hijazi, & Sir Shakeel Qureshi
- Two challenges: interim review paper & final case presentation
- Winning team declared at end; recognition of all participating early career physicians

Didactic content will cover clinical topics, resilience during difficult situations, team building, medical reasoning, research methodology, industry relationships and much more.

**APPLY TODAY:** at [CHDinterventions.org](https://CHDinterventions.org) or email, [info@CHDinterventions.org](mailto:info@CHDinterventions.org)



PICS Society



# SAVE THE DATE SAN DIEGO

MARRIOTT MARQUIS – SAN DIEGO MARINA  
SEPTEMBER 4–7, 2024





# UltraNav System Enables Safer and More Cost-Effective Transseptal Procedures by Aligning Catheter and Ultrasound

*Novel Platform for Structural Heart Interventions Now in Human Use, With the Ability to Improve Patient Recovery and Reduce Anesthesia and Hospital Stays*



The Dib UltraNav Transseptal Catheter System, which houses a needle and ultrasound in one system for use in atrial transseptal procedures and delivery of catheters, has now been successfully used in 15 human cases, at major cardiology hospitals in Arizona and Minnesota.

UltraNav improves the safety and accuracy of transseptal procedures by enabling better visualization of the catheter, needle, and needle tip. It facilitates safer and more predictable transport of intracardiac echocardiography (ICE) and other catheters/wires from the right into the left atrium of the heart. Its use also suggests it may reduce the need for Transesophageal Echo (TEE) interventions.

UltraNav replaces the current procedural approach of using a separate needle and ultrasound beam on two different planes, which provides only a partial image of the orientation and depth of the needle and its tip, further disrupted by the cardiac and respiratory motion of the patient. Because UltraNav is a single system that aligns the catheter/needle with the ultrasound beam on the same plane, it provides more precise, continuous, and complete visualization for the clinician. Improved visualization reduces complications and increases catheter alignment during transseptal procedures.

Clinical experience to date indicates that UltraNav may also reduce recovery time in certain procedures because it only requires moderate sedation, not general anesthesia. This has resulted in the elimination of hospital stays and allowed patients to return home in a matter of hours, which reduces scheduling challenges that exist with procedures using TEE and can lead to substantial reductions in overall cost.

“There’s been a significant rise in structural transseptal heart procedures, which mandates the need for a safer, more accurate approach,” said Dr. Nabil Dib, founder of Dib UltraNav Medical and inventor of the UltraNav Transseptal Catheter System. “Although the current risks may be low, complications can be fatal. Reducing serious complications such as heart perforation and reducing the need for anesthesia with a novel one-catheter system will change the way we approach structural heart interventions, reduce the learning curve for physicians, and expand the treatment to more patients.”

Dr. Dib will present “A Double Lumen Catheter to Facilitate Atrial Septal Procedure and the Transseptal Delivery of Catheters: Dib UltraNav Transseptal Catheter System/Catheter-Based Treatment of Congenital Heart Disease:

ASD, PFO, and RVOT Obstruction II” on Oct. 24, at 10:09am PST, at the Transcatheter Cardiovascular Therapeutics (TCT) conference in San Francisco, in the Moderated Abstracts Station 2 Emerging Clinical Science & Research, Hall A, Exhibition Level, Moscone South, Moscone Center.

The single-use, dual-lumen, non-steerable Dib UltraNav System intravascular catheter and handle received FDA 510(k) clearance in March 2022. It is compatible with frequently used needles, RF wires, and various ICE catheters. It has a broad indication for use for puncture of the septum and transport of ICE catheters to the left atrium and is applicable for any septal or left heart procedures, including appendage closure procedures, valve interventions, and catheter-based ablation.





# Edwards Evoque Transcatheter Tricuspid Valve Replacement System Receives CE Mark

Edwards Lifesciences Corporation (NYSE: EW) announced the company's EVOQUE tricuspid valve replacement system received the CE Mark for the transcatheter treatment of eligible patients with tricuspid regurgitation (TR). The EVOQUE system is the world's first transcatheter valve replacement therapy to receive regulatory approval to treat TR.

"Innovating for unmet patient needs is at the center of everything we do at Edwards, which makes us especially proud to have received CE Mark for this first-of-its-kind transcatheter tricuspid valve replacement therapy," said Daveen Chopra, Edwards' corporate vice president, transcatheter mitral and tricuspid therapies. "With the EVOQUE system's approval, in addition to our current PASCAL tricuspid system, we are now able to provide a broader array of much-needed treatment options for appropriate tricuspid disease patients in Europe."

The EVOQUE system is comprised of a nitinol self-expanding frame, intra-annular sealing skirt, and tissue leaflets made from the same bovine pericardial tissue as the company's market-leading heart valves. The EVOQUE valve will be available in three sizes, all delivered through a low-profile transfemoral 28F system.

"The EVOQUE system is able to fully replace the tricuspid valve, virtually eliminating tricuspid regurgitation in a wide range of anatomies," said Prof. Philipp Lurz, Director of Cardiology, University of Mainz, Germany and European Principal Investigator for the TRISCEND II study. "The significant improvements in patients' quality-of-life are remarkable, now offering a therapy to many patients who previously had no treatment options."

One-year results on patients treated in the single-arm, prospective, global, multi-center TRISCEND study of the EVOQUE system were presented at PCR London Valves 2022 and demonstrated favorable safety and effectiveness outcomes and significant quality-of-life improvements. Key findings included high survival (90.1%) and high freedom from heart failure hospitalization (88.4%); significant and sustained TR reduction to mild or trace TR (97.6%); and significantly improved functional and quality-of-life outcomes (93% of patients in NYHA Class I or II compared to 26% at baseline and a 26-point increase in KCCQ score over baseline).

The company will present results from the TRISCEND II pivotal trial, studying the EVOQUE system, during a late-breaking clinical trial session on Oct. 26 in San Francisco at the 35th Transcatheter Cardiovascular Therapeutics (TCT), the annual scientific symposium of the Cardiovascular Research Foundation.

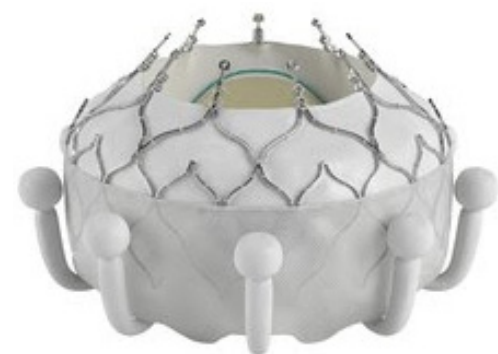Patients with tricuspid valve disease suffer greatly with symptoms ranging from debilitating to life-threatening with few effective options for relief. Other transcatheter therapies in Edwards' tricuspid portfolio with CE Mark approval include the PASCAL Precision transcatheter repair system and the Cardioband annular reduction system. The company does not yet have any transcatheter therapies approved for treatment of the tricuspid valve in the United States.

## About Edwards Lifesciences

Edwards Lifesciences is the global leader of patient-focused innovations for structural heart disease and critical care



# Edwards



monitoring. We are driven by a passion for patients, dedicated to improving and enhancing lives through partnerships with clinicians and stakeholders across the global healthcare landscape. For more information, visit [Edwards.com](https://www.edwards.com) and follow us on Facebook, Instagram, LinkedIn, X and YouTube.





# Celebrating Dr. Gary Webb

Dear Reader,

It is with a heavy heart that I remember my partner in life, Gary, at the second anniversary of his passing . For 41 years, I was fortunate enough to witness his remarkable force, drive, tenacity, intellect, compassion, curiosity, sense of humor, belly laugh, sense of mischief, vision, and love of life.

For his family, he is in every rainbow, every heart shape, every photo ( and there are thousands!). We hear him in the music we shared and in the gentle breeze that whispers through the trees.

At the second anniversary of his death, I have been reflecting on his legacy, and a huge part of that legacy is The CHiP Network. ACHD was Gary's professional passion since I first knew him in 1980.

His vision always had the patients at the very core of who he was and everything he did. His purpose was to allow health care providers globally to be able to share the needed knowledge and experience to best care for these precious patients. Gary believed that the global ACHD community was greater than the sum of its parts.

When Gary died, I heard many stories about how much he loved his family and how he would answer his phone to speak to us whenever any one of us called. The funny thing that patients and colleagues didn't realize was that he would do the same for each of you and for any of his patients when he was at home. He would pick up the call anytime you called. Thanksgiving, birthday dinners, Saturday nights... nothing was off limits. You needed to speak with him, he would be there. Gary met so many incredible people in his ACHD journey. Each of you was important to him personally and professionally. He would share with me his delight in your successes and his sadness in your sorrows. We bore witness to the breadth and depth of his love and commitment to the ACHD community and the individuals who cared so well for the patients at the centre of his universe.

CHiP was so incredibly important to Gary. He felt it was the embodiment of his vision around global congenital heart disease. The memory of CHiP for me is truly bittersweet because I know how Gary struggled to stay involved, to ensure it succeeded into the future. His dedication and determination here was stronger than the significant effects of his tumor, his chemotherapy and his radiation therapy. I would get him into his wheelchair



and take him to the kitchen table where he would struggle to navigate his computer to join the calls and participate even as his lost his voice. He fought so very hard to ensure that CHiP thrived after his death. We are all so incredibly grateful to Varun and you all, a truly inspirational group of people who have worked to ensure the success and continued growth of CHiP. Gary thanks you from the bottom of his heart!

While he lives on through the work you all do, I want to leave you with two of Gary's mantras that are a part of our daily lives. "Be good to yourself, Be good to others." "Work hard, Play hard."

**Anne Phillips, MD, FRCPC (Dr. Gary Webb's wife)**

We are grateful for your kind help, support, and wishes as we continue Dr. Webb's mission. Your support is instrumental in helping us achieve our goals and make a positive impact. We look forward to working alongside you and encourage you to share any comments, feedback, or questions you may have. Thank you again for your unwavering support and dedication to our cause.

**On behalf of the CHiP Network,  
Varun Aggarwal, MD  
President & Editor-in-Chief**

To donate, please visit: [https://www.paypal.com/donate/?hosted\\_button\\_id=MV73TB5AMHW3C](https://www.paypal.com/donate/?hosted_button_id=MV73TB5AMHW3C)





## FEBRUARY

22<sup>ND</sup>-24<sup>TH</sup>

**Innovations in Heart Valve Reconstruction:  
A Master Class - 8th Annual Advances in Congenital  
Heart Disease Summit**

Lake Buena Vista, Florida, USA

<https://www.clevelandclinicmeded.com/live/courses/congenital/>

## APRIL

06<sup>TH</sup>-08<sup>TH</sup>

**ACC.24**

Atlanta, Georgia, USA

[https://accscientificsession.acc.org/Registration-and-Hotels/Registration-Rates-and-Dates?utm\\_source=direct&utm\\_medium=email&utm\\_content=A24085&utm\\_campaign=acc24](https://accscientificsession.acc.org/Registration-and-Hotels/Registration-Rates-and-Dates?utm_source=direct&utm_medium=email&utm_content=A24085&utm_campaign=acc24)

17<sup>TH</sup>-20<sup>TH</sup>

**PICS-IPC Istanbul 2024**

Istanbul, Turkey

<https://picsistanbul.com/en>

# Program Directory 2023-2024

*Published Mid-August*

**Directory of Congenital & Pediatric  
Cardiac Care Providers in North  
America**

**Contact information at each program  
for Chief of Pediatric Cardiology &  
Fellowship Director**

**Lists each program's  
Pediatric Cardiologists &  
Cardiothoracic Surgeons**

**Lists Pediatric Cardiology  
Fellowships**

**Distributed to  
Division Chiefs by mail**

**Electronic version available on  
CCT's website:**

**[CongenitalCardiologyToday.com/  
Program-Directory](https://www.CongenitalCardiologyToday.com/Program-Directory)**

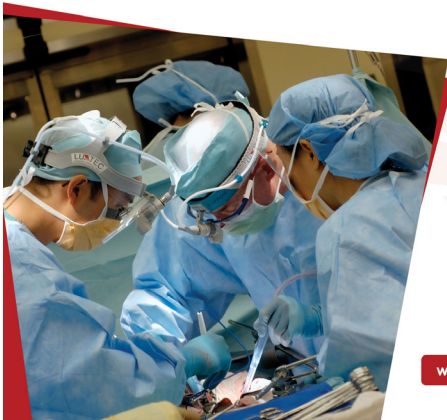**Need to update your listing?**

**Contact Kate Baldwin**

**[kate.f.baldwin@gmail.com](mailto:kate.f.baldwin@gmail.com)**



**CONGENITAL CARDIOLOGY TODAY**  
Timely News & Information for Congenital/Structural Cardiologists & Cardiothoracic Surgeons Worldwide



### Recruitment Advertising

- ✓ In print and electronic monthly issue
- ✓ On our website
- ✓ In monthly Email Blast
- ✓ No cost for CCT to create the ad
- ✓ Multiple sizes available



Subscribe Electronically  
Free on Home Page

[www.CongenitalCardiologyToday.com](http://www.CongenitalCardiologyToday.com)



# Pediatric Interventional Cardiologist

## Division of Pediatric Cardiology, Department of Pediatrics

### University of Utah School of Medicine

This is an outstanding opportunity to join a vibrant and collegial academic environment and work in a children's hospital ranked as one of the best in the U.S. The Division of Pediatric Cardiology at the Spencer Fox Eccles School of Medicine is seeking a Pediatric Cardiologist with subspecialty training and interest in Interventional Cardiology. The clinical focus will be caring for patients with congenital heart disease needing cardiac catheterization for diagnosis and management. Interventional cath procedures performed include balloon atrial septostomy, balloon valvuloplasty, balloon angioplasty, stent placement, coil and device occlusion of abnormal vessels, device closure of septal defects, transcatheter valve replacement (aortic, mitral, pulmonic, tricuspid), post-transplant evaluation including coronary angiography and endomyocardial biopsy, and hybrid procedures including perventricular VSD closure, hybrid stage I palliation for patients with HLHS, transapical pulmonary valve replacement, etc. The successful candidate will join 3 other interventional cardiologists in covering the cath lab for scheduled and after-hours emergent cases. Division members rotate in covering general pediatric cardiology night and weekend call. Clinical responsibilities will include covering patients on the inpatient service (rotating) and seeing patients in an outpatient clinic (weekly). In addition to clinical service, there is both opportunity and expectation for academic work, including education, investigation/research, and administration, as well as advocacy. There will be protected time for these efforts with a well-established support structure, expected benchmarks, and both breadth and depth in mentoring available within the Division.

The interventional team consists of 3 pediatric interventional cardiologists, a dedicated nurse practitioner, and experienced cath lab personnel. The Division has a very busy catheterization program (800 cases last year), and works closely with cardiothoracic surgery, cardiac intensive care, and cardiac anesthesia to coordinate care. The Division is part of Primary Children's Heart Center which receives referrals from Utah and surrounding states; 4 surgeons perform approximately 600 surgeries per year with outstanding outcomes. Most clinical services are delivered at Primary Children's Hospital which includes a 16-bed dedicated cardiac ICU, 2 dedicated cath labs, and a new ambulatory facility which houses our outpatient services.

Qualified candidates must be Board Eligible/Board Certified in Pediatric Cardiology with subspecialty training and expertise in Interventional Cardiology. The selected candidate will receive a faculty appointment in the Department of Pediatrics on the Clinical or Tenure Track at the academic level commensurate with experience and qualifications.

The Department and University offers a competitive salary and unmatched benefits program including non-contributory retirement contributions of 20.2% of annual salary that vest immediately. The Department offers a faculty development and mentoring program designed to foster success in translational or basic research, quality improvement engagement, and excellence as educators.

Salt Lake City is a rapidly growing, vibrant city in the Intermountain West, with a nationally recognized Broadway theater, ballet, symphony, and several professional sports teams. The Salt Lake International Airport is a hub for Delta Airlines and has direct flights to many North American cities and daily direct flights to multiple European cities. Outdoor activities are unparalleled: the city is a ski destination and a gateway to the state's renowned red rock landscapes. In addition to its 14 ski resorts, Utah boasts five national parks (with five more within a half-day's drive), a variety of golf courses allowing for year-round play, hundreds of miles of hiking and biking trails, picturesque lakes, and numerous other outdoor activities.

**Interested individuals can apply for the position at <https://utah.peopleadmin.com/postings/156909>.**

**Cover letter and curriculum vitae are required. For additional information about the position, please contact: Robert G. Gray, MD, Director of the Pediatric Cardiology Catheterization Lab, [robert.gray@utah.edu](mailto:robert.gray@utah.edu).**

*The University of Utah Health (U of U Health) is a patient focused center distinguished by collaboration, excellence, leadership, and respect. The U of U Health values candidates who are committed to fostering and furthering the culture of compassion, collaboration, innovation, accountability, diversity, integrity, quality, and trust that is integral to our mission.*

*The University of Utah values candidates who have experience working in settings with students, staff, faculty and patients from diverse backgrounds and possess a strong commitment to improving access to higher education, employment opportunities, and quality healthcare for historically underrepresented groups.*

*Individuals from historically underrepresented groups, such as minorities, women, qualified persons with disabilities and protected veterans are encouraged to apply. Veterans' preference is extended to qualified applicants, upon request and consistent with University policy and Utah state law. Upon request, reasonable accommodations in the application process will be provided to individuals with disabilities.*

*The University of Utah is an Affirmative Action/Equal Opportunity employer and does not discriminate based upon race, ethnicity, color, religion, national origin, age, disability, sex, sexual orientation, gender, gender identity, gender expression, pregnancy, pregnancy-related conditions, genetic information, or protected veteran's status. The University does not discriminate on the basis of sex in the education program or activity that it operates, as required by Title IX and 34 CFR part 106. The requirement not to discriminate in education programs or activities extends to admission and employment. Inquiries about the application of Title IX and its regulations may be referred to the Title IX Coordinator, to the Department of Education, Office for Civil Rights, or both.*





## CORPORATE TEAM

**PUBLISHER &  
EDITOR-IN-CHIEF**

Kate Baldwin  
*kate.f.baldwin@gmail.com*

**CO-FOUNDER &  
MEDICAL EDITOR**

John W. Moore, MD, MPH  
*jwmmoore1950@gmail.com*

**FOUNDER &  
SENIOR EDITOR**

Tony Carlson  
*tcarlsonmd@gmail.com*

**STAFF EDITOR &  
WRITER**

Virginia Dematatis

**EDITOR-IN-CHIEF  
EMERITUS**

Richard Koulbanis

**STAFF EDITOR**

Loraine Watts

## EDITORIAL BOARD

Aimee K. Armstrong, MD  
Jacek Bialkowski, MD  
Anthony C. Chang, MD, MBA  
Howaida El-Said, MD, PhD  
Ziyad M. Hijazi, MD, MPH  
John Lamberti, MD  
Tarek S. Momenah, MBBS, DCH

John W. Moore, MD, MPH  
Shakeel A. Qureshi, MD  
P. Syamasundar Rao, MD  
Carlos E. Ruiz, MD, PhD  
Hideshi Tomita, MD  
Sara M. Trucco, MD  
Gil Wernovsky, MD

## OFFICIAL NEWS & INFORMATION PARTNER OF

