CONGENITAL CARDIOLOGY TODAY
Timely News & Information for Congenital/Structural Cardiologists & Cardiothoracic Surgeons Worldwide

International Edition
Vol. 21 - Issue 4

April 2023

Table of Contents

Utility of 3D and Real Time 3D Transesophageal (TEE) Echocardiography in Pediatric Interventional Suite Decision Making for Atrial Septal Defect (ASD) Closures – A Case Series

Umang Gupta, MD, MBA

Keywords: 3D echocardiography, Congenital Heart Disease, device closure, Atrial Septal Defect

Introduction

While the role of 3D imaging has been identified for structural and congenital cardiac defects, its implementation has been very slow. This is likely related to lack of specific training, limitations of appropriate software on the cart and time intensive processing of more complex lesions. With advancement in probe technology and software quality, there has been a renewed interest to utilize it in real time during procedures in pediatric patients with structural and congenital heart disease. This is likely to be boosted by recent availability of a pediatric 3D TEE probe. In our experience we have found 3D echocardiography imaging to provide valuable and unique information that complements 2D imaging information and helps in decision making.

In this report we describe a series of two such cases where we found that the 3D and real time 3D imaging provided additional information that was not available through 2D Imaging. In each of these cases the additional information impacted the decision making and management. The images were obtained using Philips IE 33 machine with X8-2t ultrasound probe. The modalities used were real time 3D and zoom features and processed on the cart before acquisition.

Case Presentation

Case 1

The first case we describe is of an 18-year-old woman who initially presented to Cardiology clinic for shortness of breath and chest pain. As a part of her workup, a transthoracic echocardiogram was obtained that showed the presence of large Atrial Septal Defect (ASD). Due to limitations of the windows, however, the margins of the ASD could not be clearly delineated. She was referred for TEE with 3D imaging to further delineate the anatomy of the defect and for device closure, if amenable. With this goal, she was brought to the Pediatric Cath lab for the TEE and the lab was prepared to perform device closure if deemed suitable for it.

The TEE obtained confirmed the large defect, but also identified a markedly deficient inferior vena cava (IVC) rim, making it not amenable to device closure **(Figures 1-3)**. It also confirmed the absence of inferior sinus venous defect, and an encircling sliver of tissue was identified at the IVC margin **(Figure 1 & 2)**. With these findings, she was deemed not to be a candidate for device closure and was referred for surgery. The findings of the TEE were confirmed visually by the surgeons at the time of repair. After an uneventful postoperative course, the patient was discharged home.

APRIL 2023

International Edition Vol. 21 - Issue 4

TABLE OF CONTENTS

RIGHT CHOICE.

Melody™

Transcatheter Pulmonary Valve (TPV) System



Not intended to constitute medical advice or in any way replace the independent medical judgment of a trained and licensed physician with respect to any patient needs or circumstances. Melody TPV is not suitable for all patients and ease of use, outcomes, and performance may vary. See the Instructions for Use for indications, contraindications, precautions, warnings, and adverse events.

Restoring lives for

13

years and counting.

The only transcatheter pulmonary valve specifically designed for RVOT conduits and bioprosthetic valves. The longest studied transcatheter valve, with the largest body of clinical evidence at over 10 years.* More than 16,000 patients' lives have been changed over 13 years, and counting.

Melody TPV — The Right Choice for Your Patients

*Melody Transcatheter Pulmonary Valve Study: Post Approval Study of the Original IDE Cohort.

UC201809495b EN 11/2020

Medtronic
Further, Together

Important Labeling Information for the United States

Indications: The Melody TPV is indicated for use in the management of pediatric and adult patients who have a clinical indication for intervention on a dysfunctional right ventricular outflow tract (RVOT) conduit or surgical bioprosthetic pulmonary valve that has ≥ moderate regurgitation, and/or a mean RVOT gradient ≥ 35 mm Hg.

Contraindications: None known.

Warnings/Precautions/Side Effects

- **DO NOT implant in the aortic or mitral position. Pre-clinical bench testing of the Melody valve suggests that valve function and durability will be extremely limited when used in these locations.**
- DO NOT use if patient's anatomy precludes introduction of the valve, if the venous anatomy cannot accommodate a 22 Fr size introducer, or if there is significant obstruction of the central veins.
- DO NOT use if there are clinical or biological signs of infection including active endocarditis. Standard medical and surgical care should be strongly considered in these circumstances.
- Assessment of the coronary artery anatomy for the risk of coronary artery compression should be performed in all patients prior to deployment of the TPV.
- To minimize the risk of conduit rupture, do not use a balloon with a diameter greater than 110% of the nominal diameter (original implant size) of the conduit for pre-dilation of the intended site of deployment, or for deployment of the TPV.
- The potential for stent fracture should be considered in all patients who undergo TPV placement. Radiographic assessment of the stent with chest radiography or fluoroscopy should be included in the routine postoperative evaluation of patients who receive a TPV.
- If a stent fracture is detected, continued monitoring of the stent should be performed in conjunction with clinically appropriate hemodynamic assessment. In patients with stent fracture and significant associated RVOT obstruction or regurgitation, reintervention should be considered in accordance with usual clinical practice.

Potential procedural complications that may result from implantation of the Melody device include the following: rupture of the RVOT conduit, compression of a coronary artery, perforation of a major blood vessel, embolization or migration of the device, perforation of a heart chamber, arrhythmias, allergic reaction to contrast media, cerebrovascular events (TIA, CVA), infection/sepsis, fever, hematoma, radiation-induced erythema, blistering, or peeling of skin, pain, swelling, or bruising at the catheterization site. Potential device-related adverse events that may occur following device implantation include the following: stent fracture,* stent fracture resulting in recurrent obstruction, endocarditis, embolization or migration of the device, valvular dysfunction (stenosis or regurgitation), paravalvular leak, valvular thrombosis, pulmonary thromboembolism, hemolysis.

*The term "stent fracture" refers to the fracturing of the Melody TPV. However, in subjects with multiple stents in the RVOT it is difficult to definitively attribute stent fractures to the Melody frame versus another stent.

For additional information, please refer to the Instructions for Use provided with the product or available on http://manuals.medtronic.com.

CAUTION: Federal law (USA) restricts this device to sale by or on the order of a physician.

Important Labeling Information for Geographies Outside of the United States

Indications: The Melody™ TPV is indicated for use in patients with the following clinical conditions:

- Patients with regurgitant prosthetic right ventricular outflow tract (RVOT) conduits or bioprostheses with a clinical indication for invasive or surgical intervention, OR
- Patients with stenotic prosthetic RVOT conduits or bioprostheses where the risk of worsening regurgitation is a relative contraindication to balloon dilatation or stenting

Contraindications

- Venous anatomy unable to accommodate a 22 Fr size introducer sheath
- Implantation of the TPV in the left heart
- RVOT unfavorable for good stent anchorage
- Severe RVOT obstruction, which cannot be dilated by balloon
- Obstruction of the central veins
- Clinical or biological signs of infection
- Active endocarditis
- Known allergy to aspirin or heparin
- Pregnancy

Potential Complications/Adverse Events: Potential procedural complications that may result from implantation of the Melody device include the following: rupture of the RVOT conduit, compression of a coronary artery, perforation of a major blood vessel, embolization or migration of the device, perforation of a heart chamber, arrhythmias, allergic reaction to contrast media, cerebrovascular events (TIA, CVA), infection/sepsis, fever, hematoma, radiation-induced erythema, pain, swelling or bruising at the catheterization site. Potential device-related adverse events that may occur following device implantation include the following: stent fracture.* stent fracture resulting in recurrent obstruction, endocarditis, embolization or migration of the device, valvular dysfunction (stenosis or regurgitation), paravalvular leak, valvular thrombosis, pulmonary thromboembolism, hemolysis.

*The term "stent fracture" refers to the fracturing of the Melody TPV. However, in subjects with multiple stents in the RVOT it is difficult to definitively attribute stent fractures to the Melody frame versus another stent.

For additional information, please refer to the Instructions for Use provided with the product or available on http://manuals.medtronic.com.

The Melody Transcatheter Pulmonary Valve and Ensemble II Transcatheter Delivery System has received CE Mark approval and is available for distribution in Europe.

medtronic.com

710 Medtronic Parkway
Minneapolis, MN 55432-5604
USA
Tel: (763) 514-4000
Fax: (763) 514-4879
Toll-free: (800) 328-2518

LifeLine
CardioVascular Technical Support
Tel: (877) 526-7890
Fax: (651) 367-0918
rs.structuralheart@medtronic.com

UC201809495b EN 11/2020

Medtronic

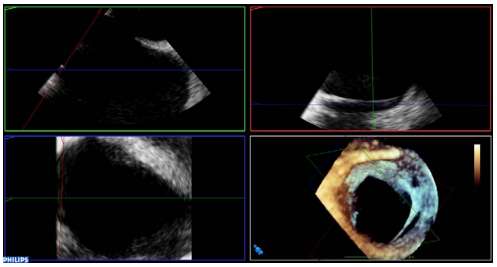

FIGURE 1 *Multiplanar reconstruction from 3D dataset acquired in 4 chamber view at mid esophageal level by TEE showing large atrial septal defect with deficient IVC rim. The blue plane shows the enface view of the large ASD and the red plane shows the IVC entering the right atrium and the thin rim separating it from ASD.*

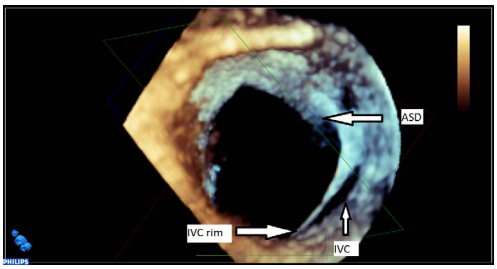

FIGURE 2 *Zoomed reconstructed 3D image showing the large ASD and deficient IVC rim. This is looking from the right atrium. IVC is seen entering the right atrium and no inferior sinus venosus defect seen. IVC= Inferior vena cava, ASD = Atrial septal defect.*

Case 2

The second case we describe is of a 15-year-old child who was initially referred for cardiac evaluation for a murmur. A transthoracic echocardiogram was done as a part of workup that revealed a moderate size ASD with left-to-right shunt and adequate margins. Hence, patient was referred for percutaneous device closure.

In the Cath lab, TEE was performed that confirmed the diagnosis as well as the adequacy of the margins **(Figure 4)**. Hence, the decision was made to proceed with device closure. TEE assistance was provided during the procedure to minimize the need for fluoroscopy. After the initial device deployment, the 2D TEE imaging continued to show a residual shunt near the aortic rim **(Figure 5)** and 2D imaging could not confirm the presence of the aortic rim between the discs of the device. To further delineate the position of the device, real time 3D

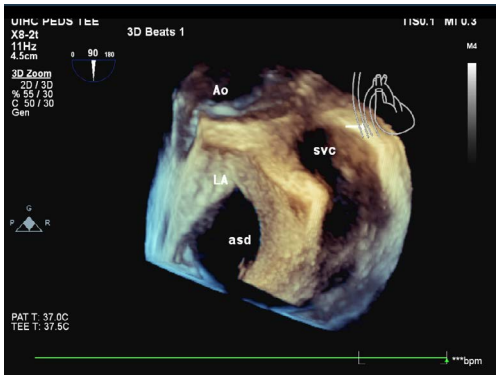

FIGURE 3 *Another zoomed reconstructed view of the ASD from the Left atrial side (LA) showing adequate aortic and SVC rims. Ao = aorta, SVC= superior vena cava, asd = Atrial septal defect.*

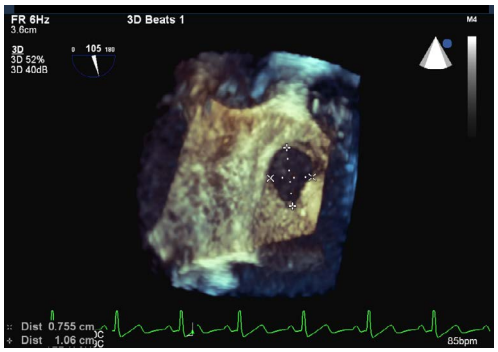

FIGURE 4 *Reconstructed 3D Zoom view of the atrial septal defect from the right atrial side with measurements.*

imaging was performed focusing on the aortic rim of the defect and position of the device relative to that. The additional imaging showed an appropriate and stable position of the device **(Figure 6)**. Hence decision to release it was made. After the release, the previously seen shunt disappeared and follow-up images showed a well-placed device confirming the 3D findings **(Figure 7 & 8)**. After an uneventful overnight stay the echo was repeated next day and on follow-up, and confirmation was made that the device was stable and well-placed with no residual shunts.

Discussion

Echocardiography, starting with the initial use of M mode and progressing through advances to current use of 2D, 3D and real time 3D imaging of heart, has led to dramatic improvements in cardiovascular medicine and has now become the workhorse of cardiac imaging.[1]

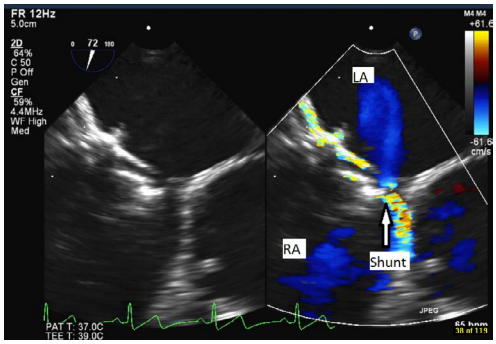

FIGURE 5 *Mid esophageal TEE view with probe rotated to 70 degrees showing ASD device in place but before release. Note the shunt at the aortic rim of the device. Aortic rim could not definitively be confirmed between the discs of the device on 2D-imaging.*

The first descriptions of its application came about in mid-1930's and the first clinical applications of M-mode echocardiography was introduced in 1950's. These initial applications were focused on the assessment of the mitral valve using the shapes of the corresponding waveforms. Subsequently, the various M-mode recordings were related to their anatomical origins. Contrast echocardiography, which was introduced in the 1960's, led to further progress in the understanding of the cardiovascular diseases. 2D imaging was first introduced in 1950's, getting established in 1960's. Around the same time, the TEE was introduced as a modality in late 1960's. The introduction of Pulse doppler imaging in the same decade further increased the tools that we had to investigate the heart. Combined together these innovations in imaging set the stage to leapfrog our understanding of diseases and manage them in ways that were not possible just a few decades ago.[2] The impact of echocardiography was commended on by Feigenbaum in his article in 1996.[3]

Around the same time that these capabilities were added to our investigative armamentarium, the idea of 3D echo was introduced with first 3D images reported in 1974.

Further advancement in echocardiography had two facets. On one end, we saw introduction of more sophisticated application of doppler imaging with introduction of tissue doppler in 1990's as well as speckle tracking and intracardiac

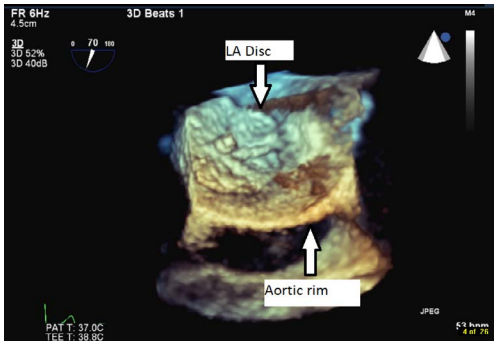

FIGURE 6 *The real time 3D Zoom image obtained from mid-esophageal view with probe rotation to about 70 degrees shows the device is well placed with aortic rim between the two discs of the ASD device.*

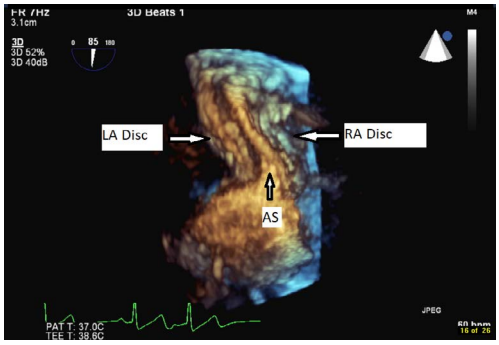

FIGURE 7 *The real time 3D Zoom image obtained at mid-esophageal level in bicaval plane (probe rotation to 90 degree) showing the device sitting well across the atrial septal defect after release.*

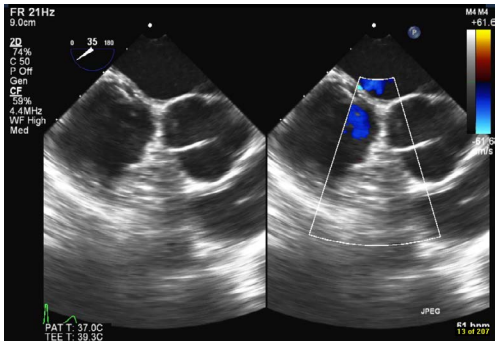

FIGURE 8 *Mid esophageal TEE view with probe rotation to 35 degrees showing no residual shunt at the atrial level after the device release.*

imaging.[4] On the other end, these modalities have been introduced to investigate diseases in pediatric patients and with more complex lesions.

Along with these developments, the hardware has also seen significant improvements over the last few decades. This has enabled its use to support interventional techniques for percutaneous treatment of structural heart defects[5] and other interventional procedures.[6] The role of 3D and 4D imaging has also been recognized in both structural / congenital and functional analysis.[7-11] Roberson and Cui were one of the first investigators who described the use of TEE for ASD closures and proposed protocols for it.[7] With expanding knowledge and need for standardization, EAE/ASE recommendations for image acquisition and display using three-dimensional echocardiography were published followed by similar consensus document for Congenital Heart Diseases.[8-11]

Our case series is an attempt to increase the experience in this direction, highlighting the usefulness of the 3D and 4D echo to provide additional clinically important information that cannot be gleaned by 2D imaging. We are confident this will provide motivation to those who are wishing and contemplating to start utilizing this modality in the pediatric population with congenital and structural heart disease. For those who are using it but sporadically, we hope this report will serve as a reminder to use it for decision making.

Fortunately, the development in echocardiography is complemented by developments in other modalities including cardiac CT and CMR imaging, though integration across platforms is lacking. A future goal should be to integrate multiple modalities to improve patient outcomes.

Conclusion

Since its humble beginning, the echocardiography has come a long way to become the mainstay of cardiac evaluation. The 3D imaging has further boosted its utility. However, because of significant limitations its adoption in investigating congenital and structural heart defects has been slow. But as our cases show, it is a valuable tool and in select cases provides information that cannot be obtained through 2D imaging. This information impacts management. Hence, its use should be considered in any scenario where the 2D imaging is not enough to provide the information.

References

1. Di Franco A, Ohmes LB, Gaudino M, et al. Serendipity and innovation: history and evolution of transthoracic echocardiography. Journal of thoracic disease. Apr 2017;9(Suppl 4):S257-s263. doi:10.21037/jtd.2017.03.90.
2. Edler I, Lindström K. The history of echocardiography. Ultrasound in medicine & biology. Dec 2004;30(12):1565-644. doi:10.1016/s0301-5629(99)00056-3.
3. Feigenbaum H. Evolution of echocardiography. Circulation. Apr 1 1996;93(7):1321-7. doi:10.1161/01.cir.93.7.1321
4. Maleki M, Esmaeilzadeh M. The evolutionary development of echocardiography. Iran J Med Sci. Dec 2012;37(4):222-32.
5. Balzer J, van Hall S, Böring Y-C, Kelm M. New Role of Echocardiography in the Cath Lab: Novel Approaches of Peri-Interventional 3D Echocardiography. Current Cardiovascular Imaging Reports. 2013/12/01 2013;6(6):445-453. doi:10.1007/s12410-013-9229-x.
6. Patrianakos AP, Zacharaki AA, Skalidis EI, Hamilos MI, Parthenakis FI, Vardas PE. The growing role of echocardiography in interventional cardiology: The present and the future. Hellenic J Cardiol. Jan - Feb 2017;58(1):17-31. doi:10.1016/j.hjc.2017.01.008.
7. Roberson DA, Cui VW. Three-dimensional transesophageal echocardiography of atrial septal defect device closure. Current cardiology reports. Feb 2014;16(2):453. doi:10.1007/s11886-013-0453-4.
8. Simpson J, Lopez L, Acar P, et al. Three-dimensional Echocardiography in Congenital Heart Disease: An Expert Consensus Document from the European Association of Cardiovascular Imaging and the American Society of Echocardiography. J Am Soc

Echocardiogr. Jan 2017;30(1):1-27. doi:10.1016/j.echo.2016.08.022.
9. Wu VC, Takeuchi M. Three-Dimensional Echocardiography: Current Status and Real-Life Applications. Acta Cardiol Sin. Mar 2017;33(2):107-118. doi:10.6515/acs20160818a.
10. Lang RM, Badano LP, Tsang W, et al. EAE/ASE recommendations for image acquisition and display using three-dimensional echocardiography. J Am Soc Echocardiogr. Jan 2012;25(1):3-46. doi:10.1016/j.echo.2011.11.010.
11. Hahn RT, Saric M, Faletra FF, et al. Recommended Standards for the Performance of Transesophageal Echocardiographic Screening for Structural Heart Intervention: From the American Society of Echocardiography. J Am Soc Echocardiogr. Jan 2022;35(1):1-76. doi:10.1016/j.echo.2021.07.006.

UMANG GUPTA, MD, MBA

Clinical Associate Professor
University of Iowa
Stead Family Children's Hospital
Iowa City, IA, USA
umang-gupta@uiowa.edu

The Other Vein That Stayed: Isolated Persistent Left Superior Vena Cava – A Case Report

Shivani Thacker, BA; Chandana Shekar, MD; Matthew Budoff, MD

Abstract

A Persistent Left Superior Vena Cava (PLSVC) is a rare congenital anomaly that results when the part of the left anterior cardinal vein caudal to the innominate vein fails to regress. The presence of a PLSVC is often incidentally found. It leads to difficulty accessing the right side of the heart through a left subclavian venous approach, which is the standard access for pacemaker or defibrillator placement. We report a case of PLSVC with an absent right Superior Vena Cava (SVC).

Learning Objective

Isolated PLSVC is a rare congenital anomaly which is typically asymptomatic and is most often discovered during central venous catheterization or pacemaker implantation. Cardiologists should consider the presence of a PLSVC when a catheter or guide wire inserted via the left subclavian approach makes an abnormal left-sided downward course. It must be confirmed with the use of imaging modalities like CTA which allows for accurate anatomical pictures. Once identified, the presence of a PLSVC should be well documented so that it can help overcome cardiac procedural challenges in the future.

Introduction

Though PLSVC is a rare vascular anomaly, it is the most common type of congenital malformation of the thoracic venous system. It affects 0.5-2% of the general population and 10% of patients with congenital cardiac malformations.[1] It results when the left superior cardinal vein caudal to the innominate vein fails to regress.[2] It is less frequent, however, to have a PLSVC with absent right SVC, which only occurs in 0.09-0.13% of the general population.[3] An isolated PLSVC is asymptomatic and is often incidentally found when it poses technical difficulties for vascular access via left cephalic or subclavian approach. Awareness of this anatomical anomaly is critical in minimizing the risks of potential complications during invasive cardiac procedures.

Case Presentation

A 70-year-old female with a history of previous myocardial infarction, chronic systolic heart failure (New York Heart Association Class II-III), type 2 diabetes mellitus, hypertension, and hyperlipidemia were evaluated for Cardiac Resynchronization Therapy-Defibrillator (CRT-D) placement. The procedure was attempted via left subclavian venous approach, and a micropuncture wire was inserted through the needle which had demonstrated venous blood flow. While advancing the micropuncture wire, it took a 90° angle to return to the hind aorta and the retrocardiac position, consistent with a PLSVC attached to the Coronary Sinus (CS). The procedure was aborted, and a Computed Tomography Angiogram (CTA) was done. CTA confirmed a PLSVC **(Figures 1-3)** and notably, no right RSVC was visualized. With this information, our patient later had the CRT-D successfully implanted via right axillary vein approach, with specially designed lead delivery catheters.

Discussion

Developmental Anomaly

Two pairs of cardinal veins, constituents of the embryological sinus venosus, constitute the primary source of embryonic systemic venous drainage. The anterior cardinal veins drain the cranial parts of the embryo, and the posterior cardinal veins drain the caudal parts. Both veins join to form the right and left common cardinal veins before entering the embryological heart. During the eighth week of fetal development, the innominate or left brachiocephalic vein connects the bilateral anterior cardinal veins. The caudal portions of the right anterior and right common cardinal vein form the right SVC. Part of the left anterior cardinal vein, caudal to the innominate vein regresses forming the ligament of Marshall. When this regression fails to happen, and the left anterior vein continues to drain the left brachiocephalic veins, a PLSVC results.[2] If the right anterior cardinal vein degenerates instead of forming the right SVC, blood from the right side is carried by the brachiocephalic vein to the PLSVC.4 PLSVC is associated with the absence of innominate vein in 65% of cases.[5]

Diagnosis

Multiple non-invasive modalities including chest X-ray, echocardiography, Computed Tomography Angiography (CTA) and Magnetic Resonance Venography (MRV) can be used in the diagnosis of PLSVC.[2] However, as most patients are asymptomatic, isolated PLSVC is most commonly detected when technical difficulties are faced accessing the right ventricle via a left-sided vascular approach.

As in our case, CTA is an excellent modality for the diagnosis of PLSVC as it not only allows for detecting PLSVC but also allows for visualization of the exact course or site of connection of PLSVC with the cardiac chambers. Though non-enhanced CT can also be used to diagnose PLSVC, CTA has a superior advantage, especially when dedicated protocols for optimum enhancement of the SVC and CS are used. Routine contrast-

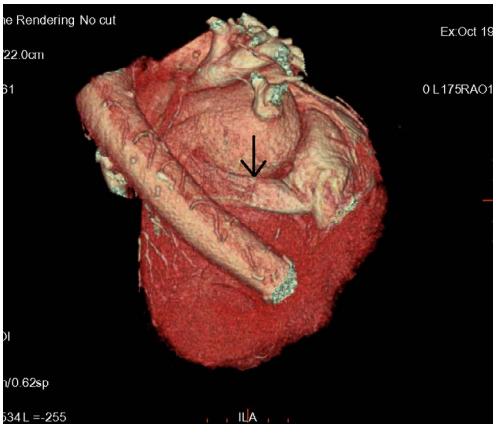

FIGURE 1 *CTA imaging showing PLSVC highlighted by the arrow*

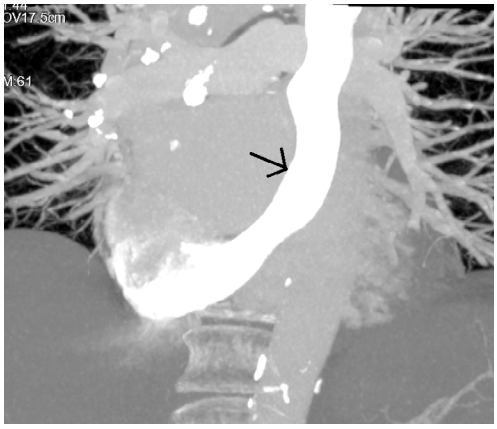

FIGURE 2 *CTA imaging showing PLSVC highlighted by the arrow*

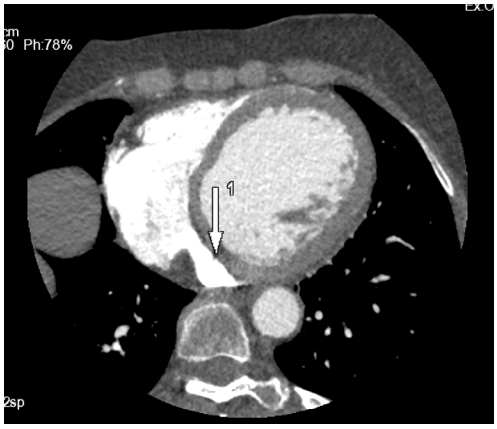

FIGURE 3 *CTA imaging showing PLSVC highlighted by the arrow*

enhanced ECG-gated cardiovascular CT performed three to five seconds after injecting the contrast agent into a peripheral vein, achieves excellent uniform enhancement of the SVC. Caudocranial image acquisition may be considered as the CS is inferiorly positioned. If multiphasic data are available, the systolic reconstruction phases (35%–45%) would also yield better coronary venous distention.[6]

Clinical Implications

As PLSVC is more common in patients with congenital cardiac malformations than in the general population, the presence of these anomalies should be looked for and appropriately addressed. Its association with atrial septal defects, bicuspid aortic valves or coarctation of the aorta in Turner syndrome, left isomerism of the heart, coronary sinus ostial atresia, tetralogy of Fallot, and several other malformations has been well-documented.[2,4]

PLSVC can pose challenges during trans-venous procedures such as right heart catheterization, pacemaker implantation, Implantable Cardioverter Defibrillator (ICD) placement, and biventricular pacing.[7] It can also complicate placement of central venous line and cardiopulmonary bypass in patients undergoing cardiac/thoracic surgery procedures.[8] In these patients, complications such as shock, cardiac arrest or angina can manifest as a result of catheter manipulation in the coronary sinus and injury to the vessel wall.[9,10] However, despite its anatomical changes, risks, and associated complications, PLSVC does not prevent successful pacemaker or ICD placement. Technical and technological advances have led to use of different approaches and specifically designed catheters for the necessary procedures in such cases.

Persistence of LSVC has also been described to cause small and poorly formed sinus node, fetal dispersion of the AV node and His bundle within the central fibrous body, small diameter of the His bundle, and poor arterial supply to either the AV node or the sinus node. This may predispose patients to arrhythmias and sudden death.[10]

Conclusion

Isolated PLSVC is a rare congenital anomaly which is typically asymptomatic and is most often discovered during central venous catheterization or pacemaker implantation. Cardiologists should consider the presence of a PLSVC when a catheter or guide wire inserted via the left subclavian approach makes an abnormal left-sided downward course. It must be confirmed with the use of imaging modalities like CTA which allows for accurate anatomical pictures, thus aiding the choice of invasive techniques needed for the procedure. Once identified, the presence of a PLSVC should be well-documented so that it can help overcome cardiac procedural challenges in the future.

Conflicts of interest: None

Patient Permission

The patient provided permission for her medical records to be used for the purpose of a case report.

References

1. Edwards JE, Du SJ, Alcott DL, et al. Thoracic venous anomalies. III. Atresia of the common pulmonary vein, the pulmonary veins draining wholly into the superior vena cava. AMA Arch Pathol. 1951 Apr;51(4):446-60. PubMed PMID: 14810335.
2. Ratliff HL, Yousufuddin M, Lieving WR, et al. Persistent left superior vena cava: case reports and clinical implications. Int J Cardiol. 2006 Nov 10;113(2):242-6. doi: 10.1016/j.ijcard.2005.08.067. PubMed PMID: 16318881; eng.
3. Soward A, ten Cate F, Fioretti P, et al. An elusive persistent left superior vena cava draining into left atrium. Cardiology. 1986;73(6):368-71. doi: 10.1159/000174030. PubMed PMID: 3791336.
4. Sheikh AS, Mazhar S. Persistent left superior vena cava with absent right superior vena cava: review of the literature and clinical implications. Echocardiography (Mount Kisco, NY).

2014 May;31(5):674-9. doi: 10.1111/echo.12514. PubMed PMID: 24460570; eng.
5. Elumalai G. "LEFT SUPERIOR VENA CAVA" EMBRYOLOGICAL BASIS AND ITS CLINICAL SIGNIFICANCE. Vol. 100. 2016.
6. Shah SS, Teague SD, Lu JC, et al. Imaging of the coronary sinus: normal anatomy and congenital abnormalities. Radiographics. 2012 Jul-Aug;32(4):991-1008. doi: 10.1148/rg.324105220. PubMed PMID: 22786990; eng.
7. Danielpour PJ, Aalberg JK, El-Ramey M, et al. Persistent left superior vena cava: an incidental finding during central venous catheterization-a case report. Vasc Endovascular Surg. 2005 Jan-Feb;39(1):109-11. doi: 10.1177/153857440503900111. PubMed PMID: 15696254.
8. Rubenfire M, Evangelista J, Wajszczuk WJ, et al. Implication of a persistent left superior vena cava in transvenous pacemaker therapy and cardiac hemodynamic monitoring. Chest. 1974 Feb;65(2):145-7. PubMed PMID: 4810672; eng.
9. Huang SK. Persistent left superior vena cava in a man with ventricular fibrillation. Chest. 1986 Jan;89(1):155-7. PubMed PMID: 3940779.
10. Schummer W, Schummer C, Frober R. Persistent left superior vena cava and central venous catheter position: clinical impact illustrated by four cases. Surg Radiol Anat. 2003 Jul-Aug;25(3-4):315-21. doi: 10.1007/s00276-003-0138-6. PubMed PMID: 12898196.

SHIVANI THACKER, BA

Medical Student
Western University of Health Sciences
Pomona, CA, USA
562.335.7342
Thackershivani7@gmail.com

CHANDANA SHEKAR, MD

Cardiologist
Portneuf Medical Center
Pocatello, ID, USA

MATTHEW BUDOFF, MD

Professor of Medicine, UCLA
Endowed Chair of Preventive Cardiology
Lundquist Institute
1124 W Carson St
Torrance, CA, USA

MAY

18-20

SCAI 2023 Scientific Sessions
Phoenix, AZ, USA
https://scai.org/scai-2023-scientific-sessions

JUNE

23-26

ASE 2023 – Foundations and the Future of Cardiovascular Ultrasound
National Harbor, MD, USA
https://www.asescientificsessions.org/

28-1

CSI Frankfurt
Frankfurt, Germany
https://www.csi-congress.org/conferences-courses/conferences/csi-frankfurt

JULY

28-29

CICT 2023 – CICT Controversies in Interventional Cardiovascular Therapies
Pasadena, CA, USA
https://cictsymposium.com/

AUGUST

27-01

8th World Congress of Pediatric Cardiology and Cardiac Surgery
Washington, DC, USA
http://wcpccs2023.org/

Coming Soon from IAC ...

Adult Congenital Transthoracic Echocardiography Accreditation

Recognizing the critical role of facilities providing care to patients with congenital heart disease who transition their care from pediatric cardiology to adult cardiology services, **IAC is pleased to announce the upcoming availability of a new accreditation testing area, Adult Congenital Transthoracic Echocardiography**.

The *IAC Standards & Guidelines for Adult Congenital Transthoracic Echocardiography* have been established to provide guidance in training and experience, protocol development and resources needed to perform and interpret echocardiograms on patients with complex, congenital heart disease. By achieving IAC accreditation, facilities will demonstrate their commitment to high quality, specialized diagnostic imaging, to patients and referring physicians.

IAC Echocardiography is widely respected in the field of echocardiography as illustrated by the support of national medical societies who each serve as a sponsoring organization, including the **Adult Congenital Heart Association (ACHA)**.

"As a long standing member of the medical advisory board of the Adult Congenital Heart Association (ACHA), I am excited to see the new Adult Congenital Transthoracic accreditation guidelines. This is another great step forward to help ensure that adult congenital heart disease patients across the country have access to high standard, accessible, comprehensive imaging."

- Michael G. Earing, MD, MS Healthcare Management

Member of IAC Echocardiography Board of Directors, Representing ACHA / Medical Director of the Chicago Adult Congenital Heart Disease Alliance

The new program will be available to applicant facilities later in 2022.

Stay informed! Sign up to receive program updates at **intersocietal.org/signup**.

Diagnostic Imaging Accreditation

Vascular Testing . Echocardiography
Nuclear/PET . MRI . CT / Dental CT

IAC

Vascular and Cardiac Intervention Accreditation

Carotid Stenting . Cardiac Electrophysiology
Vein Center . Cardiovascular Catheterization

Improving health care through accreditation® | **intersocietal.org** | 800.838.2110

"An Intellectual Feast" PICS LIVE 2023 and the 8th World Congress August 27th – September 1st, Washington, DC

The PICS Society Center for Continuing Education

Following last year's 25th Anniversary *PICS Symposium* in Chicago, this August we will start our next quarter-century with an even more special event: *PICS LIVE* will be held concurrently with the *World Congress of Pediatric Cardiology & Cardiac Surgery (WCPCCS)* in Washington, DC. Traditionally held every four years, the *World Congress* is a meeting of unparalleled depth, scope and size in pediatric cardiology/cardiac surgery. This year *PICS LIVE* will focus each morning with the live cases that *PICS* is renowned for, while enabling *PICS LIVE* attendees full access to the incredible programming of the entire *World Congress*.

We recently interviewed Drs. Ziyad M. Hijazi, MPH, FPICS (*PICS* President) and Damien Kenny, FPICS (*PICS Live* Chair and *PICS* Vice President) about plans for PICS Live. We also received invaluable information from the *WCPCCS* leadership. Highlights:

Is *PICS Live* in effect this year's version of the annual *PICS Symposium*?
Dr. Hijazi: Yes! The only major difference: This year we are doing it alongside the *World Congress,* so that those who come to Washington DC will have a "two for one" experience. Each morning attendees can attend our live cases; we call this *"PICS Live."* Each afternoon, attendees will attend any *World Congress* events they choose, whether those events focus on interventional treatment of CHD (which PICS faculty will be deeply involved with) or any of the dozens of other events offered daily. So in that sense this is a two-for-one week. That's why we call this an intellectual feast!

How do people register, submit abstracts, book hotel rooms, plan each day?
Dr. Kenny: We are working with the *World Congress* staff to make this all very user-friendly, focusing on "one-stop shopping." Simply go to **wcpccs2023.org** where you will find links for everything you need. Register for the *World Congress*, then for a modest additional fee on the registration page you can sign up for *PICS Live* as well—easily AND affordably! Even better: the total cost of both *PICS Live* and the *World Congress* is very similar to previous *PICS* meetings.

"The best of two worlds"
Dr. Hijazi: *PICS Live*, although an independent meeting designed by the PICS Society, will occur 8:00 am to 12:30 pm Monday through Thursday during the *World Congress*. The live cases will take place at the Marriott Marquis, footsteps from the Washington DC Convention Center. *PICS Live* attendees will enjoy continuous live case transmission from at least ten cardiac centers in the US, Europe, the Middle East, Asia and South America. Master operators will treat CHD conditions involving percutaneous valves, stent implantation devices, closure of septal defects, balloon angioplasty and other situations. As in previous years, panels at *PICS Live* will provide expert commentary, with time reserved for audience Q & A.

All afternoon sessions will be held in the Convention Center focusing on didactic sessions, seminars and workshops in our specialty, as well as opportunities for you to network - and learn - with our colleagues from many other fields. Sessions will cover: advanced imaging, nursing/ technologist science, heart failure, surgery, anesthesiology, adult CHD, intensive care, cardiovascular disease in the neonate and many other areas.
Dr. Kenny: The lynchpin of *PICS Live* will be live case demonstrations from around the world. Seeing how teams perform procedures provides an invaluable educational benefit. We will also have taped moderated cases with instructor/ attendee interaction. *PICS Live* will provide many hours of CME, very important for board certification or recertification and, of course, for one's own professional development.

Tell us more about this year's topics of special focus
Dr. Hijazi: We will cover interventions for CHD both in the live cases and in collaborative sessions with other societies in the Main Convention Center: septal defects (ASD closure, VSD closure, PDA closure), procedures for premature infants and fetal patients, adult CHD, advanced imaging, anesthesia, rheumatic fever, neonatology, hybrid surgical/interventional procedures, lymphatics and others. Advances in artificial intelligence and simulation technologies are of growing focus as well. The *PICS Society* will proudly collaborate with other societies such as the *International Society for Adult Congenital Heart Disease*, the *Congenital Cardiac Anesthesia Society*, the *Fetal Heart Society*, the *Neonatal Heart Society*, the *World Society for Pediatric and Congenital Heart Surgeons* and others.

Also this year we will have a session on quality, an extraordinarily important area. Everyone in our field knows the basics, so we will focus laser-like on quality in all of its aspects: outcomes, patient satisfaction, infection prevention, patient selection, guidelines-based care, interdisciplinary teamwork, and so much more. Dr. Ralf Holzer, who chairs the *PICS* Quality Improvement Committee, will lead a session on this vital topic. ***News flash:*** during the meeting, the *PICS Society* will also announce a major initiative in this area—details soon!

What additional programming will be offered?
Dr. Kenny: Advances in imaging are occurring daily. To help us keep up, Drs. Aimee Armstrong and Gregor Krings will again offer the 3Di3 Advanced Imaging program providing the latest 'news you can use' in this vital area. As mentioned earlier, there will be many events for our nursing and technologist colleagues, as well as programs for early career interventionalists. Drs. Vivian Dimas and Gareth Morgan will chair our two-day Fellows and Early Career Course (FECC), our highly popular program (apply early: space is limited). Additionally, the first-of-its-kind "Multidimensional Anatomy Lab" will be open throughout the meeting, ranging from traditional anatomic specimens, through angiography, echocardiography, 3D and 4D imaging, and virtual reality. This hands-on experience will provide an incredible opportunity for interventionalists to grasp the subtleties of anatomic variation in CHD.

Tell us about the venue itself
Dr. Hijazi: Washington, DC is an amazing international city for the entire family. DC is served by three international airports with scores of direct flights daily. As the capitol city of the U.S., you and your family can experience a week-long living history lesson, where you can visit the Smithsonian's huge collection of free museums (the largest on the planet), view Capitol Hill and the White House, and sample restaurants of all types. If you are visiting from outside the U.S., contact our staff to learn about policies for visiting your nation's embassy.

Opportunities to interact with industry partners
Dr. Kenny: *The World Congress'* exhibition hall will be huge! Industry will display the latest products and the tried-and- true. Everything will be on display, with those who developed these products available for discussion.

Industry demonstrations in the exhibit hall and expert presentations during industry symposia will focus on advances in imaging and new interventional devices.

This is crucial. CEO's and their representatives will be there to learn our needs. Take time to introduce yourself, interact, learn and avail yourself of opportunities for hands – on demonstrations. The relationship between industry and medical professionals is extremely important: We clinicians have the ideas about what we need to better treat patients. Industry has the engineers, the scientists and the resources to meet those needs.

Information & Dates to Remember

- *World Congress 2023*: August 27th – September 1st, Washington, DC
- *PICS Live*: August 28th – 31st
- Registration & accommodations for *PICS Live* and the *World Congress*: **wcpccs2023.org**
- *PICS Live* website: **CHDinterventions.org**
  - Abstracts: submit to **wcpccs2023.org**
  - Presentation formats: For consideration submit by May 15th
  - Posters: For consideration submit between May 16th – June 30th
- *PICS* 3Di3 Advanced Imaging Program: details at **CHDinterventions.org**
- *PICS* Fellows & Early Career Course: Apply at **CHDinterventions.org**

More About the World Congress

Traditionally held every four years, the *World Congress* is a large international meeting of unparalleled depth, scope and size, affectionately known as "The Olympics of our Profession." Inspired by the incredible precedent set by past *World Congress* organizers, our goal is to make this the most comprehensive, up-to-date, and technologically advanced meeting for Pediatric and Congenital Heart Disease.

In addition to the collaboration with *PICS*, the *WCPCCS* features:

- ~2300 Talks in ~170 Sessions, with ~1000 Faculty across 22 Tracks
  - Emphasis on diversity in faculty – geographic, gender, age and race
  - Besides PICS, 14 additional societies and post-graduate courses have cancelled their annual meeting and have embedded scientific content in the *World Congress*
  - Healthcare professionals from all disciplines can customize their learning experience based on their own needs
- 16 Featured Landmark Lectures
- ~1500 Abstracts of New Science will be Submitted from Around the World
  - Best Abstract Competition
- 17 different track winners, including *PICS**, will compete for the Best Abstract of the Congress
- Multi-dimensional Anatomy Lab – First of its kind
- Digital Futures Hub – First of its kind
- "Trainee and Early Career Track" Throughout the Meeting
- Global Health and Advocacy Village
  - A collection of over 125 NGOs and Patient/Parent Advocacy will share their Visions and Missions from around the world
  - Creation of Enduring Materials, White Papers, and Scientific Statements
- The *WCPCCS* has garnered International support from the *Association of European Cardiologists, Cardiac Society of Australia and New Zealand, Pediatric Cardiology Society of India*, and *Global Alliance for Rheumatic and Congenital Heart Disease*

*Abstracts should be submitted specifically for the Catheterization Track, and accepted abstracts will be presented as either oral or poster presentations. The winner of the "Best Catheterization Abstract" will also compete with the top abstracts of 16 other tracks for the Best Abstract of the 8th *World Congress* Award. For information regarding abstract submission, visit: **https://www.wcpccs2023.org/event/1da8563e-0f65-486c-88df-70c3db431af5/websitePage:839641f8-d609-4fea-8e22-bfa63439f918**

Organizations from across North America have come together to make this *World Congress* a momentous event. We are honored by the groundswell of support from these organizations. More than 60 children's hospitals across North America have joined the effort as Institutional Partners, plus over 50 international associations and related organizations have provided endorsements for this *World Congress*. See you in Washington, DC!

Preview of PDA Stenting in Cyanotic Newborns: Comprehensive Management Strategies from Fetus to Toddler – First Annual PDA Stenting Symposium

Howaida El Said, MD, PhD; Jeanne Carroll, MD; Brent Gordon, MD; David Werho, MD; Brian T. Allison, FACHE

It started with a dream carried through the years by many giants. First John Moore started the experiment in lambs in 1990,[1] then Gibbs had the courage to perform the procedure on a couple of infants in 1992.[2] It wasn't until coronary stent technology advanced that Alwi Mazni adapted it for infants in Malaysia that were unable to get a Blalock-Thomas-Taussig (BTT) shunt.[3] While surgical shunts were a breakthrough in establishing adequate pulmonary blood flow that allowed cyanotic infants to survive, the mortality associated with a BTT remains anywhere from 10-30%.[4] While that was tolerable when the mortality without surgery was 100%, it is less desirable in the current era of excellent outcomes and data transparency.

One building block after the other and here we are with many centers adopting it as the primary procedure and some performing ductal stenting for all cyanotic infants.[5] The procedure seems simple, but it is far from that. It is risky and tedious and deserves respect. An excellent procedure in the lab and you can have a baby eating the same day and home the next: one mistake and you may not have a survivor. The learning curve is steep, and one can never let their guard down.

Each PDA is unique. It may arise from the descending aorta, the innominate artery, or the under-surface of the arch. Access must be meticulously thought out. Femoral, carotid, axillary, or umbilical? Each has its time and place with pros and cons for each.[6] CT imaging and 3D modeling facilitate planning the procedure including stent length and vascular approach **(Figure 1)**.[7]

Who should have a PDA stent? Patients with dual-source or single sources of pulmonary blood flow? Single ventricle or two ventricles? Is one of the branch pulmonary arteries going to get isolated? Is the bronchus going to get compressed?[8-13]

Finally, sizing the PDA stent is an art. What diameter? What length? One stent or two? Many have adopted a philosophy of "better too long than too short" to avoid leaving the aortic or pulmonary artery end(s) uncovered. But then there are reports about injury of the back of the aorta if the stent is too long. Bioengineers are tirelessly working on helping us understand the mechanics and dynamics of the stent interaction with the protean PDA shape and size, but this remains one of the many challenges of the procedure.

After stent implantation, what is the post procedure course? Which anticoagulants are best? How should we monitor these patients at home? When should they have their next surgery? Should you re-dilate the stent? How do you remove the stent at the time of surgery and can the procedure be done off pump? What will the COMPASS trial teach us? Finally, will stenting improve neurodevelopmental outcomes?

So many questions and too many "answers"!?!?!

We felt that this very important procedure deserved its own meeting and cordially invite you to attend the inaugural PDA Stenting Symposium in San Diego, on April 20th-22nd, 2023. We have developed a collaborative, multidisciplinary Conference that has been carefully designed to provide an innovative and comprehensive overview of the latest developments and outcomes for PDA stenting in infants with cyanotic congenital heart disease. Many distinguished intensivists, neonatologists, cardiothoracic surgeons, developmental pediatricians, and cardiologists have joined the faculty and will take part in this conference, with the common goal to advance the field and reinforce lasting partnerships across specialties of those who care for these fragile and complex patients via lectures, case discussions, and taped cases.

The Conference will be hosted at the Loews Coronado, providing the ultimate opportunity for learning, sharing, networking and professional socializing while enjoying stunning views from its prime beachfront location. San Diego is world-renowned for its fantastic year-round climate, award-winning restaurants, and abundance of readily accessible outdoor activities. What better way to spend a long weekend than diving into PDA stenting and enjoying all that San Diego can offer in the Spring?

The Conference will be available in person and live Zoom. To register, please visit https://web.cvent.com/event/1df624a5-3218-4c2e-81e4-807df87f5471/summary

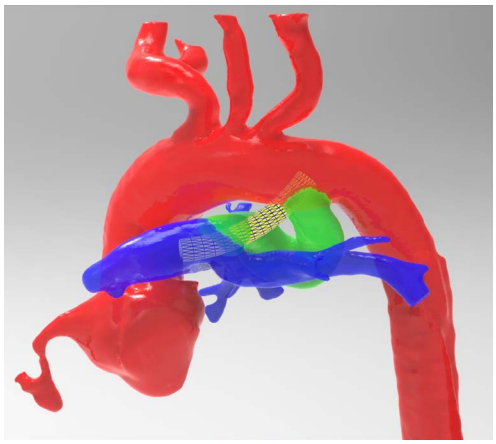

FIGURE 1 *3D reconstruction demonstrating simulation of PDA stent by the Helen and Will Webster Foundation 3D Innovations Lab at Rady Children's Hospital*

Scan or click to visit the PDA Stenting website

References

1. Moore JW, Kirby WC, Lovett EJ, O'Neill JT. Use of an intravascular endoprosthesis (stent) to establish and maintain short-term patency of the ductus arteriosus in newborn lambs. Cardiovasc Intervent Radiol. 1991 Sep-Oct;14(5):299-301. doi: 10.1007/BF02578454. PMID: 1933975.

2. Gibbs JL, Rothman MT, Rees MR, Parsons JM, Blackburn ME, Ruiz CE. Stenting of the arterial duct: a new approach to palliation for pulmonary atresia. Br Heart J. 1992; 67:240–245.
3. Alwi M, Choo KK, Latiff HA, Kandavello G, Samion H, Mulyadi MD. Initial results and medium-term follow-up of stent implantation of patent ductus arteriosus in duct-dependent pulmonary circulation. J Am Coll Cardiol. 2004 Jul 21;44(2):438-45.
4. Bentham JR, Zava NK, Harrison WJ, Shauq A, Kalantre A, Derrick G, Chen RH, Dhillon R, Taliotis D, Kang SL, Crossland D, Adesokan A, Hermuzi A, Kudumula V, Yong S, Noonan P, Hayes N, Stumper O, Thomson JDR. Duct Stenting Versus Modified Blalock-Taussig Shunt in Neonates With Duct-Dependent Pulmonary Blood Flow: Associations With Clinical Outcomes in a Multicenter National Study. Circulation. 2018 Feb 6;137(6):581-588.
5. Ratnayaka K, Nageotte SJ, Moore JW, Guyon PW, Bhandari K, Weber RL, Lee JW, You H, Griffin DA, Rao RP, Nigro JJ, El-Said HG. Patent Ductus Arteriosus Stenting for All Ductal-Dependent Cyanotic Infants: Waning Use of Blalock-Taussig Shunts. Circ Cardiovasc Interv. 2021 Mar;14(3):e009520. doi: 10.1161/CIRCINTERVENTIONS.120.009520. Epub 2021 Mar 9. PMID: 33685211.
6. Justino H, Petit CJ. Percutaneous Common Carotid Artery Access for Pediatric Interventional Cardiac Catheterization. Circ Cardiovasc Interv. 2016 Apr;9(4).
7. Jadhav SP, Aggarwal V, Masand PM, Diaz E, Zhang W, Qureshi AM. Correlation of ductus arteriosus length and morphology between computed tomographic angiography and catheter angiography and their relation to ductal stent length. Pediatr Radiol. 2020 May;50(6):800-809.
8. Shahanavaz S, Qureshi AM, Petit CJ, Goldstein BH, Glatz AC, Bauser-Heaton HD, McCracken CE, Kelleman MS, Law MA, Nicholson GT, Zampi JD, Pettus J, Meadows J. Factors Influencing Reintervention Following Ductal Artery Stent Implantation for Ductal-Dependent Pulmonary Blood Flow: Results From the Congenital Cardiac Research Collaborative. Circ Cardiovasc Interv. 2021 Dec;14(12).
9. Bauser-Heaton H, Qureshi AM, Goldstein BH, Glatz AC, Ligon RA, Gartenberg A, Aggarwal V, Shashidharan S, McCracken CE, Kelleman MS, Petit CJ. Comparison of Patent Ductus Arteriosus Stent and Blalock-Taussig Shunt as Palliation for Neonates with Sole Source Ductal-Dependent Pulmonary Blood Flow: Results from the Congenital Catheterization Research Collaborative. Pediatr Cardiol. 2022 Jan;43(1):121-131.
10. Bauser-Heaton H, Qureshi AM, Goldstein BH, Glatz AC, Nicholson GT, Meadows JJ, Depaolo JS, Aggarwal V, McCracken CE, Mossad EB, Wilson EC, Petit CJ. Use of carotid and axillary artery approach for stenting the patent ductus arteriosus in infants with ductal-dependent pulmonary blood flow: A multicenter study from the congenital catheterization research collaborative. Catheter Cardiovasc Interv. 2020 Mar 1;95(4):726-733.
11. Qureshi AM, Goldstein BH, Glatz AC, Agrawal H, Aggarwal V, Ligon RA, McCracken C, McDonnell A, Buckey TM, Whiteside W, Metcalf CM, Petit CJ. Classification scheme for ductal morphology in cyanotic patients with ductal dependent pulmonary blood flow and association with outcomes of patent ductus arteriosus stenting. Catheter Cardiovasc Interv. 2019 Apr 1;93(5):933-943.
12. Goldstein BH, O'Byrne ML, Petit CJ, Qureshi AM, Dai D, Griffis HM, France A, Kelleman MS, McCracken CE, Mascio CE, Shashidharan S, Ligon RA, Whiteside W, Wallen WJ, Agrawal H, Aggarwal V, Glatz AC. Differences in Cost of Care by Palliation Strategy for Infants With Ductal-Dependent Pulmonary Blood Flow. Circ Cardiovasc Interv. 2019 Apr;12(4).
13. Nicholson GT, Glatz AC, Qureshi AM, Petit CJ, Meadows JJ, McCracken C, Kelleman M, Bauser-Heaton H, Gartenberg AJ, Ligon RA, Aggarwal V, Kwakye DB, Goldstein BH. Impact of Palliation Strategy on Interstage Feeding and Somatic Growth for Infants With Ductal-Dependent Pulmonary Blood Flow: Results from the Congenital Catheterization Research Collaborative. J Am Heart Assoc. 2020 Jan 7;9(1).

HOWAIDA EL SAID, MD, PHD

Professor of Pediatric Cardiology
Course Director
Rady Children's Hospital San Diego
San Diego, CA, USA
helsaid@rchsd.org

JEANNE CARROLL, MD

Assistant Professor of Neonatology
Course Co-Director
Rady Children's Hospital San Diego
San Diego, CA, USA

BRENT GORDON, MD

Associate Professor of Pediatric Cardiology
Rady Children's Hospital San Diego
San Diego, CA, USA

DAVID WERHO, MD

Associate Professor of Pediatric Cardiology
Rady Children's Hospital San Diego
San Diego, CA, USA

BRIAN T. ALLISON, FACHE

Vice President
Heart Institute
Rady Children's Hospital San Diego
San Diego, CA, USA

An Overview of ACTION – The Advanced Cardiac Therapies Improving Outcomes Network

Angela Lorts, MD, MBA, Co-Executive Director ACTION & Lauren Smyth, MHA, Director, Operations, ACTION

The Need is Clear: Patients Need Better Care & Outcomes

Heart failure is a leading cause of death, heart transplantation and functional decline among children and adults with complex congenital and acquired forms of heart disease. More than 14,000 hospitalizations related to pediatric heart failure occur annually in the United States alone.[1]

Additionally, research for pediatric heart failure is underfunded, and cardiac devices and medicines are not developed specifically for children. Barriers to developing therapies for pediatrics include relatively small patient numbers, lack of economic incentive, burden of data collection, and suboptimal awareness of the problem. Heart failure care delivery in pediatrics also varies greatly, and patients experience a wide range of outcomes depending on where they live. This leads to an increase in mortality, hopsitalizations, and adverse events. The need is clear: our patients need better care and better outcomes.

A Solution: ACTION

In 2017, we created a pediatric and adult Congential Heart Disease learning health network to overcome these barriers and challenges.[2] ACTION (the Advanced Cardiac Therapies Improving Outcomes Network) unites and connects our global healthcare community to improve outcomes for patients with heart failure. We bring patients, caregivers, providers, institutions, research, technology, regulatory bodies and industry together. By building this cohesive community with all stakeholders, we bring new technologies to pediatrics, we are cost efficient while being effective, and we focus on the outcomes that matter. To date, we have 60 member centers in North America, and engagement with institutions in eight countries.

Initiatives

ACTION initiatives have included planning and implementation of quality improvement projects, data collection, education and program material development, and much more. Discovery and improvement are often limited by small numbers of patients at any one care center; the open communication and transparency of outcomes between our members inspire inventive thinking and evidence-based practices to enhance standards of care and improve patient outcomes. Our network serves patients with Cardiomyopathy, Congenital Heart Disease, Ventricular Assist Device (VAD), Muscular Dystrophy, and Pediatric & Adult Fontan circulatory failure.

Data & Registries

Our data & registries form the basis for all projects across the network. We are aiming to have the most reliable pediatric heart failure data at the lowest cost. Currently we adjudicate our site data and adverse events, link to other data sources, format for use as Real World Data, collect patient reported outcomes data, and use data to determine network priorities. In 2020, the ACTION VAD registry was succesfully used for an expansion of the Abbott HeartMate 3 LVAD FDA label to include pediatrics. In November 2022, we launched the first VAD prospective trial using the ACTION registry, the Berlin Heart Active Driver trial.

Outcomes

Our work has led to a decrease in adverse events. Our first quality improvement project focused on reducing stroke rates for VAD patients. In 2017, approximately 30% of all children supported on Berlin Heart were suffering from a stroke event. We rolled out a bundle of interventions that included a change in the anticoagulation strategy, standardization of blood pressure measurement and innovative rounding strategies.[3] By implementing this bundle, the stroke rate for Berlin Heart patients is now 13%, overall VAD stroke rates have been reduced by 50%, and more lives are being saved by more devices being implanted. **See Figure 1.**

Education

Education for patients, families and providers has been a primary focus for ACTION. In the past, there was a paucity of pediatric-specific VAD educational materials. We are developing patient and provider-facing education materials, such as handbooks, infographics, videos, animations, and a video game, all delivered on an eLearning site: myACTIONeducation.org. We now have the framework to expand education materials to other patient populations. We will continue to create education materials as more medications and devices are approved for pediatric use.

Research & Trials

In more recent endeavors, ACTION has been focused on prospective device trials. After the expanded FDA label was obtained for the HeartMate 3 LVAD (press release available

action

ADVANCED CARDIAC THERAPIES IMPROVING OUTCOMES NETWORK

ACTION in MOTION – What we are Accomplishing

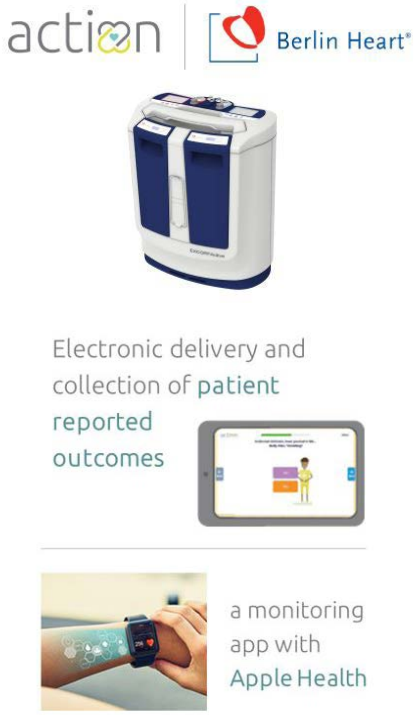

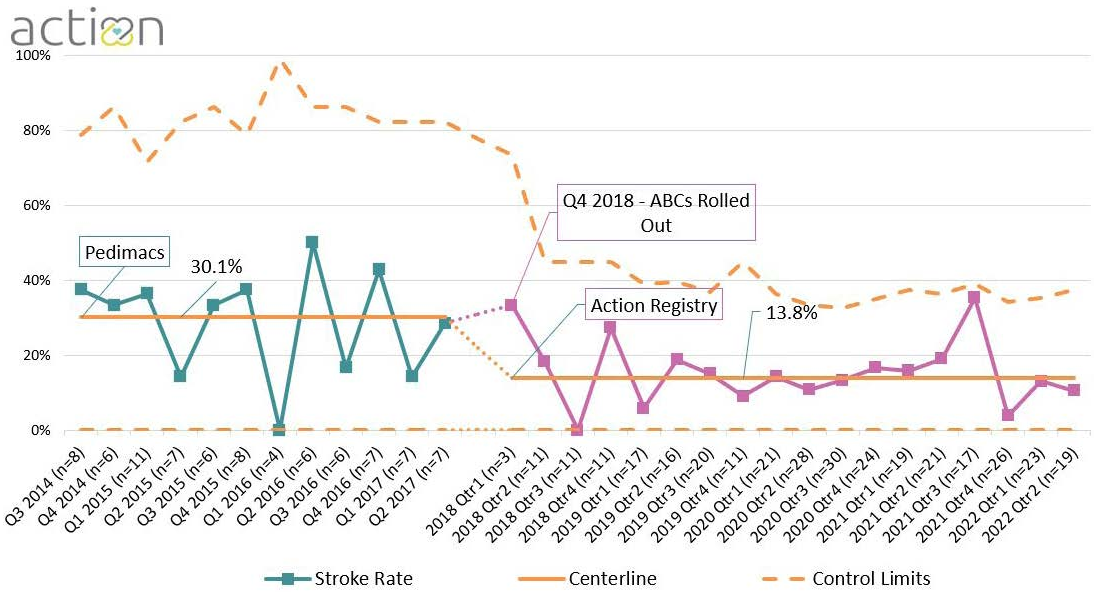

FIGURE 1 *Stroke rates over time from 2014-2022*

here), we have started to focus on a standard approach for future prospective trials. The first trial using this approach is the Berlin Heart Active Driver trial, actionlearningnetwork.org/our-trials/, and is being conducted through the learning network model. We have activated 13 sites and already enrolled 13 patients.

Innovation

Lastly, innovation in heart failure care is a core component of our network. In the past, we have had ineffective collection of patient reported outcomes, and no standard home monitoring with wearable technology. We are designing an electronic delivery and collection of patient-reported outcomes via iPad, email and text. Our pilot data has shown promising results for response rates in which 95% of surveys administered were completed.[4] We have also created a monitoring application with Apple Health so physical functional observational data can be collected directly from wearables, such as heart rate, six-minute walk test, weight, sleep, etc. With these innovative projects, we will have insight into the outcomes that patients feel matter most and real-time data from patients while living outside of the hospital.

Impact

In the past six years, ACTION has made a significant impact on pediatric VAD and heart failure outcomes, but there's more work to be done. Our goals include further engagement and collaboration with other organizations, industry partners and international sites to further our mission. With further collaborations we can bring new treatment options to children in heart failure.

How You Can Help / Get Involved

We cannot do this work alone; we need your help. There are many opportunities to get involved with ACTION, including:

- Reaching out to our network to get involved
- Proposing a research or quality improvement idea
- Spreading educational materials from your center
- Bringing innovation to the multicenter collaborative

To learn more and to get involved, please reach out to info@actionlearningnetwork.org or go to actionlearningnetwork.org. To read more about ACTION's outcomes & research, please visit our publications page.

References

1. Bansal N, Burstein DS, Lorts A, et al. Heart failure in children: Priorities and approach of the ACTION collaborative, Progress in Pediatric Cardiology, Volume 59, 2020, 101313, ISSN 1058-9813, https://doi.org/10.1016/j.ppedcard.2020.101313.
2. Lorts A, Smyth L, Gajarski RJ, et al. The Creation of a Pediatric Health Care Learning Network: The ACTION Quality Improvement Collaborative. ASAIO J. 2020;66(4):441-446. doi:10.1097/MAT.0000000000001133.
3. Villa CR, VanderPluym CJ; ACTION Investigators*. ABCs of Stroke Prevention: Improving Stroke Outcomes in Children Supported With a Ventricular Assist Device in a Quality Improvement Network. Circ Cardiovasc Qual Outcomes. 2020 Dec;13(12):e006663. doi: 10.1161/CIRCOUTCOMES.120.006663. Epub 2020 Dec 15. PMID: 33320692.
4. Cousino, MK, May, LJ, Smyth, L, et al. Patient and parent-reported outcomes in paediatric ventricular assist device support: a multi-center ACTION learning network feasibility and pilot experience. Cardiol Young(2023). DOI: https://doi.org/10.1017/S1047951122004048.

A Year Worth of ACTION
ACTION Looks Back at 2022 & Ahead to 2023

With the new year, the pediatric cardiology organization ACTION (the Advanced Cardiac Therapies Improving Outcomes Network), reflects on its accomplishments from 2022 and provides a view of what is to come in 2023.

ACTION's mission is to unite and connect the global healthcare community to improve outcomes for patients with heart failure, especially children.

"2022 was a tremendous, successful year for ACTION. We made great strides in improving outcomes for VAD, Heart Failure, Muscular Dystrophy and Fontan patients throughout 2022," said Angela Lorts, MD, MBA and Co-Executive Director of ACTION.

"As 2023 begins, we're already strategically planning to develop these four areas of ACTION further," continued Lorts. "Each focus area will have a registry for data collection, quality improvement initiatives, research, education, protocol harmonization efforts and innovation projects. We will also continue to develop our relationships with device and pharmaceutical companies and the FDA to better serve these orphan populations."

ACTION's 2022 Accomplishments

- **Apple Watch Study –** ACTION launched a first-of-its-kind Apple watch study for pediatric heart failure patients. Through an App built by the ACTION team, physical functional data is being collected to better understand heart failure patients on advanced cardiac therapies. The App collects data such as heart rate, six-minute walk tests, step count, weight and more.
- **Heart Failure Registry in ACTION –** successfully launched, it enables ACTION to do quality improvement, research and clinical trials for pediatric heart failure patients.
- **$2 Million Grant from Parent Project Muscular Dystrophy (PPMD) –** in June 2022, ACTION was awarded a $2 million grant from PPMD to expand muscular dystrophy focused research and quality improvement initiatives. PPMD's gift allows the expansion of ACTION's initiatives, including: MD database expansion; increase institution participation and ensure diverse representation; establish use of real-world data and prospective clinical trials for treatment of cardiac disease in muscular dystrophy; develop ACTION Patient Reported Outcomes (PRO); and develop educational modules for patients, caregivers and providers.
- **Ventricular Assist Device (VAD) Registry –** ACTION achieved a milestone of having 1,200 patients enter its VAD registry.
- **Berlin Heart Active Driver Trial –** launched its first prospective device trial, the Berlin Heart Active Driver Trial, using its real-world data registry model.
- ***In Real Life* Educational Series –** embarked on a new education initiative for VAD patients with a two-day series titled, In Real Life, in which VAD providers were educated on real-life situations, scenarios and challenges.
- **Fontan Referral Care –** also became a more prominent focus for ACTION in 2022. It held a quality improvement design meeting in which it identified problems, barriers and potential interventions from its baseline data.
- **Manuscripts Published –** closing out 2022 academically, ACTION is proud of the 22 manuscripts it published as a network to date.

ACTION'S 2023 Look Ahead

2023 will be a busy year for ACTION. The organization looks head at the following activities:

- Completing enrollment in the Berlin Heart Active Driver Trial and identifying future trials for pediatric heart failure.
- Launching Fontan referral interventions and data collection, including the development of education for community providers and patients/families.
- Producing site-specific quality reports to improve data transparency and outcomes at the local level.
- Further collaboration with other mission-similar organizations.

To learn more about ACTION and how you could join its efforts, please visit actionlearningnetwork.org.

About ACTION

ACTION (the Advanced Cardiac Therapies Improving Outcomes Network) is an organization that unites and connects a global healthcare community to improve outcomes for patients with heart failure, especially children. Since 2017, ACTION has continued to grow and engage an international community by uniting key stakeholders: patients, families, clinicians, researchers, payors and industry.

Based in Cincinnati, OH, ACTION uses a quality improvement and research-based approach. ACTION works in collaboration with network sites and network members, sharing data, finding better solutions and discovering new innovations. Currently, there are 58 network sites and 1,185 network members. Learn more at actionlearningnetwork.org.

CONGENITAL CARDIOLOGY TODAY

CORPORATE OFFICE

PO Box 52316
Sarasota, FL 34232 USA

OFFICIAL NEWS & INFORMATION PARTNER OF

PICS Society

Pediatric *and Congenital* Interventional Cardiovascular Society

ISSN 1554-7787 print. ISSN 1554-0499 electronic.
Published monthly.