



July 2019 - Volume 17 - Issue 7
North American Edition

Table of Contents

Balloon Fracture of Surgical Pulmonary Valve Rings Improve Subsequent Transcatheter Implantations

By Farhouch Berdjis, MD; Michael R. Recto, MD; Sharib Gaffar, MD - p. 1

Medical News, Products & Information - p. 7

Recruitment - p. 11, 13, 14, 17

Upcoming Medical Meetings

CHIP: Become a Better Interventionalist by Learning From Complications

Aug. 2-3, 2019; Seattle, WA USA

PICS-AICS 2019

Sept. 4-7, 2019; San Diego, CA USA
www.picsymposium.com

2019 Cardiac Surgery and Cardiology Conference (2019CSC)

Sept. 10-11, 2019; Singapore
www.cardiology.episirus.org

2019 North American Society for Cardiac Imaging

Sept. 14-17, 2019; Seattle, WA USA
www.nasci.org/Future-Meetings

8th Annual Adult Congenital Heart Disease in the 21st Century

Oct. 4-5, 2019; Bethesda, MD USA
www.ce.medstarhealth.org/ACHD

Corporate Office

11502 Elk Horn Drive
Clarksburg, MD 20871 USA



@ccardiology

www.CongenitalCardiologyToday.com

Official publication of the CHiP Network

Balloon Fracture of Surgical Pulmonary Valve Rings Improve Subsequent Transcatheter Implantations

By Farhouch Berdjis, MD; Michael R. Recto, MD; Sharib Gaffar, MD

Abstract

The management of right-ventricle-to-main-pulmonary artery conduit in patients who have previously undergone transannular right-ventricular outflow patch for Tetralogy of Fallot (TOF) continues to evolve. In this case series, we describe our experience with transcatheter management of five patients who had previously undergone placement of an Edwards pericardial tissue valve in the right-ventricle-to-main pulmonary artery position, and developed both severe pulmonary valve insufficiency and mild-to-moderate pulmonary valve stenosis with right ventricular enlargement. In order to optimally place the largest available Melody valve (22 mm), these patients underwent pulmonary valve ring fracture with high pressure Atlas balloons. The Atlas balloons were upsized by 1 mm from the surgical valve diameter and inflated to 22 atm. Valve ring fracture was achieved in all five cases. Post valve ring fracture, the diameter increased between 1.1 to 1.8 mm (mean 1.3 mm) and pressure gradient across the fractured valve ring decreased between 7 to 18 mmHg. This case series describes

successful fracture of surgically-placed pulmonary valve ring with high pressure Atlas balloons and subsequent placement of the largest available Melody valve.

Keywords

Atlas balloon splitting of surgical valve ring, Melody valve-in-valve implantation, RVOT restenosis, Tetralogy of Fallot

Introduction

The surgical repair of Tetralogy of Fallot (TOF) has not significantly changed since it was first proposed by Lillehei in 1954¹. The operation consists primarily of Ventricular Septal Defect closure and placement of a transannular right-ventricular outflow tract patch. Almost all patients who have undergone complete TOF repair will, over time, develop progressive right ventricular enlargement secondary to pulmonary valve insufficiency. For many years, standard management of pulmonary valve insufficiency following complete TOF repair with transannular right-ventricular outflow tract (RVOT) placement involved placement of surgical valved conduits. These valved conduits would then calcify and either develop stenosis or insufficiency. Transcatheter (Melody) valve placement

Recruit with CCT

Recruitment advertisements are listed

- In print and electronic monthly issue
- On our website
- In our monthly email blast



Contact: Kate@cct.bz

is accepted therapy for patients who have previously undergone placement of prosthetic right ventricle to main pulmonary artery conduits who, over time, have developed significant conduit stenosis or insufficiency². In this case series, we document our experience fracturing surgically-placed Edwards pericardial tissue valves (Edwards Lifesciences Corporation; Irvine, California) with high pressure Atlas Balloons (Bard Peripheral Vascular; Tempe, Arizona) in four patients with TOF and one patient with critical pulmonary valve stenosis who had initially required transannular RVOT patch as an infant and subsequent placement of an Edwards pericardial tissue valve. The pulmonary valve ring was successfully fractured in all five cases, allowing for successful implantation of the larger diameter (22 mm Melody) valve that would have been possible without pulmonary valve ring fracture.

Methods

Five patients, four males and one female, were followed on a regular basis from the newborn period until their adolescent years. Four of the five patients had TOF; the remaining patient had critical pulmonary valve stenosis. The four patients with TOF underwent complete repair with transannular RVOT patch placement between three to eight months of age (median five months old). The one patient with critical pulmonary valve stenosis underwent transannular RVOT patch at 2.5 mos after progressive cyanosis following balloon valvuloplasty on the first day of life. After complete repair, these patients developed severe pulmonary valve insufficiency and right ventricular enlargement necessitating placement of an Edwards pericardial tissue pulmonic valve between five and nine years of age (median eight years old).

All patients had regular yearly echocardiograms performed during cardiology follow-up appointments. Progressive echocardiograms demonstrated severe pulmonary valve insufficiency with right ventricular enlargement. Two of the patients also developed moderate pulmonary valve stenosis. The decision was then made to proceed with transcatheter Melody valve placement to relieve the pulmonic insufficiency and halt progression of right ventricular enlargement.

The patients ranged from 9 to 15 years old (median 11 years) at time of catheterization, with weight ranging from 31 to 77 kg (median 48 kg). The time between placement of surgical pericardial tissue valve and need for transcatheter Melody valve placement ranged from three to six years (median six years).

Surgical Pulmonary Valve Ring Fracture Technique

All patients underwent cardiac catheterization under general anesthesia. Both right- and left- heart catheterization, including compression testing to rule out coronary compression, were performed in all cases. The diameter of the Edwards pulmonary valve ring was measured pre- and post-valve fracture (Figure 1A, 1D). An Atlas high-pressure balloon 1 mm greater in diameter than the surgically-placed pulmonary valve ring was successfully utilized to fracture the valve ring in all cases. The Atlas balloons were carefully inflated to a maximum pressure of 22 atmospheres, achieving successful fracture of the surgical valve ring without significant recoil or main pulmonary artery tear. The valve ring fracture was visually confirmed under angiography (Figure 1B, 1C). Following successful valve ring fracture, the mean pressure gradient across the Edwards pulmonary valve decreased between 7 and 18 mmHg (median 8 mmHg). The valve ring diameter increased between 1.1 and 1.8 mm (median 1.3 mm). In all cases, a 22 mm Melody transcatheter pulmonary valve mounted on a 22 mm Ensemble delivery system was positioned across the fractured surgical valve ring and implanted in standard fashion without complications. Repeat angiography post Melody valve placement showed resolution of pulmonary valve stenosis and insufficiency (Figure 1D).

All patients were observed overnight in the Cardiovascular Intensive Care Unit without complications and discharged home the following morning. At their outpatient follow-up appointments, repeat echocardiogram showed resolution of both pulmonary valve insufficiency and stenosis with stable right ventricular dimensions.

Discussion

Patients who have undergone surgical placement of right-ventricle-to-pulmonary artery (RV-PA) conduits will, at some point in time, require replacement of

their conduit^{3,4}. The average lifespan of surgically-placed conduits is approximately four to ten years^{3,5}. Depending on the age and weight of these patients, a good number of them will be candidates to undergo transcatheter pulmonary valve placement. Currently, most centers utilize a weight greater than 20 kg and a surgical conduit measuring greater than or equal to 16 mm in diameter as suitable candidates for transcatheter pulmonary valve placement⁶. Having said that, not all surgically placed pulmonary valves are suitable candidates for successful fracture of the pulmonary valve ring. Patients who previously underwent placement of Trifecta (St. Jude Medical) and Hancock II (Medtronic) bioprosthetic valves are limited by the size of the initial implanted valve, since these valves cannot be fractured⁷.

The goal of transcatheter pulmonary valve placement has been to implant the largest possible valve. Melody valves come in 20 and 22 mm diameters. In the case of our five patients, the smallest Edwards pericardial tissue valve implanted was 19 mm (the other valves were 22 or 23 mm). By fracturing the 19 mm pulmonary valve ring we increased the diameter of the pulmonary valve from 16.7 to 18.3 mm, enabling successful implantation of the larger 22 mm Melody valve. Mean increase in pulmonary valve diameter post-split for our five patients was 1.4 mm.

It is important to note that coronary compression testing is important in all of these cases. Coronary compression is well described prior to transcatheter pulmonary valve placement^{7,8,9}. Further studies are required to clearly define a low-risk distance between the pulmonary valve and coronary ostia, although Saxon et al suggest a distance less than 5 mm may be considered high risk for balloon fracture⁷. Balloon testing of the pulmonary annulus prior to fracture should be done on all cases to clearly define the coronary ostia distance from the pulmonary annulus. Balloon fracture of surgical valves should also only be attempted on those patients with normal aortic and coronary location and anatomy^{9,10}. Aortic root distortion, non-coronary aortic root compression, and aortic insufficiency have also been described, albeit temporarily in most cases^{11,12,13}. In the event that coronary compression or compression of the aorta is noted during compression testing, the placement of a larger diameter transcatheter pulmonary

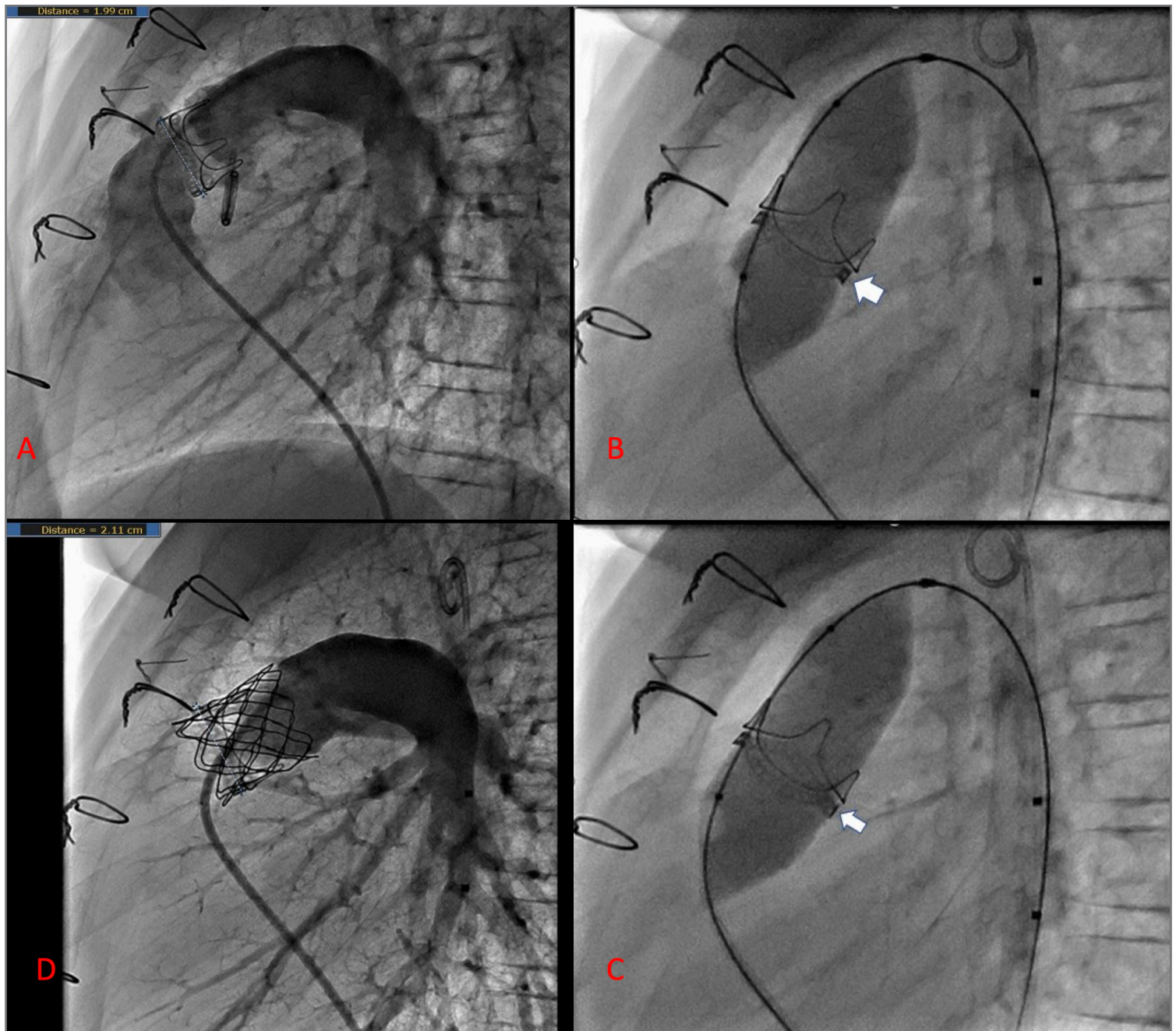


Figure 1. Patient with an initial 21 mm Edwards surgical valve. Clockwise from A to D: A) Valve diameter was 19.9 mm and had evident severe pulmonic insufficiency. B) 22 mm Atlas balloon immediately prior to (white arrow) and C) after successful valve splitting (white arrow). D) Transcatheter 22 mm Melody valve successfully implanted, with resolution of pulmonic insufficiency. Post-splitting valve diameter is now 21.1 mm.

valve would not be feasible. The patient would instead require a surgical pulmonary valve replacement.

Valve-in-valve replacement is well described in the literature, and balloon fracture of surgical valve rings is an accepted approach prior to valve-in-valve replacement, especially in high-risk aortic valve replacement^{10,11,14}. However, pulmonary valve-in-valve replacement for conduit stenosis can be more challenging secondary to the decreased elastic tissue content of the pulmonary outflow tract¹⁰. In addition, balloon fracture of the surgical valve ring with high pressure balloons places evenly distributed radial stress throughout the valve ring, with the point of weakness on the valve ring not always evident. This can lead to uncertainty as to

where the fracture will occur, and which adjacent structures could be at risk for rupture. By upsizing the Atlas balloons by 1 mm above the original surgical valve diameter and applying slow inflation to reach maximal pressure during an attempt at valve ring fracture, the risk of vascular trauma or dissection at the valve ring site can be minimized. The benefits of this approach are similar to those seen during aortic valve-in-valve replacement following balloon valvuloplasty: increased effective orifice diameter at the valve site, flexibility to place a larger transcatheter valve, and decreased risk of transcatheter valve failure or collapse by allowing for maximal expansion of the replacement valve with decreased collapsing pressure imposed by an intact surgical valve ring.

Conclusion

We describe five cases of successful high-pressure balloon fracture of surgically-placed pulmonary valve rings as a means to facilitate placement of a larger diameter percutaneous transcatheter pulmonary valve. Our five patients encompassed a broad age and weight range. In all five cases, balloon fracture of the surgical pericardial tissue valve showed decreased pressure gradient across the RVOT, and increased diameter of the valve ring itself. This method may be of benefit for patients who have undergone prior surgical placement of RV-PA conduits who, over time, have developed significant conduit stenosis and insufficiency. All five patients showed immediate resolution of their severe pulmonic insufficiency, and interventions were completed without complication. However, a larger sample size of patients as well as longer-term follow-up is required to fully evaluate the efficacy of this approach as a means to avoid or prolong future surgical intervention.

References

1. Lillehei CW, Varco RL, Cohen M, Warden HE, Patton C, Moller JH. The first open-heart repairs of ventricular septal defect, atrioventricular communis, and tetralogy of Fallot using extracorporeal circulation by cross-circulation: a 30-year follow-up. *Ann Thorac Surg* 1986 Jan;41(1):4-21.
2. Hascoet S, Acar P, Boudjemline Y. Transcatheter pulmonary valvulation: current indications and available devices. *Arch Cardiovasc Dis* 2014 Nov;107(11):625-634.
3. Dearani JA, Danielson GK, Puga FJ, Schaff HV, Warnes CW, Driscoll DJ, et al. Late follow-up of 1095 patients undergoing operation for complex congenital heart disease utilizing pulmonary ventricle to pulmonary artery conduits. *Ann Thorac Surg* 2003 Feb;75(2):399-410; discussion 410-1.
4. Whiteside W, Tretter JT, Aboulhosn J, Aldoss O, Armstrong AK, Bocks ML, et al. Acute and Midterm Outcomes of Transcatheter Pulmonary Valve Replacement for Treatment of Dysfunctional Left Ventricular Outflow Tract Conduits in Patients With Aortopulmonary Transposition and a Systemic Right Ventricle. *Circ Cardiovasc Interv* 2017 Sep;10(9).
5. Yuan SM, Mishaly D, Shinfeld A, Raanani E. Right ventricular outflow tract reconstruction: valved conduit of choice and clinical outcomes. *J Cardiovasc Med (Hagerstown)* 2008 Apr;9(4):327-337.
6. Ghawi H, Kenny D, Hijazi ZM. Transcatheter pulmonary valve replacement. *Cardiol Ther* 2012 Dec;1(1):5-012-0005-9. Epub 2012 Oct 16.
7. Saxon JT, Allen KB, Cohen DJ, Chhatrwalla AK. Bioprosthetic Valve Fracture During Valve-in-valve TAVR: Bench to Bedside. *Interv Cardiol* 2018 Jan;13(1):20-26.
8. Chatterjee A, Bajaj NS, McMahon WS, Cribbs MG, White JS, Mukherjee A, et al. Transcatheter Pulmonary Valve Implantation: A Comprehensive Systematic Review and Meta-Analyses of Observational Studies. *J Am Heart Assoc* 2017 Aug 4;6(8):1-10.
9. Fraisse A, Assaidi A, Mauri L, Malekzadeh-Milani S, Thambo JB, Bonnet D, et al. Coronary artery compression during intention to treat right ventricle outflow with percutaneous pulmonary valve implantation: incidence, diagnosis, and outcome. *Catheter Cardiovasc Interv* 2014 Jun 1;83(7):E260-8.
10. Tanase D, Grohmann J, Schubert S, Uhlemann F, Eicken A, Ewert P. Cracking the ring of Edwards Perimount bioprosthesis with ultrahigh pressure balloons prior to transcatheter valve in valve implantation. *Int J Cardiol* 2014 Oct 20;176(3):1048-1049.
11. Raval J, Nagaraja V, Eslick GD, Denniss AR. Transcatheter valve-in-valve implantation: a systematic review of literature. *Heart Lung Circ* 2014 Nov;23(11):1020-1028.
12. Torres AJ, McElhinney DB, Anderson BR, Turner ME, Crystal MA, Timchak DM, et al. Aortic Root Distortion and Aortic Insufficiency During Balloon Angioplasty of the Right Ventricular Outflow Tract Prior to Transcatheter Pulmonary Valve Replacement. *J Interv Cardiol* 2016 Apr;29(2):197-207.
13. Lindsay I, Aboulhosn J, Salem M, Levi D. Aortic root compression during transcatheter pulmonary valve replacement. *Catheter Cardiovasc Interv* 2016 Nov;88(5):814-821.
14. Brown SC, Cools B, Gewillig M. Cracking a tricuspid perimount bioprosthesis to optimize a second transcatheter sapien valve-in-valve placement. *Catheter Cardiovasc Interv* 2016 Sep;88(3):456-459.




Farhouch Berdjis, MD
Principal Author

*Children's Hospital of Orange County
1010 W La Veta Ave. Suite 575
Orange, CA, USA
714.547.0900
fberdjis@gmail.com*



Michael R. Recto, MD

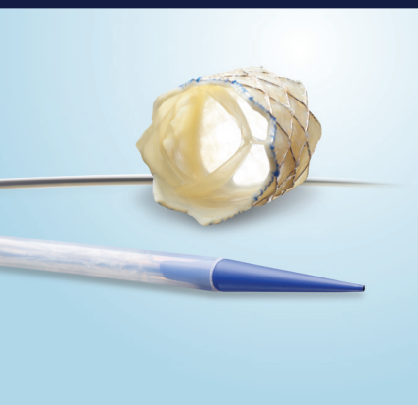*Children's Hospital of Orange County
Orange, CA, USA*



Sharib Gaffar, MD
Communicating Author

*Children's Hospital of Orange County,
CA, USA
University of California Irvine, CA, USA
Miller Children's and Women's Hospital
Long Beach, CA, USA
818.599.0231
sgaffar@uci.edu*

RIGHT CHOICE.



Melody™
Transcatheter Pulmonary
Valve (TPV) System



Not intended to constitute medical advice or in any way replace the independent medical judgment of a trained and licensed physician with respect to any patient needs or circumstances. Melody TPV is not suitable for all patients and ease of use, outcomes, and performance may vary. See the Instructions for Use for indications, contraindications, precautions, warnings, and adverse events.

Restoring lives for

11

years and counting.

The only transcatheter pulmonary valve specifically designed for RVOT conduits and bioprosthetic valves. The longest studied, with the largest body of clinical evidence at 7 years post-implant.* Over 11 years of implants, more than 12,000 patients' lives have been changed.

**Melody TPV — The Right Choice
for Your Patients**

*Melody Transcatheter Pulmonary Valve Study:
Post Approval Study of the Original IDE Cohort.
©2018 Medtronic. All rights reserved.
UC201809495 EN 02/2018

Medtronic
Further, Together

Melody™ Transcatheter Pulmonary Valve, Ensemble™ II Transcatheter Valve Delivery System

Important Labeling Information for the United States

Indications: The Melody TPV is indicated for use in the management of pediatric and adult patients who have a clinical indication for intervention on a dysfunctional right ventricular outflow tract (RVOT) conduit or surgical bioprosthetic pulmonary valve that has \geq moderate regurgitation, and/or a mean RVOT gradient \geq 35 mm Hg.

Contraindications: None known.

Warnings/Precautions/Side Effects:

- **DO NOT implant in the aortic or mitral position. Pre-clinical bench testing of the Melody valve suggests that valve function and durability will be extremely limited when used in these locations.**
- DO NOT use if patient's anatomy precludes introduction of the valve, if the venous anatomy cannot accommodate a 22 Fr size introducer, or if there is significant obstruction of the central veins.
- DO NOT use if there are clinical or biological signs of infection including active endocarditis. Standard medical and surgical care should be strongly considered in these circumstances.
- Assessment of the coronary artery anatomy for the risk of coronary artery compression should be performed in all patients prior to deployment of the TPV.
- To minimize the risk of conduit rupture, do not use a balloon with a diameter greater than 110% of the nominal diameter (original implant size) of the conduit for pre-dilation of the intended site of deployment, or for deployment of the TPV.
- The potential for stent fracture should be considered in all patients who undergo TPV placement. Radiographic assessment of the stent with chest radiography or fluoroscopy should be included in the routine postoperative evaluation of patients who receive a TPV.
- If a stent fracture is detected, continued monitoring of the stent should be performed in conjunction with clinically appropriate hemodynamic assessment. In patients with stent fracture and significant associated RVOT obstruction or regurgitation, reintervention should be considered in accordance with usual clinical practice.

Potential procedural complications that may result from implantation of the Melody device include the following: rupture of the RVOT conduit, compression of a coronary artery, perforation of a major blood vessel, embolization or migration of the device, perforation of a heart chamber, arrhythmias, allergic reaction to contrast media, cerebrovascular events (TIA, CVA), infection/sepsis, fever, hematoma, radiation-induced erythema, blistering, or peeling of skin, pain, swelling, or bruising at the catheterization site.

Potential device-related adverse events that may occur following device implantation include the following: stent fracture, stent fracture resulting in recurrent obstruction, endocarditis, embolization or migration of the device, valvular dysfunction (stenosis or regurgitation), paravalvular leak, valvular thrombosis, pulmonary thromboembolism, hemolysis.

"The term "stent fracture" refers to the fracturing of the Melody TPV. However, in subjects with multiple stents in the RVOT it is difficult to definitively attribute stent fractures to the Melody frame versus another stent.

For additional information, please refer to the Instructions for Use provided with the product or available on <http://manuals.medtronic.com>.

CAUTION: Federal law (USA) restricts this device to sale by or on the order of a physician.

Important Labeling Information for Geographies Outside of the United States

Indications: The Melody™ TPV is indicated for use in patients with the following clinical conditions:

- Patients with regurgitant prosthetic right ventricular outflow tract (RVOT) conduits or bioprostheses with a clinical indication for invasive or surgical intervention, OR
- Patients with stenotic prosthetic RVOT conduits or bioprostheses where the risk of worsening regurgitation is a relative contraindication to balloon dilatation or stenting

Contraindications:

- Venous anatomy unable to accommodate a 22 Fr size introducer sheath
- Implantation of the TPV in the left heart
- RVOT unfavorable for good stent anchorage
- Severe RVOT obstruction, which cannot be dilated by balloon
- Obstruction of the central veins
- Clinical or biological signs of infection
- Active endocarditis
- Known allergy to aspirin or heparin
- Pregnancy

Potential Complications/Adverse Events: Potential procedural complications that may result from implantation of the Melody device include the following: rupture of the RVOT conduit, compression of a coronary artery, perforation of a major blood vessel, embolization or migration of the device, perforation of a heart chamber, arrhythmias, allergic reaction to contrast media, cerebrovascular events (TIA, CVA), infection/sepsis, fever, hematoma, radiation-induced erythema, pain, swelling or bruising at the catheterization site.

Potential device-related adverse events that may occur following device implantation include the following: stent fracture, stent fracture resulting in recurrent obstruction, endocarditis, embolization or migration of the device, valvular dysfunction (stenosis or regurgitation), paravalvular leak, valvular thrombosis, pulmonary thromboembolism, hemolysis.

"The term "stent fracture" refers to the fracturing of the Melody TPV. However, in subjects with multiple stents in the RVOT it is difficult to definitively attribute stent fractures to the Melody frame versus another stent.

For additional information, please refer to the Instructions for Use provided with the product or available on <http://manuals.medtronic.com>.

The Melody Transcatheter Pulmonary Valve and Ensemble II Transcatheter Delivery System has received CE Mark approval and is available for distribution in Europe.

medtronic.com

710 Medtronic Parkway
Minneapolis, MN 55432-5604
USA
Tel: (763) 514-4000
Fax: (763) 514-4879
Toll-free: (800) 328-2518

LifeLine
CardioVascular Technical Support
Tel: (877) 526-7890
Tel: (763) 526-7890
Fax: (763) 526-7888
rs.cstechsupport@medtronic.com

Medical News, Products & Information

Compiled and Reviewed by Kate Baldwin and Tony Carlson

B. Braun Interventional Systems Announces U.S. Commercial Launch of NuDEL™ All-in-One Stent Delivery System for treatment of congenital heart defects

B. Braun Interventional Systems Inc. (BIS) in collaboration with NuMED Inc. announced today the U.S. launch of the NuDEL™ CP Stent® Delivery System, intended for the treatment of coarctation of the aorta and right ventricular outflow tract conduit disruptions. The announcement was made during the SCAI 2019 Scientific Sessions, taking place from May 19–22 in Las Vegas, where BIS is exhibiting at Booth #608.

The NuDEL™ Stent Delivery System is the latest state-of-the-art addition to the BIS congenital and structural heart portfolio and is a line extension to the CP Stent® family of products manufactured by NuMED. Comprised of a pre-mounted Covered CP Stent on a balloon in balloon (BIB®) catheter that is pre-loaded inside of a kink-resistant sheath, the NuDEL system provides physicians with an “all-in-one” device for the treatment of congenital heart defects.

“The NuDEL is a novel product that combines three separate devices into a single tool, which provides physicians procedural efficiency by eliminating the need to hand crimp or load a mounted stent into an introducer,” said Jennifer Gotto, B. Braun Interventional Systems Product Manager. The NuDEL System is offered in key diameters ranging from 12mm to 24mm, and lengths from 1.6cm to 4.5cm for enhanced delivery of covered CP stents.

Visitors to the BIS booth (#608) at the SCAI 2019 Scientific Sessions will be able to see the NuDEL Stent Delivery System and learn more about the company's growing congenital and structural heart portfolio.

About B. Braun Interventional Systems

B. Braun Interventional Systems offers interventional solutions designed with the patient in mind. Many of the products offered have been developed in response to the needs of physicians, technicians, and nurses. The company is committed to delivering safety, precision and convenience to interventional procedures. B. Braun Interventional Systems Inc. is part of the B. Braun Group of Companies in the U.S., which is headquartered in Bethlehem, Pa., and includes B. Braun Medical Inc., Aesculap® and CAPS®.

Globally, the B. Braun Group of Companies employs more than 61,000 employees in 64 countries. Guided by its Sharing Expertise® philosophy, B. Braun continuously exchanges knowledge with customers, partners and clinicians to address the critical issues of improving care and lowering costs. To learn more about B. Braun Interventional Systems Inc., visit www.bisusa.org/about-us.

About NuMED, Inc.

Since 1982, NuMED has been developing, manufacturing and delivering innovative cardiovascular medical products for the smallest of patients to adults with heart defects.

Headquartered in Hopkinton, NY, NuMED's mission is to improve the quality of patient care and the productivity of health care by developing and advocating less-invasive medical devices and procedures. They are committed to continually refining their existing products, and researching new technologies that can reduce risk, trauma, cost, procedure time and the need for aftercare. To learn more about NuMED, visit www.numedforchildren.com.

Ochsner Health System and Geneva Health Solutions Partner to Bring Innovation to Louisiana Patients with Cardiac Device Implants

Ochsner Health System – a nationally-recognized healthcare system based in Louisiana – announced a new partnership with Geneva Health Solutions (GHS) – the leading device data management platform and remote monitoring service for implantable cardiac devices. This partnership marks the first time GHS cloud-based technology platform and remote monitoring service for patients with cardiac implants will be utilized in the region – Louisiana, Arkansas, Mississippi, Alabama and Georgia. The GHS system will drive fully-automated scheduling and reporting in collaboration with Ochsner's established electronic medical record (EPIC).

“Innovation has been fundamental for Ochsner since its founding under the leadership of Dr. John L. Ochsner, Sr., who pioneered valve and coronary surgery. From performing the first heart transplant in the Gulf South to participating in more than 100 clinical trials, Ochsner's cardiology team embraces new technology and procedures that improve patient outcomes,” said Christopher White, MD, Director for John Ochsner Heart and Vascular Institute. “This partnership with Geneva Health Solution complements our relentless spirit for advancing the knowledge of the mechanisms, treatments and diagnoses of Cardiovascular Disease for our patients in Louisiana and beyond.”

Todd Mule, Vice President, Cardiology Service Line, Ochsner Health System added, “Ochsner is committed to investing in patient-centric technology and is confident that partnering with Geneva Health Solutions will further enhance what we are able to offer our patient and coordinated care team through our electronic medical records platform, Epic. Ochsner's investment in, and enthusiasm for, technology offers our patients enhanced coordination of care, convenience and better results.”

All-In-One
for Rapid
Deployment



NuDEL™

CP Stent® Delivery System

For Treatment of Coarctation of the Aorta and
RVOT Conduit Disruption

Distributed by:

B. Braun Interventional Systems Inc. | Part of the B. Braun Group of Companies
824 Twelfth Avenue | Bethlehem, PA 18018 | USA
Tel 877-836-2228 | Fax 610-849-1334 | www.bisusa.org

Indications for Use: The NuDEL is indicated for use in the treatment of native and/or recurrent coarctation of the aorta involving the aortic isthmus or first segment of the descending aorta where there is adequate size and patency of at least one femoral artery associated with one or more of the following: acute or chronic wall injury; nearly atretic descending aorta of 3 mm or less in diameter; a non-compliant stenotic aortic segment found on pre-stent balloon dilation; a genetic or congenital syndrome associated with aortic wall weakening or ascending aortic aneurysm.

Indications for Use: The NuDEL is indicated for use in the treatment of right ventricle to pulmonary artery (right ventricular outflow tract) conduit disruptions that are identified during conduit pre-dilatation procedures performed in preparation for transcatheter pulmonary valve replacement.

Caution: Federal (USA) Law restricts this device to sale by or on the order of a physician. **Contraindications:** Clinical or biological signs of infection. Active endocarditis. Pregnancy. **Contraindications (CoA only):** Patients too small to allow safe delivery of the stent without compromise to the systemic artery used for delivery. Unfavorable aortic anatomy that does not dilate with high pressure balloon angioplasty. Curved vasculature. Occlusion or obstruction of systemic artery precluding delivery of the stent. Known allergy to aspirin, other antiplatelet agents, or heparin. **Contraindications (RVOT only):** Patients too small to allow safe delivery of the stent without injury to a systemic vein or to the right side of the heart. **Warnings / Precautions:** Administer appropriate anticoagulation therapy to reduce potential thrombosis. If the patient is not appropriately anticoagulated, thrombus formation may occur. The sheath must be flushed with heparinized saline via the proximal side port prior to introducing the delivery system into the body. The inflated diameter of the stent should at least equal the diameter of the intended implant site. Excessive handling and manipulation of the covering while crimping the stent may cause the covering to tear off of the stent. Retracting the covered stent back into the sheath may cause the covering to catch and tear off of the stent. Do not exceed the RBP. An inflation device with pressure gauge is recommended to monitor pressure. Pressure in excess of the RBP can cause balloon rupture and potential inability to withdraw the catheter into the sheath. Confirm that the distal end of the introducer sheath is at least 2.5cm back from the most proximal image band before inflating the outer balloon. Failure to do so may stretch the outer tubing and severely hinder balloon deflation. Exercise caution when handling the stent to prevent breakage. The NuDEL system, especially at the stent, is rigid and may make negotiation through vessels difficult. The inflation diameter of the balloon used during stent delivery should approximate the diameter of the obstructive vessel and the intended implant site. If resistance is encountered upon removal, the whole system (balloon, guidewire and sheath) should be removed as a single unit, particularly if balloon rupture or leakage is known or suspected. **Warnings / Precautions (CoA only):** Coarctation of the aorta involving the aortic isthmus or first segment of the descending aorta should be confirmed by diagnostic imaging. The NuMED CP Stent has not been evaluated in patients weighing less than 20kg. The platinum/iridium stent may migrate from the site of the implant. As with any type of implant, infection secondary to contamination of the stent may lead to aortitis, or abscess. Over-stretching of the artery may result in rupture or aneurysm formation. **Warnings / Precautions (RVOT only):** During the Premarket Approval study the Medtronic Melody valve was used for valve restoration. The safety and effectiveness of the Covered CP Stent for pre-stenting of the right ventricular outflow tract (RVOT) landing zone (i.e. prophylaxis or prevention of either RVOT conduit rupture or TPVR fracture; use as a primary RVOT conduit) in preparation of a transcatheter pulmonary valve replacement (TPVR) has not been evaluated. As with any type of implant, infection secondary to contamination of the stent might lead to endocarditis, or abscess formation. The Covered Stent can migrate from the site of implant potentially causing obstruction to pulmonary artery flow. Over-stretching of the RVOT may result in rupture or aneurysm of the RV-PA conduit or the native pulmonary artery. Reference the IFU for a complete listing of indications, contraindications, warnings and precautions. www.bisusa.org

Rx only

CP Stent is a registered trademark of NuMED, Inc.
NuDEL is a trademark of NuMED, Inc.
©2019 B. Braun Interventional Systems Inc.
CV-9107 6/19



Millions of Americans have implanted cardiac devices. Patients with these devices, such as pacemakers, defibrillators and loop recorders, transmit critical cardiac data from their implanted device from the comfort of their homes to the provider via the cloud. These transmissions allow providers to monitor their patients proactively for both routine device follow-up and alerts regarding device issues or clinical events, like atrial fibrillation and other indicators of heart failure. The GHS patent-pending platform aggregates cardiac device data from all major device manufacturers' remote monitoring portal, in-office checks and ER visits. The GHS remote monitoring service helps providers manage the incoming data in an outpatient setting.

"We are honored to be selected by Ochsner to deliver a high-caliber remote monitoring service to their patients and help become an extension of Ochsner's hardworking device clinic team," said Yuri Sudhakar, CEO of GHS. "The data deluge from these devices can overwhelm cardiac practices, physicians and staff. With our platform and service, cardiology practices can focus on their patients, not data management."

GHS's service and platform is being used in over 60 cardiology practices nationwide, improving workflow for physicians and staff, increasing patient compliance, identifying issues about patient's devices or critical cardiac conditions in advance, and helping reduce costs from hospitalizations.

For more information about GHS, visit www.genevahealthsolutions.com. For more information about Ochsner Health System, visit www.ochsner.org.

About Geneva Health Solutions

Founded by a team of cardiologists and technologists, Geneva Health Solutions transforms cardiac device data into actionable information to improve clinical

workflow and patient care for cardiology practices across the country. It is the only solution offering to combine a patent-pending enterprise cloud-based platform and a high-quality service for remote monitoring of implantable cardiac devices. Learn more at www.genevahealthsolutions.com.

About Ochsner Health System

Ochsner Health System is Louisiana's largest non-profit, academic, healthcare system. Driven by a mission to Serve, Heal, Lead, Educate and Innovate, coordinated clinical and hospital patient care is provided across the region by Ochsner's 30 owned, managed and affiliated hospitals and more than 80 health centers and urgent care centers. Ochsner is the only Louisiana hospital recognized by *U.S. News & World Report* as a "Best Hospital" across three specialty categories caring for patients from all 50 states and more than 60 countries worldwide each year. Ochsner employs more than 19,000 employees and over 1,200 physicians in over 90 medical specialties and subspecialties and conducts more than 700 clinical research studies. Ochsner Health System is proud to be a tobacco-free environment.

For more information, please visit www.ochsner.org and follow us on Twitter and Facebook.

For more information on Ochsner Health System, visit www.ochsner.org.

published online today in *The Annals of Thoracic Surgery*.

"It was comforting to see that the differences in cognitive decline between the two heart procedures are small, even though one involves major surgery and the other—cardiac catheterization—is a minimally invasive procedure," said Elizabeth Whitlock, MD, from the University of California, San Francisco.

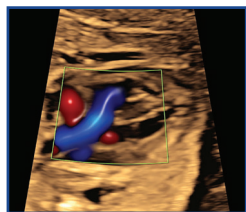
Using the Health and Retirement Study (HRS), Dr. Whitlock and colleagues examined data from 3,105 participants who reported undergoing either heart surgery or cardiac catheterization between 2000 and 2014. Cardiac catheterization is a catheter-based procedure that is usually performed as a diagnostic procedure prior to cardiac surgery. It is also used in conjunction with placing coronary artery stents to treat coronary artery disease. Funded by the *National Institute on Aging*, the HRS is an anonymous study of older adults in the United States. Thousands of HRS participants answer questions about their health and take brief memory tests every two years. Data on demographic, economic, health, quality of life, and cognitive factors are collected.

"It is important to make sure research like this includes diverse and large samples to fully account for other characteristics associated with who receives surgery," said Dr. Whitlock. "The HRS has been an incredible resource for understanding health and aging in America."

The researchers separated the patients—all of whom were at least 65 years old—into two groups: "catheterization" with 1,921 (62%) and "heart surgery" with 1,184 (38%). In the analysis, heart surgery was not associated with additional memory decline; researchers found that surgery participants showed little difference (-.021 memory units, equal to 4.6 months of cognitive aging) in pre- to post-procedure memory

Brain Health Not Affected by Major Heart Surgery

Newswise — CHICAGO—Patients who undergo heart surgery do not experience major memory changes—either better or worse—when compared with those who have a much less invasive, catheter-based procedure, according to a study



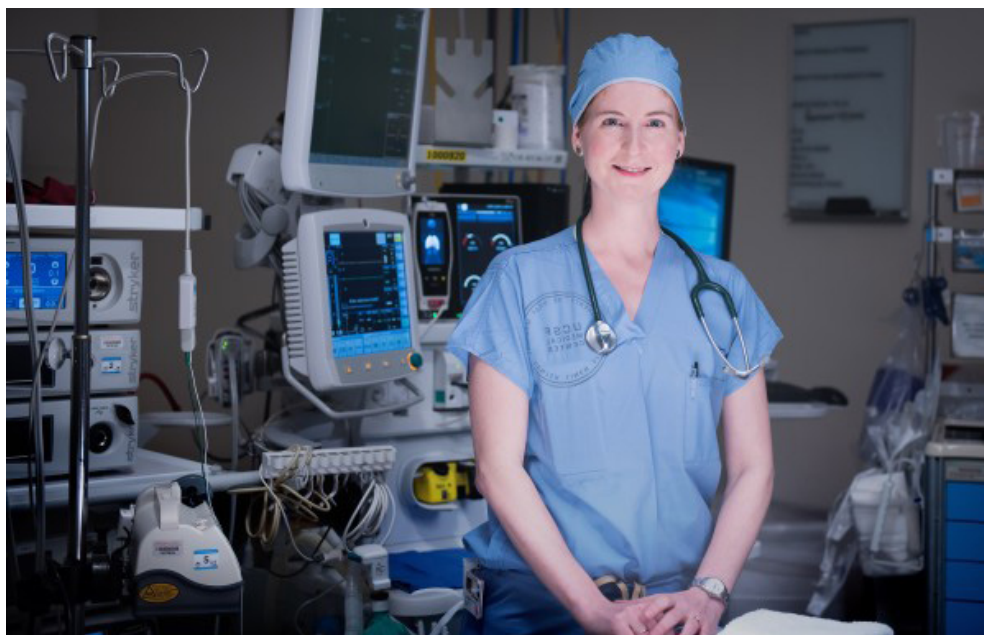Ninth Annual Fetal Echocardiography and Fetal Cardiac Screening Symposium at UCLA: *Pearls From The Masters*

Course Director: Mark Sklansky, MD

Saturday, October 26, 2019

www.cme.ucla.edu/courses/event-description?registration_id=302009





Elizabeth Whitlock, MD, from the University of California, San Francisco.

compared with those undergoing catheterization. “For a 75-year-old person, this translated into a very small 0.26% increased risk of his/her inability to manage finances independently and a 0.19% increased risk of being unable to manage medications independently,” said Dr. Whitlock.

“We expected to find a bigger difference in the surgery group, since there are many anecdotes about serious cognitive decline after heart surgery,” said Dr. Whitlock. “Our results are different for several reasons, one being that our follow-up is up to two years after surgery, to account for the fact that people may improve over time.”

In addition, the study design facilitated results that were not necessarily influenced by common factors such as pre-procedure anxiety, post-procedure pain, opioid use, and hospitalization-related stress. Dr. Whitlock explained that most participants completed cognitive testing well before the heart procedure and then again after a substantial recovery period following the procedure. This strategy reduced the risk that results would be affected by these issues. Importantly, researchers also compared like groups of patients—older adults with heart disease. Many previous studies have compared heart surgery patients with healthy patients who do not have heart disease.

“Since patients aren’t choosing between ‘surgery for heart disease’ and ‘no heart disease,’ it isn’t fair to compare the memory outcomes of these two groups,” said Dr. Whitlock. “Our findings suggest that there isn’t a major long-term impact when these two methods of correcting serious heart problems are compared. We think this is because severe heart disease itself probably has a cognitive impact.”

The American Heart Association reports that approximately 92 million people in the US suffer from some form of cardiovascular disease, with almost eight million people undergoing heart surgery or other related procedures each year. Coronary artery bypass grafting (CABG) is one of the best known and most effective surgeries of the modern age. While it is very safe, there also are risks associated with the operation. In fact, CABG is commonly blamed for a loss of memory and thinking skills, also known as postoperative cognitive decline (POCD), especially among older adult patients.

While it is not known for certain what causes POCD, researchers explained that factors such as small strokes that happen during surgery, the impact of inflammation from tissue trauma, and pain medications may have a role. Disrupted sleep, delirium, infections, and physical inactivity also may contribute.

Rady Children's

Hospital
San Diego

EP/Pacemaker Nurse

We are seeking a candidate to replace our retiring EP Nurse expert at Rady Children's Hospital San Diego.

Position includes:

- Pacemaker/device clinic and programming (320 active patients)
- Ambulatory monitoring surveillance
- Patient care coordination including young adult CHD patients
- Channelopathy and EP lab database management
- EP lab recording
- Nursing and fellow education
- Opportunities for research involvement

Travel to annual HRS meeting included.

Contact with letter of interest and CV:

James Perry, MD
jperry@rchsd.org

Matt Williams, MD
mwilliams@rchsd.org



PICS-AICS

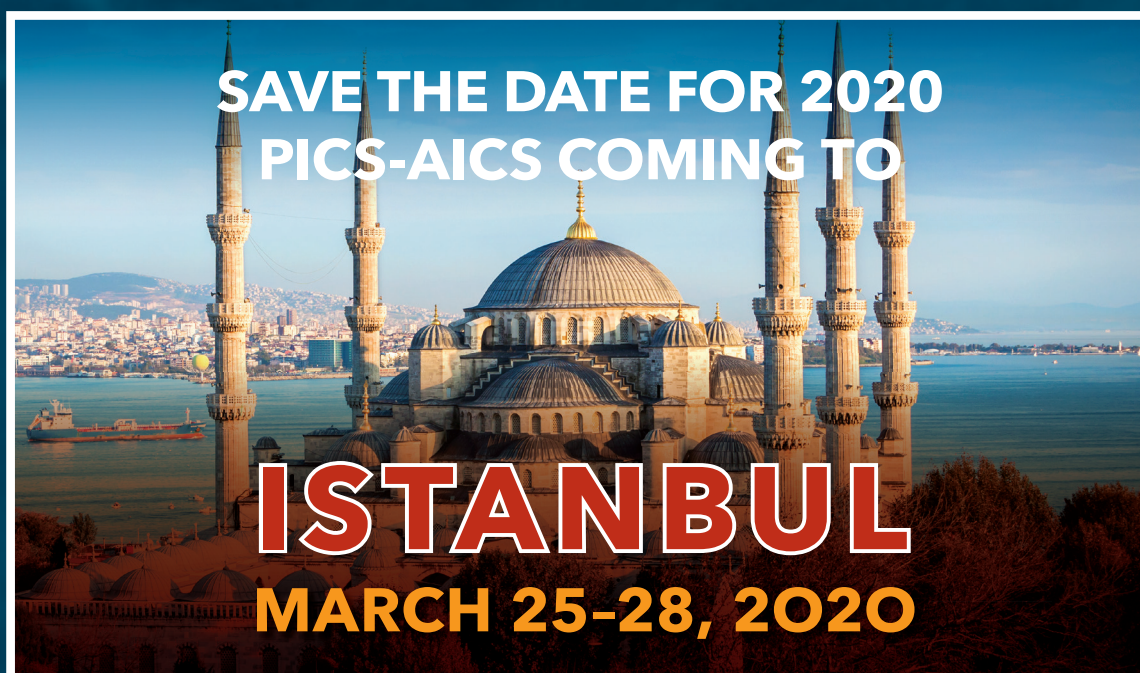Pediatric and Adult Interventional Cardiac Symposium

SAVE THE DATE SAN DIEGO

MARRIOTT MARQUIS - SAN DIEGO MARINA

SEPTEMBER 4-7, 2019

Focusing on the latest interventional catheter strategies for congenital and structural heart disease in children and adults.



WWW.PICSYMPOSIUM.COM

"Most of these factors are temporary, so while they may explain an initial cognitive decline seen in the weeks after a major surgery, cognition should gradually improve as the contributors resolve," said Dr. Whitlock. "That's why this approach—looking at up to 2 years after surgery—is a very important way to look at the 'old problem' of POCD."

This research was funded by the *National Institute of General Medical Sciences* and the *National Institute on Aging*, both part of the *National Institutes of Health*, and the *Foundation for Anesthesia Education and Research*.

Michele Lossius, MD, Appointed Chief Quality Officer for UF Health Shands Hospitals, Clinics

Gainesville, Fla. — Michele Lossius, MD, has been appointed Chief Quality Officer for the UF Health Shands Hospitals and clinical programs.

Lossius has a long, accomplished history with UF Health: She joined the pediatric critical care division in 2006 and is now a UF College of Medicine associate professor and pediatric physician. She was promoted to Division Chief of



Michele Lossius, MD, Chief Quality Officer for UF Health Shands Hospitals, Clinics

Pediatric Hospital Medicine in 2013 and has served as the Physician Director of Quality and Safety for Pediatrics. Lossius also earned her undergraduate and medical degrees from UF and completed residency training in pediatrics at UF Health Shands Hospital.

"I am incredibly excited about this opportunity and humbled by the outpouring of support by colleagues across the various disciplines of care. We have a wonderful organization that seeks to be innovative in responding to today's challenges in health care. I look forward to being a part of those solutions," Lossius said.

In the Chief Quality Officer role she assumed on Jan. 7, Lossius will provide strategic oversight for quality and patient-centered improvement efforts for the Gainesville hospitals and hospital-run outpatient programs. She will collaborate with staff in clinical risk management, patient experience, accreditation and clinical analytics through the UF Health Sebastian Ferrero Office of Clinical Quality and Patient Safety. Additionally, Lossius will support and work with physician directors of quality and quality liaisons across the organization.

She succeeds Eric Rosenberg, MD, a UF Health Shands associate Chief Medical Officer and College of Medicine professor, who served as interim Director of Quality.

"Dr. Lossius has the many important attributes that are needed in a chief quality officer, including substantial experience caring for patients and immersing herself in quality and safety roles throughout her career," said Ed Jimenez, CEO of UF Health Shands.

Lossius will guide organizational efforts to achieve outstanding performance on key quality and safety metrics, integrate residents in quality and safety work, engage patients and families, and help maintain a positive culture of quality improvement. She will also be responsible for promoting a unified approach to quality and safety goals among executive leaders, nursing and operations teams and College of Medicine clinical faculty and residents.



General Pediatric Cardiologist

The Pediatric Cardiology Center of Oregon is recruiting a **BC/BE FT GENERAL PEDIATRIC CARDIOLOGIST** to join the private practice of five Pediatric Cardiologists located in Portland, OR.

The Pediatric Cardiology Center of Oregon works with Legacy's Randall Children's Hospital and their pediatric CV Surgery team and are associated with multiple hospital systems throughout the state of Oregon and Washington. We have a comprehensive team that includes a cardiac interventionist providing transcatheter valve replacement (Melody Valve), ASD and VSD devices, an EP specialist experienced in ablations and device implants, a large fetal program and a Cardiac CT/MRI program.

In addition to our main office in Portland, our physicians provide outreach to multiple sites across Oregon and SW Washington. The group and surgical program also provides services to children from Alaska and has an active bloodless surgery program.

Candidates must be able to read and perform transthoracic and transesophageal echocardiograms. The group is looking for a full-time, salaried position with call, post-op and hospitalist responsibilities. Visit our site www.pccoforegon.com for more information about our clinic.

Please send curriculum vitae, cover letter, recommendation letters, and questions to: amandal@pccoforegon.com



Pediatric Interventional Cardiologist

Exceptional care for children with cardiac needs in the Capital District of New York has been provided for over 50 years by a team at Albany Med and the Bernard & Millie Duker Children's Hospital. We are excited to further the work of this great team with the opportunity to expand with the addition of a second pediatric interventional cardiologist: BC/BE Interventional Pediatric Cardiologist with the ability to provide consultation and care in the operating room and catheterization laboratory. This individual would also be expected to develop a practice of congenital heart patients and provide care for them in the outpatient setting as well with a role in general cardiology practice, the proportion of which to be determined. Clinical care may include Satellite Clinics throughout the Albany Med region which comprises 25 counties and 740,000 children and young adults up to age 21. On-call responsibilities include being a consultant in the post-operative PICU, caring for service patients on the ward, and providing interventional and diagnostic catheterizations. Candidates will partner with 5 Pediatric Cardiologists, and an outstanding experienced surgeon who has been the Director of our very highly rated program in Congenital Cardiac Surgery for 19 years. The program has capability to perform all state-of-the-art imaging including fetal, TTE, TEE, CMRI and CTA. This individual should possess leadership skills and desire to advance into a leadership position within the program.

Albany Medical Center Hospital is a large academic Medical Center in Albany, New York, the state capital. It is a level I Trauma Center and the regional hub for all adult and pediatric specialties. The Bernard and Millie Duker Children's Hospital, which houses a 60 bed NICU, 19 bed PICU with an embedded Pediatric Cardiac Unit, and a new pediatric emergency department that opened in 2018, is the site of inpatient care rendered by the division. Albany Medical College is a private medical school, and a nondiscriminatory AA/EOE institution (minorities and women are encouraged to apply). The successful candidate will enjoy many opportunities for teaching house staff and medical students and will be eligible for a faculty appointment in Albany medical College, rank will be dependent on qualifications, and experience.

Located at the heart of New York's Capital Region, Albany is a culturally and environmentally diverse area that is home to nearly 1,000,000 residents. The 3 cities of the capital region—Albany, Schenectady, and Troy, and their suburbs offer a range of affordable, safe, and comfortable neighborhoods with quality schools and active community groups. Albany, the capital New York State, is home for the state University in Albany, the School of Public Health, Albany College of Pharmacy, Albany Law School, and multiple private colleges, and offers a wide variety of culturally events. It is within easy driving distance to New York City, Boston, and Montréal, as well as the Adirondack Mountains, Lake Placid, Saratoga, and Lake George. It is a wonderful place to raise the family and enjoy activities related to all 4 seasons.

Interesting candidates should submit a letter of interest and curriculum vitae to:

Barbara E. Ostrov, MD

Martha Lepow Professor and Chair, Department of Pediatrics
Chief of Service, Bernard & Millie Duker Children's Hospital
22 New Scotland Ave, MC 24
Albany, NY 12208
ostrovb@amc.edu

Valerie D'Aloia

Albany Medical College Physician Recruitment
47 New Scotland Ave, MC57
Albany, NY 12208
518-262-1333
daloia@mail.amc.edu

Her quality and safety experience includes participating in team performance training that aims to improve patient care and a program that develops skills for teaching quality improvement and patient safety to medical students, residents and other clinicians. She also completed the Patient Safety Executive Development Program at the Institute for Healthcare Improvement and the Intermountain Advanced Training Program in Healthcare Delivery Improvement.

As Pediatric Hospital Medicine Division Chief, Lossius has led novel and innovative programs in education and safety. Clinically, she is involved with national projects related to bronchiolitis management, adverse drug events and fever in newborns. Lossius worked as the pediatrics Physician Director of Quality and Safety to reduce variation in care, decrease length of stay, establish protocols and develop strong working relationships across the institution.

Gore Cardioform ASD Occluder Receives FDA Approval

W. L. Gore & Associates (Gore) announced the U.S. Food and Drug Administration's (FDA's) premarket approval (PMA) of the Gore Cardioform ASD Occluder for the percutaneous closure

of ostium secundum Atrial Septal Defects (ASDs). The FDA approval was supported by data collected from the pivotal stage of the Gore ASSURED Clinical Study, which demonstrated 100 percent closure success at the six-month evaluation in patients with a successful implant.

The pivotal study evaluated the safety and efficacy of ASD closure using the Gore Cardioform ASD Occluder in 125 patients with evidence of right heart volume overload demonstrating the need for defect closure. The study involved patients between the ages of 2 and 84, across 22 investigation sites, including 15 children's hospitals. The pivotal study met its safety, closure and technical success primary endpoints.

"The FDA approval of the Gore Cardioform ASD Occluder is a significant milestone for innovation in the minimally invasive treatment of ASDs," said Matthew J. Gillespie, MD, Children's Hospital of Philadelphia, Co-Principal Investigator of the ASSURED Study. "This soft, conformable device was not previously available for this range of defects but is now an option for larger defects that typically have a greater risk for complications, including right heart enlargement, atrial fibrillation and pulmonary hypertension. The ability to retrieve and reposition the Gore Cardioform ASD Occluder helps me ensure proper positioning and offers me confident closure."

The device's anatomically adaptable waist conforms to the defect to close ASDs from 8 to 35 mm in diameter, including those without a retro-aortic rim, by facilitating optimal tissue ingrowth, while maintaining thromboresistance. As the latest extension to the Gore Cardioform Occluder family, it builds on a legacy of safety outcomes.

In addition to the Gore Cardioform ASD Occluder, the occluder portfolio also includes the Gore Cardioform Septal Occluder, which is indicated for ASD closure for defects up to 17 mm and received FDA approval in 2018 for Patent Foramen Ovale (PFO) closure to prevent recurrent ischemic stroke. Approval for the Gore CARDIOFORM Septal Occluder was supported by positive results announced in May 2018 from the Gore REDUCE Clinical Study, which demonstrated the safety and efficacy of PFO closure with a Gore device plus antiplatelet therapy compared to antiplatelet therapy alone in patients with a PFO and history of cryptogenic stroke.

For more information: www.gore.com




NEONATOLOGY TODAY

Peer Reviewed Research, News and Information in Neonatal and Perinatal Medicine

Neonatology Today is interested in publishing manuscripts from Neonatologists, Fellows, NNPs and those involved in caring for neonates on case studies, research results, hospital news, meeting announcements, and other pertinent topics.


Please submit your manuscript to: LomaLindaPublishingCompany@gmail.com



Subscribe Electronically to CCT

Free on the Home Page

www.CongenitalCardiologyToday.com



Recruit with CCT

Recruitment Advertisements are Listed

- In print and electronic monthly issue
- On CCT's website
- In CCT's monthly email blast

Contact: Kate@cct.bz



CONGENITAL CARDIOLOGY TODAY

Founder & Senior Editor

Tony Carlson
Tony@cct.bz

Publisher & Editor-in-Chief

Richard Koulbanis

Co-Founder & Medical Editor

John W. Moore, MD, MPH
Dr.John@cct.bz

Senior Editor of Special Projects

Kate Baldwin
Kate@cct.bz

Staff Editor

Loraine Watts

Staff Editor & Writer

Virginia Dematatis

Editorial Board

Teiji Akagi, MD
Zohair Al Halees, MD
Mazeni Alwi, MD
Felix Berger, MD
Fadi Bitar, MD
Jacek Bialkowski, MD
Mario Carminati, MD
Anthony C. Chang, MD, MBA
John P. Cheatham, MD
Bharat Dalvi, MD, MBBS, DM
Horacio Faella, MD
Yun-Ching Fu, MD
Felipe Heusser, MD
Ziyad M. Hijazi, MD, MPH
Ralf Holzer, MD
Marshall Jacobs, MD
R. Krishna Kumar, MD, DM, MBBS
John Lamberti, MD

Gerald Ross Marx, MD
Tarek S. Momenah, MBBS, DCH
Toshio Nakanishi, MD, PhD
Carlos A. C. Pedra, MD
Daniel Penny, MD, PhD
James C. Perry, MD
Shakeel A. Qureshi, MD
P. Syamasundar Rao, MD
Andrew Redington, MD
Carlos E. Ruiz, MD, PhD
Girish S. Shirali, MD
Horst Sievert, MD
Hideshi Tomita, MD
Gil Wernovsky, MD
Zhuoming Xu, MD, PhD
William C. L. Yip, MD
Carlos Zabal, MD

© 2019 by Congenital Cardiology Today
(ISSN 1554-7787-print; ISSN 1554-0499-online)
Published monthly. All rights reserved.

Statements or opinions expressed in Congenital Cardiology Today reflect the views of the authors and sponsors, and are not necessarily the views of Congenital Cardiology Today.

Official Publication of the CHiP Network

CHIP NETWORK
CONGENITAL HEART INTERNATIONAL PROFESSIONALS

The congenital heart professionals network exists to facilitate communications between congenital heart professionals locally, regionally, and globally.

JOIN TODAY

www.chip-network.org



Funded by Cincinnati Children's Heart Institute



ARNOLD PALMER
HOSPITAL
For Children

Director of Adult Congenital Heart Disease

Arnold Palmer Medical Center
Orlando Health

The Heart Center at Arnold Palmer Hospital for Children seeks a Director of Adult Congenital Heart Disease. The Heart Center is Orlando's most established tertiary care cardiac program with consistently proven excellent clinical outcomes. The surgical team has a proven track record of excellent outcomes in complex operations on neonates, children, and young adults. As a part of Orlando Health, The Heart Center enjoys an excellent working relationship with the Orlando Health Heart Institute that serves our adult cardiac community. Currently adults with congenital heart disease are cared for as inpatients at one of Arnold Palmer Hospital for Children or Orlando Regional Medical Center. Two providers currently manage adults with congenital heart disease as outpatients. Maternal and fetal issues are actively managed at Winnie Palmer Hospital for Women and Babies with an active regional Maternal Fetal Medicine program.

As director, the position requires board certification in adult congenital heart disease. The director will be responsible to the chief of cardiology and work with the directors of the Heart Center to continue to formally develop the adult congenital heart program in concert with our efforts to guide transition of the pediatric patient to adult based care. The director will champion a goal of full ACHD accreditation and be committed to quality assessment and improvement. The preferred candidate will have prior clinical and leadership experience. Compensation, including competitive benefits, is commensurate with experience.

Orlando Health is one of Florida's most comprehensive private, not-for-profit healthcare networks. The diversified health system encompasses eight hospitals, a large multispecialty medical group (Orlando Health Medical Group), expanding community clinic locations and a clinically integrated network (Orlando Health Network). Orlando Health has total revenues in excess of \$3.2 billion annually, over 19,000 employees and a medical staff of more than 3,200 physicians. In 2018 15,022 births occurred at Winnie Palmer Hospital which houses a Women's Intensive Care Unit and a 142 bed NICU. Arnold Palmer Hospital for Children is home to 156 inpatient beds including a dedicated pediatric cardiac intensive care unit. Complete invasive and non-invasive imaging is available including CT and MRI. Caring for our patients are 130 pediatric subspecialty physicians and 65 advanced practice professionals.

Orlando combines to create one of Florida's most appealing areas for business, living and recreation. U.S. News & World Report analyzed 100 metro areas in the United States and recently ranked Orlando 40th for Best Places to Live. While Florida has a reputation for being a retirement hot spot, nearly two-thirds of Orlando's residents are of working age with annual growth of young families to the region.

Inquiries can be directed to:

David Nykanen, MD

Co-Director, The Heart Center

Orlando Health's Arnold Palmer Hospital for Children

David.Nykanen@OrlandoHealth.com