

CONGENITAL CARDIOLOGY TODAY

News and Information for Pediatric and Congenital Cardiovascular Physicians and Surgeons

Vol. 5 / Issue 1
January 2007
North American Edition

WWW.CONGENITALCARDIOLOGYTODAY.COM

INSIDE THIS ISSUE

Early Experience With A Miniaturized Three Dimensional Matrix Transducer In Children

by *Girish S. Shirali, MBBS,
FACC, FAAP*

~Page 1

Holiday in Southeast Asia leads to Medical Mission in Siem Reap, Cambodia

by *Susan T. Grossfeld, BS, and
Paul D. Grossfeld, MD*

~Page 7

DEPARTMENTS

Medical News, Products and Information

~Page 12

CONGENITAL CARDIOLOGY TODAY

9008 Copenhaver Drive, Ste. M
Potomac, MD 20854 USA
Tel: +1.301.279.2005
Fax: +1.240.465.0692

Editorial Offices:
16 Cove Road, Ste. 200
Westerly, RI 02891 USA

www.CongenitalCardiologyToday.com

© 2006 by Congenital Cardiology Today (ISSN 1554-7787-print; ISSN 1554-0499-online). Published monthly. All rights reserved. Congenital Cardiology provides timely news and information for pediatric and congenital cardiologists. Statements or opinions expressed in Congenital Cardiology Today reflect the views of the authors and sponsors, and are not necessarily the views of Congenital Cardiology Today.

EARLY EXPERIENCE WITH A MINIATURIZED THREE DIMENSIONAL MATRIX TRANSDUCER IN CHILDREN

By *Girish S. Shirali, MBBS, FACC, FAAP*

Introduction

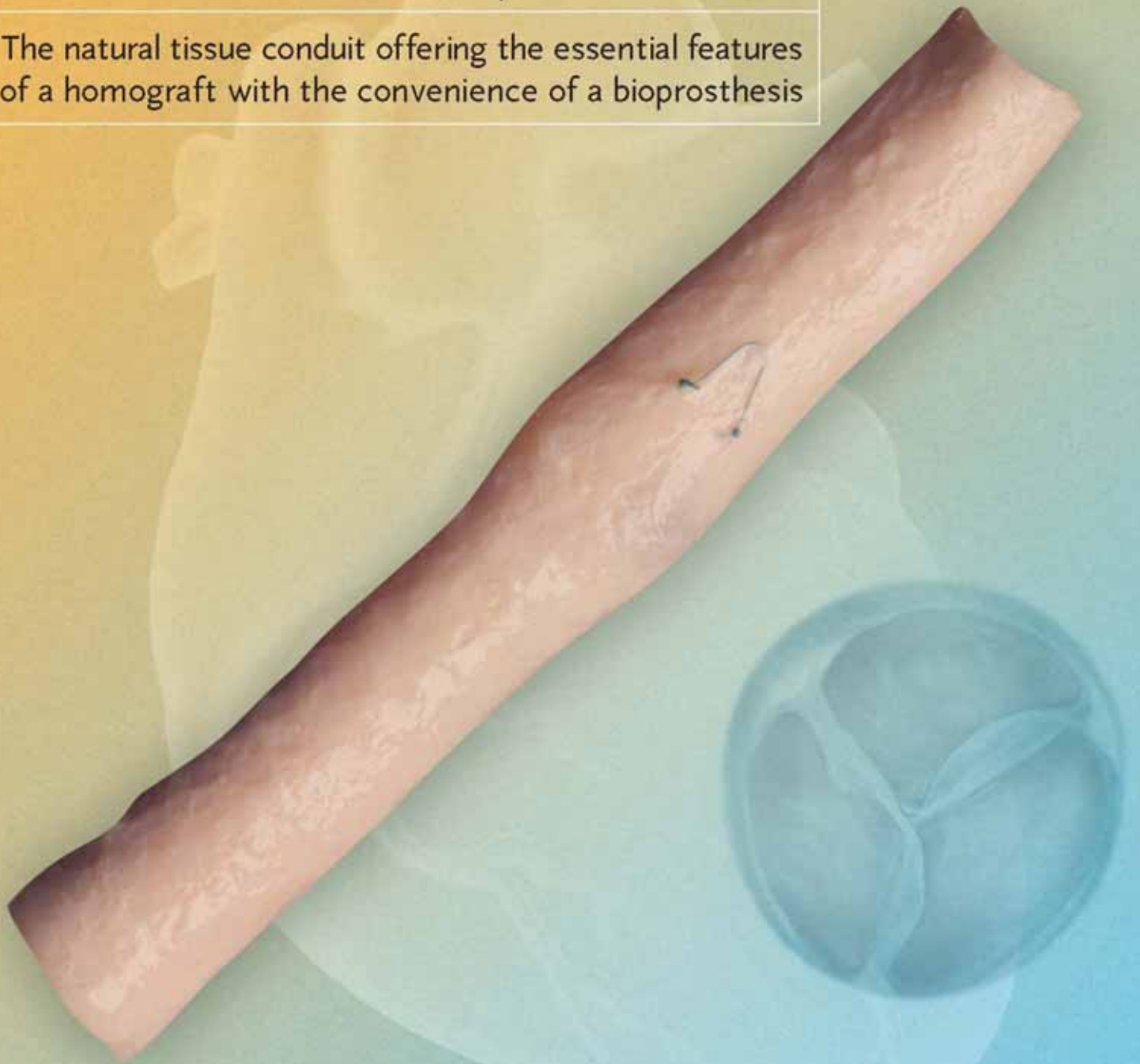
Complex intra-cardiac anatomy and spatial relationships are inherent to congenital heart defects (CHD). Until recently, our ability to image the heart by echocardiography has been limited to two-dimensional (2D) techniques. Advances in transducer technology, beam-forming and computer processing power and speed have led to significant improvements in spatial and temporal resolution using 2D echocardiography (2DE). However, 2DE has fundamental limitations. The nature of a 2D slice, which has no thickness, necessitates the use of multiple orthogonal 'sweeps'. The echocardiographer then mentally reconstructs the anatomy, and uses the structure of the report to express this vision. This means that the only 3D image of the heart is the 'virtual image' seen by the echocardiographer alone. It is not easy for an untrained, nevertheless interested observer to understand the images obtained in the course of a sweep: expert translation is required. As a corollary to this, 2DE techniques do not lend themselves to quantitation of cardiac structures of irregular shapes; it is impossible to quantitate a virtual image.

Recognition of these limitations of 2DE led to burgeoning research and clinical interest in the modality of three-dimensional echocardiography (3DE). Early reconstructive approaches were based on 2DE acquisitions and subsequent stacking of 2DE images to recreate a 3D dataset. However, the need for offline processing imposed fundamental limitations on the practicality of these approaches. More recently, the focus has shifted towards the acquisition of a 3D 'wedge' or trapezoid in real time. New transducer technology has enabled this, evolving from the familiar phased array of 2DE (with 128 elements) to the matrix array that is designed for 3DE (with 2500 to 3000 elements). 3DE matrix array transducers have been commercially available since the spring of 2003. Given the early phase of technology development at the time, it is not surprising that these transducers were heavy, with a large footprint, low frame rates and limited features. The inherently low frequency of these transducers translated into poor spatial resolution. As a result, the pediatric community continued to view 3DE with skepticism. The gap between existing imaging technologies and the ideal imaging modality has remained large. But what is ideal?

Recruitment ads
See pages 6, 9, 10, 11

CONTEGRA[®] Pulmonary Valved Conduit

The natural tissue conduit offering the essential features of a homograft with the convenience of a bioprosthesis



This device has been approved as a humanitarian use device in the U.S.

CONTEGRA[®] Pulmonary Valved Conduit

Indications: See *Humanitarian Use Device section below. **Contraindications:** - Patients 18 years and older. • If, after assessment of the risk to benefit ratio by the physician, superior clinical results are suggested by presently established alternative medical or surgical techniques. **Warnings/Precautions/Side Effects:** Acceptable clinical performance has been established for the Contegra conduit in pediatric patients under the age of 10. Because of the possibility that complications of the device could become apparent only after extended use, a benefit-risk consideration of the long-term use of the Contegra conduit in pediatric patients over 10 years of age is particularly important. General complications reported with valved conduits and biological tissue valves implanted in the heart include: hemorrhage, bleeding diathesis due to use of anticoagulants, residual or increasing transvalvular gradients, progressive neointimal thickening and peeling, progressive stenosis and obstruction, progressive pulmonary hypertension, graft infection, endocarditis, regurgitation, hemolysis, valve malfunction, physical or chemical deterioration, thromboembolism, thrombus, conduit dilatation. For additional information, please refer to the Instructions For Use provided with the product. CAUTION: Federal law (USA) restricts this device to sale by or on the order of a physician.

***Humanitarian Use Device:** Authorized by Federal law for use in patients under 18 years of age for correction or reconstruction of the Right Ventricular Outflow Tract (RVOT) in the following congenital heart malformations: Pulmonary Stenosis, Tetralogy of Fallot, Truncus Arteriosus, Transposition with Ventricular Septal Defect (VSD), Pulmonary Atresia. In addition, the Contegra Pulmonary Valved Conduit is indicated for the replacement of previously implanted but dysfunctional pulmonary homografts or valved conduits. The effectiveness of this device for these uses has not been demonstrated.

UC200703776 EN



The Ideal Modality

The ideal modality for non-invasive imaging of the heart would have the following characteristics:

For the echocardiographer:

- The modality should be able to image the entire region of interest in three dimensions in real time.
- The modality should be integrated into current imaging equipment.
- The modality should be portable and easily performed and repeated.
- Spatial and temporal resolution should be of diagnostic quality.
- It should be adaptable to patients of varying sizes and heart rates.
- The modality should overcome the limitations imposed by the two-dimensional display.
- Images should be easily viewed, manipulated and quantified at any time, and should be accessible from any PC.

For the hospital:

- The modality should be financially viable.
- It should lead to improvements in work flow.
- It should be integrated into existing image management systems.

For the operator:

- The modality should have a realistic learning curve.
- It should be fun to use and easy to interpret.
- The ergonomics of the modality should be reasonable.

For the surgeon:

- Images should be amenable to post-processing. This provides the potential for viewing perspectives that may be critical for surgery, but not necessarily obvious to others.

For the patient:

- The modality should provide valuable additional information.
- It should provide the potential for making a real difference to the patient's care and outcome.
- It should be quick, risk-free and easy.

For the researcher:

- The researcher should be able to rely on the industry's commitment (in its ongoing research and development) to the new technology.
- The modality should yield new information that is important enough to make the researcher's proposals competitive for grant funding.

While the ideal modality as detailed above does not exist currently, recent advances hold great promise for the future. This review focuses on the new pediatric matrix transthoracic X7-2 3DE transducer (Philips Medical Systems, Andover, MA), which our laboratory has helped to develop, optimize and validate.

Advances in Computer Technology

In 1965, Gordon Moore suggested that the number of transistors per integrated circuit would grow exponentially, doubling every couple of years [1]. In the subsequent 40 years, the number of components actually doubled every 18 months or so - and thus the power of central processing unit (CPU) chips also doubled at that rate. Concomitantly, other components of computers including switching, buses, memory and disk density have all increased exponentially in both capacity and speed. As a result, the availability of high-powered, miniaturized computing power has increased dramatically. This has been an important contributor to the advances in pediatric echocardiographic imaging.

Piezoelectrics: The Basics

The piezoelectric material in an ultrasound transducer is a fundamental determinant of system image quality. Piezoelectric transducer elements are responsible for delivery of ultrasound energy into the scanned tissue and for converting returning ultrasound echoes into electric signals. Their coupling efficiency in converting electrical energy to mechanical energy or vice versa is a key determinant of image quality, Doppler sensitivity and penetration. To create an overall piezoelectric effect, these elements must be subject to the application of an external electric field to align dipoles within polycrystalline materials. For almost 40 years, a ceramic polycrystalline material, PZT (lead-zirconate-titanate) or PZT composites, has been the standard piezoelectric material used in medical imaging. This material is a uniform powder that is mixed with an organic binder and baked into a dense polycrystalline structure. At its best, it achieves ~ 70% alignment of dipoles due to imperfect alignment of the individual dipoles. This leads to a corresponding constraint in the electromechanical coupling efficiency of the material.



For information, please call 1-800-BRAUN2 (227-2862)

www.bbraunusa.com



Working Together to Develop a Better Tomorrow

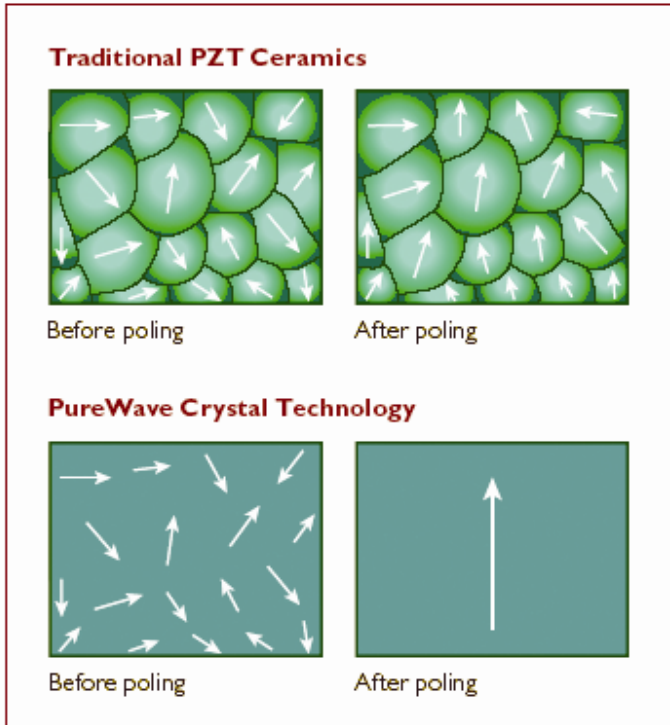


Figure 1. Orientation of dipoles during poling of traditional PZT (lead-zirconate-titanate) ceramics versus PureWave crystal. (Image: courtesy, Philips Medical Systems).

Advances Specific to the X7-2 Transducer

The X7-2 transducer (Philips Medical Systems, Andover, MA) utilizes PureWave crystal technology, which represents a completely new type of piezoelectric material. This technology involves growing crystals from a molten ceramic material, resulting in a homogenous crystal with fewer defects, lower losses and no grain boundaries. When these crystals are poled at the preferred orientation(s), near perfect alignment of dipoles (~100%) is achievable (see Figure 1) resulting in dramatically enhanced electromechanical properties. The efficiency of converting electric-to-mechanical energy improves by as much as 68-85% when compared to PZT ceramics currently used in ultrasound transducers. These efficiencies translate into the ability to increase miniaturization, as exemplified by the X 7-2 transducer, which contains 2,500 active elements (see Figure 2).

3DE in CHD: Our Laboratory's Role

Over the past four years, our laboratory has been exploring the applicability of 3DE techniques to CHD. Our prior work on 3DE, albeit using earlier-generation, low frequency transducers, has shown the promise of this modality. We initially performed descriptive studies




Figure 2. The pediatric miniaturized matrix 3D X7-2 Transducer (Image: courtesy, Philips Medical Systems).

that evaluated the role of 3DE in patients with atrioventricular septal defects, aortic arch anomalies and in guiding endomyocardial biopsies in children [2-4]. More recently, we have critically evaluated tools that are available for 3DE quantification of left ventricular volumes and ejection fraction [5]. We have demonstrated that these tools provide the ability to rapidly quantitate LV function in a reproducible manner, and that there is a negotiable learning curve with these tools. However, the transducers that have been available to date have had limited acceptance in pediatrics due to their weight, large footprint, low imaging frequency and low frame rates. Since 2005, we have been involved in the development, optimization, evaluation and validation of the X7-2 MHz miniaturized matrix 3DE transducer. This transducer has been optimized for pediatric applications in terms of size, footprint, imaging frequency, near-field resolution and frame rates.

Imaging With the X7-2 Transducer

The X7-2 transducer has excellent ergonomics: it weighs 65 grams (approximately 2 oz.) and has a footprint that measures 1.7x1.3 cm. We have been able to obtain high quality 3D images on patients ranging from neonates to small adults (see Figure 3). Image



DON'T BUY ANY MORE MEDICAL EQUIPMENT - YET...

MD Advantage Inc. will work with you to analyze your needs and the marketplace to help you make a well informed and cost effective decision for your practice. Spend more time with your patients and less time with sales people. Call MD Advantage today!

MD Advantage, Inc. ♦ 1-888-224-2234 ♦ www.MDAdvantageMedical.com

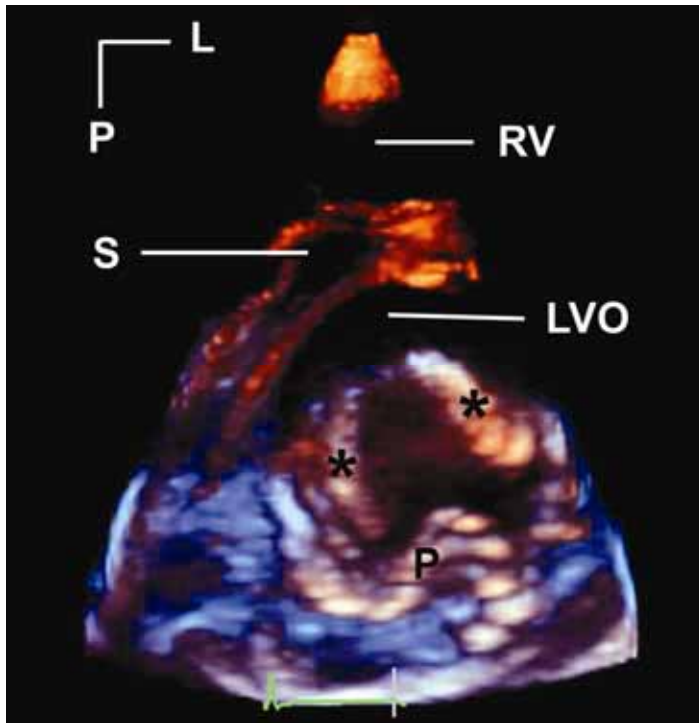


Figure 3. Parasternal short axis view of an isolated cleft of the anterior mitral leaflet. The two edges of the cleft are marked by asterisks. The posterior mitral leaflet has a prominent middle scallop (P). L, left; LVO, left ventricular outflow; P, posterior; RV, right ventricle; S, septum.

resolution in the near field has been outstanding. The quality of 3D color flow imaging, presented with the black and white image suppressed, thus providing an 'echocardiographic angiogram'[3], has been excellent (see Figure 4). Frame rates for Live 3DE have ranged from 24 to 46 frames per second, and frame rates for Full Volume 3DE have ranged from 23 to 83 frames per second. Frames rates for 3DE Color Flow have ranged from 19 to 33 frames per second. We have found 3DE to be particularly useful in evaluating complex intracardiac anatomy to guide surgical options. The X7-2 transducer has also provided excellent quality 2DE images, including gray-scale, color flow and pulsed wave Doppler.

Future Directions

The X7-2 transducer provides pediatric echocardiographers with a new array of imaging capabilities. Advances in software tools must keep pace with these advances. Existing tools allow easy quantification of LV systolic function. However, now that we have access to a digital dataset that contains the right ventricle, we would like to similarly quantify RV volume and systolic function. Similarly, the ability to capture a 3D dataset that includes all of the color flow across a

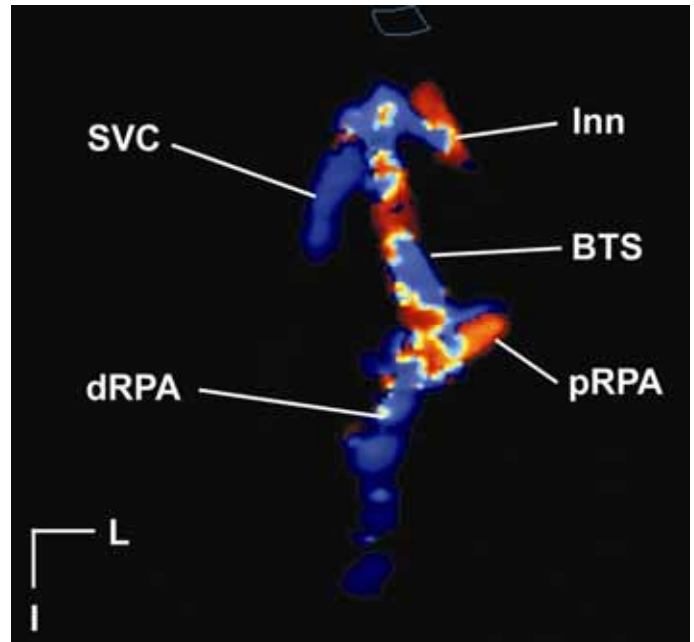


Figure 4. Suprasternal notch view: Echocardiographic 'angiogram' of a modified right Blalock-Taussig shunt (BTS). The grayscale component of the image has been suppressed. dRPA, distal right pulmonary artery; I, inferior; Inn, innominate artery; L, left; pRPA, proximal right pulmonary artery; SVC, superior vena cava.

valve leads to questions regarding reliable quantification of flows. The continuing evolution of such techniques will probably result in a paradigm shift in our ability to obtain quantitative information on our patients.

Challenges

The introduction of miniaturized new technologies is a technical challenge for industry, and a mental challenge for practitioners. Paradigm shifts can be intimidating for the busy echocardiographer and laboratory. New techniques must be evaluated, old paradigms re-examined, and inertia overcome as needed. Over the short term, the path of least resistance is that of the skeptic. What happens over the long term? Our community has now been empowered with a revolutionary transducer optimized for pediatric 3D applications (interestingly, there is not yet a 3D PureWave transducer optimized for imaging adults). How will we deal with this challenge?

Conclusions

The new 2-7 MHz 3DE transducer provided excellent image quality, and high temporal and spatial resolution in patients spanning a wide range of diagnoses and body sizes. The new

Fifteenth Charleston Symposium on Congenital Heart Disease

Embassy Suites Historic District, Charleston South Carolina USA
 May 2-4, 2007

Contact: Debbie Bryant (843) 792-3286, bryantd@musc.edu
http://www.musckids.com/heart/conferences/symposium_07.pdf



availability of high frame rates should potentially enable the wider application of 3DE quantitative methods to infants and children.

References

1. Moore, G. Electronic Magazine, p 114, April 1965. Referenced in: Excerpts from a conversation with Gordon Moore: Moore's Law. Intel Corporation.
2. Hlavacek AM, Chessa K, Crawford FA, Atz A, Shirali GS. Real-time three-dimensional echocardiography is useful in the evaluation of patients with atrioventricular septal defects. *Echocardiography* 2006;23(3):225-231.
3. Scheurer M, Bandisode VM, Ruff P, Shirali GS. Early experience with real-time

three-dimensional echocardiography for guidance of right ventricular biopsy in children. *Echocardiography* 2006;23(1):45-49.

4. Hlavacek AM, Lucas JF, Chessa K, Shirali GS. Three dimensional color flow Doppler echocardiography enhances visualization of the aortic arch. *Echocardiography*, 2006;23(10):860-864.
5. Baker GH, Flack EC, Hlavacek AM, Chessa KS, Fleming DM, Scheurer MA, Shirali GS. Variability and resource utilization of bedside three-dimensional echocardiographic quantitative measurements of left ventricular volume in congenital heart disease. *Congenital Heart Dis* 2006;1:318-323.

~CCT~



*Girish S. Shirali, MBBS, FACC, FAAP
Professor, Departments of Pediatrics
and Obstetrics/Gynecology
Director, Pediatric Echocardiography
Director, Fellowship Training
Medical University of South Carolina
Charleston, SC USA*

shiralig@musc.edu



**Arkansas Children's Hospital, Little Rock, AR
PEDIATRIC TRANSPLANT CARDIOLOGIST**



The Department of Pediatrics, Section of Cardiology, of the University of Arkansas for Medical Sciences College of Medicine located at Arkansas Children's Hospital in Little Rock, Arkansas, seeks candidates for an Assistant Professor (tenure track) position in the clinical-scientist pathway. M.D. degree and board eligibility/board certification in Cardiology is required. The position is available immediately, starting date is negotiable.

Cardiology offers state-of-the-art procedures and comprehensive post operative care to patients from Arkansas and the region. The Cardiac Catheterization team performs a variety of procedures including atrial septal defect closure, angioplasty with stent implantation, and blade and balloon atrial septostomy. Inpatient Cardiology and Intensive Care provides attending coverage of the cardiac intensive care service including post-operative care. The Cardiac Transplant program is recognized at one of the leading cardiac transplant programs in the United States. Cardiology Clinics and Outreach conduct monthly patient clinics in Fayetteville, Fort Smith, Texarkana, and Jonesboro.

The UAMS Department of Pediatrics employs over 195 faculty members and 75 residents. Arkansas Children's Hospital is among the largest children's hospitals in the United States. Located in the foothills of the Ozark Mountains, Little Rock offers Midwestern family values combined with the friendliness of the South, affordable housing, quality school options, a mild climate, excellent cultural and artistic venues, professional minor league sports, world class hunting, fishing and other outdoor recreational opportunities plus extraordinary natural beauty. With a population in excess of 500,000, Greater Little Rock offers the most desirable features of large cities without sacrificing ease of access and convenience. For more information, please see our website: www.uams.edu/pediatrics.

Interested individuals should contact:

**W. Robert Morrow, MD
Professor of Pediatrics
David and Stephanie Clark Chair in Pediatric Cardiology
UAMS College of Medicine
Arkansas Children's Hospital
800 Marshall, Slot 512-3
Little Rock, AR 72202-3591
Phone: (501) 364-1479; Fax: (501) 364-3667
morrowwilliamr@uams.edu**

HOLIDAY IN SOUTHEAST ASIA LEADS TO MEDICAL MISSION IN SIEM REAP, CAMBODIA

By Susan T. Grossfeld, BS, and Paul D. Grossfeld, MD

On July 27, 2006 an enthusiastic medical team from the University of California, San Diego and Rady Children's Hospital San Diego arrived in Siem Reap, Cambodia to volunteer their time and expertise to perform heart surgeries on children at the Angkor Hospital for Children (AHC). They also aimed to provide valuable education to the physicians and nursing staff. For the next week, this team would evaluate, operate on, and care for children from Siem Reap and neighboring provinces who had a patent ductus arteriosus.

Thanks to Variety Children's Lifeline's dedication to supporting medical missions for children in third world countries, as well as their commitment to hospital staff education and to achieving a self sustaining medical facility, a future mission to AHC will take place in the summer of 2007.

Variety Children's Lifeline is based in Solana Beach, California and was founded in 1982. Supported strictly by individual donations, Variety Children's Lifeline founder, Salah Hassanein, has supported previous missions to Chile, Nicaragua, India, Africa, Panama and Peru. With a major cardiology surgical hub opening in New Delhi, the opportunity to reach into Southeast Asia was ripe. Unknowing to Variety Children's Lifeline, this opportunity was about to present itself.

How this Mission Came About

In the fall of 2005, Dr. Paul Grossfeld, a pediatric cardiologist from UCSD and his wife Susan, were set to travel to Thailand on holiday. While arranging the vacation, Susan asked Paul if he would object to a "side trip to an undisclosed destination" for about 4 days. Being the good sport that he is, Paul had no objections.

Several major temples of interest are located just outside the village of Siem Reap, Cambodia's third largest city. While conducting some on-line research about the temples and Siem Reap, Susan found out about a small, privately funded children's hospital called Angkor Hospital for Children. The hospital's web site indicates its primary needs in the fields of infectious diseases and malnutrition. It is also in the process of developing a cardiology program. An e-mail was sent to the hospital director, Jon Morgan, indicating that Paul and Susan would be visiting



Figure 1: Dr. Paul & Susan Grossfeld arrive at Angkor Hospital for Children.

Siem Reap and were interested in volunteering. Mr. Morgan replied that because the days were few, he would prefer to arrange a simple visit to the hospital for them. With that, Susan informed Paul to "pack your stethoscope," but no further details about the side trip were presented. Within a few days of leaving for Southeast Asia, the destination of the "side trip" was revealed to Paul and his curiosity about Cambodia and the hospital began to peak.

About Angkor Hospital for Children

Angkor Hospital for Children is supported by the not-for-profit, New York based group, Friends Without a Border. Friends and Angkor Hospital for Children are committed to improving the health and future of Cambodia's children by providing pediatric care and medical education. Additionally, Angkor Hospital for Children is the only accredited teaching hospital in Cambodia. Currently, the outpatient department sees 300-500 patients per day and the hospital maintains 50 inpatient beds. Patients pay a nominal fixed fee per visit, but only if they can afford to. All treatment is free of charge after that. Angkor Hospital for Children's goal is to increase the number of properly trained healthcare professionals in the entire region, including training government healthcare workers from health centers and other hospitals. Since its inception in 1999, Angkor Hospital for Children has treated over 363,000 children and strives for Cambodian self-sufficiency. The plan is to turn over AHC to the Cambodian Ministry of Health with a highly trained all-Cambodian staff by 2007.

Angkor Hospital for Children is one of only two hospitals in Siem Reap province capable of providing pediatric surgical care. AHC

Cardiology
2007

10th Annual Update on Pediatric Cardiovascular Disease
New and Evolving Practices

February 21-25, 2007

Disney's Yacht & Beach Club Resort®

Lake Buena Vista, Florida USA

www.chop.edu/cardiology2007



Figure 2. PDA patient awaits her surgery. Photography by Daniel Rothenberg of AHC.

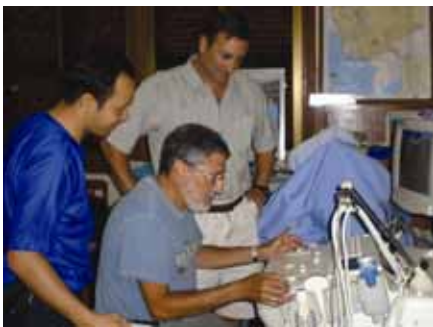

Figure 3. Dr. Ngeeth Pises of AHC, UCSD echo tech William Elias and Dr. Paul Grossfeld.

surgeons have performed a variety of operations, including acute trauma cases, tumors, orthopedic and hernia repairs. In 2005 the first cardiac surgeries (PDA ligations) were performed at AHC by a visiting cardiologist and cardiothoracic surgeon from Singapore.

The medical team at AHC has identified over 500 children with congenital heart defects, including 60 with PDA's. AHC does not have a trained cardiologist, cardiothoracic surgeon, or dedicated echo technologist. They do not have cardiopulmonary bypass or catheterization fa-

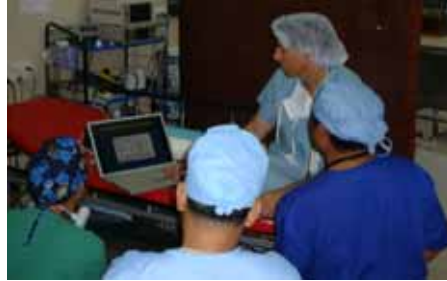

Figure 4. Dr. Mark Greenberg instructs Cambodian anesthesiologists.

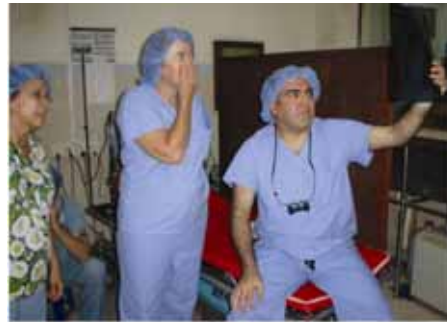

Figure 5. Cardiac surgery nurse practitioner Stephanie Moriarty, Dr. Jolene Kriett, and Dr. Michael Madani evaluate an x-ray for the next case.

cilities. The 5-year plan at AHC is to develop a cardiac surgical program that will include simple cardiopulmonary bypass cases. The demand for specialized cardiology care at AHC has been filled by a general pediatrician, Dr. Ngeeth Pises. He has taken it upon himself to learn as much as he can about cardiology and, as a result, self-trained. Echocardiograms are performed by a general radiologist, Dr. Luy Lyda, who has taken the initiative to learn how to perform pediatric echocardiograms.

Previously, AHC would refer its patients requiring surgery to neighboring countries and facilities. However, outcomes were suboptimal, and this was not a feasible financial option for most Cambodians. A



Figure 6. Susan Grossfeld with PDA patient and his brother.

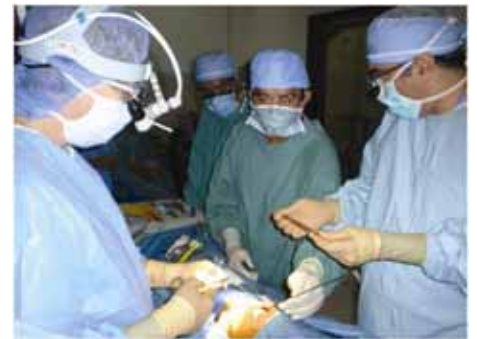

Figure 7. Dr. Jolene Kriett and Dr. Michael Madani offer instruction to AHC's surgeon Dr. Vann Thy.

small number of children have been sent to hospitals in Malaysia, Singapore and Thailand with the aid of limited private sponsorship. Located in the capital city of Phnom Penh is the Phnom Penh Heart Center, a facility capable of performing limited procedures. There was a 50% complication rate for PDA ligations performed at the Phnom Penh Heart Center. Compounding this high complication rate, the Heart Center charges \$1,500 USD per procedure. Although this amount may be small by U.S. standards, the majority of Cambodians cannot afford this fee.

Moved by the plight of AHC and the children of Cambodia, and inspired by the commitment, dedication and eagerness

B | BRAUN

For information, please call 1-800-BRAUN2 (227-2862)

www.bbraunusa.com



Working Together to Develop a Better Tomorrow

to learn on the part of the medical team at AHC, Dr. Grossfeld inquired about the opportunity to return to Cambodia with a team of medical professionals for the purpose of performing PDA ligations. The planning process began with hopes to return to Siem Reap by the end of 2006.

The Planning Process

While Paul assembled the medical team, his wife Susan set out to organize the logistics of this mission. Working closely with the executive staff, physicians, radiologist, anesthesiologist, general surgeon and the OR manager from AHC, Susan secured dedicated operating room time, coordinated the scheduling of potential cases for pre-op echocardiogram evaluations, identified the surgical and anesthesia needs, and collected the list of upcoming surgery candidates. The air travel, ground transportation and lodging accommodations fell quickly into place. Within 5 months of returning from Southeast Asia, Paul, Susan, and the rest of the medical team were set to travel to Cambodia, as the first American medical team to perform cardiac surgeries at Angkor Hospital for Children.

One of the keys to the efficient, rapid and successful planning process was the support, commitment, and competence the American team received from the staff at AHC. The only mode of communication with the Cambodian team was via e-mail, and this invaluable tool made it possible to share visual aids, equipment lists, patient records, and facilitate dialogue between the two teams efficiently. Drs. Pises and Lyda did an outstanding job screening potential patients for surgery.

Additionally, the hospital facility in Siem Reap, while basic, was adequately equipped to support this mission. Available for use were an echo machine, anesthesia equipment, ventilators (although at any given time, only a couple were functional), cardiopulmonary monitors, cautery machine and blood bank availability.

The Mission Team

The energetic and enthusiastic team of 11 included pediatric cardiologist Paul Grossfeld, MD (UCSD), cardiothoracic surgeon Jolene Kriett, MD (UCSD), cardiothoracic surgeon Michael Madani, MD (UCSD), anesthesiologist Mark Greenberg, MD (UCSD), anesthesiology resident Gloria Cheng, MD (UCSD), respiratory therapist Phillip Panzarella (UCSD), echo tech William Elias (UCSD), cardiac intensive care nurse Stephanie Moriarty (Rady Children's Hospital San Diego), OR nurses Lourdes Pugeda and Genaro Hidalgo (Rady Children's Hospital San Diego) and program coordinator/photographer Susan Grossfeld.

The Challenges

As with any medical mission to a third world country, the trip to Cambodia was not without its own challenges, both medically and logistically. Because the UCSD team was relying on a thorough and accurate diagnosis by a general pediatrician and radiologist, Paul and the echo tech arrived in Siem Reap three days ahead of the rest of the team, in order to assess patients and determine which would be suitable for undergoing surgical ligation.

Of 17 patients evaluated, 15 were deemed amenable for surgical ligation. Most of these patients were severely malnourished and had congestive heart failure.

Faced with a minimally equipped OR, the surgeons were not afforded the luxury of a bypass machine, should complications arise. Coupled with the surgical findings of very difficult "fat and



www.careers.ualberta.ca

Section Head, Cardiac Catheterization in the Division of Pediatric Cardiology

The Department of Pediatrics at the University of Alberta invites applications for the position of Section Head: Cardiac Catheterization in the Division of Pediatric Cardiology. The Pediatric Cardiology program is a major cardiac surgical centre in Western Canada and a member of the Western Canadian Children's Heart Network. The successful candidate would be appointed to a contingent faculty position, with a primary appointment with the appropriate department/faculty of their discipline.

The successful incumbent will head the Cardiac Catheterization/interventional program at the University of Alberta, and promote the development of an integrated catheterization laboratory program within the Western Canadian Children's Heart Network. Exemplary clinical skills are required with a focus on leadership ability, particularly in a multi-centre model. The program supports the training of general pediatric cardiology residents and looks forward to the further development of a training program in Cardiac Catheterization. Demonstrated ability in the teaching of general cardiology fellows is important. A significant research record and demonstrated leadership in research is anticipated. An awareness of quality improvement methodology is an asset.

The candidate must be clinically qualified, and MD eligible for licensure in the Province of Alberta. The candidate must also have excellent interpersonal skills and have the ability to adapt to changing circumstances. Demonstrated cultural competence is essential.

Salary and Rank will be commensurate with qualifications and experience. Interested candidates should submit curriculum vitae and the names and contact information of three references by April 15, 2007 to:

Attn: Dr. John Dyck
Department of Pediatrics
Division of Cardiology
4C2 WMC
University of Alberta Hospital
8440 – 112 Street
Edmonton, AB, Canada T6G 2J3

Applicants are thanked in advance for their interest; however only those candidates selected for an interview will be contacted.

All qualified candidates are encouraged to apply, however, Canadians and permanent residents will be given priority. If suitable Canadian citizens and permanent residents cannot be found, other individuals will be considered. The University of Alberta hires on the basis of merit. We are committed to the principle of equity in employment. We welcome diversity and encourage applications from all qualified women and men, including persons with disabilities, members of visible minorities, and Aboriginal persons.



Figure 8. Dr. Michael Madani and Dr. Jolene Kriett say goodbye to their patients.

short" PDA's, the cardiothoracic surgeons were challenged on every case. In addition, most of the medications had

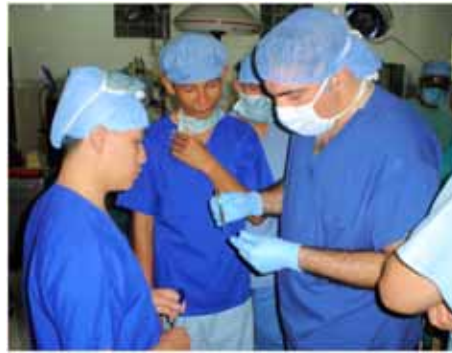

Figure 9. Dr. Michael Madani demonstrates suture technique to AHC's surgeons, Dr. Sar Vuthy and OR manager, Chhoy Chan.

to be transported by the respective team members in their checked baggage.

Happy Ending

The 15 surgeries were performed over three and a half days. All patients did exceptionally well. There were a few minor complications: One patient with a history of probable TB pneumonia had significant post-operative bleeding. He was explored with subsequent resolution. Another patient developed a pneumothorax post-operatively. The patient improved after placement of a chest tube. All 15 patients were able to be discharged home within a few days after surgery, prior to the departure of the American team.

Teaching: Fulfilling the mission

In addition to performing the surgical liga-



Arkansas Children's Hospital, Little Rock, AR Clinical Fellowship – Pediatric Cardiac Intensive Care



The Divisions of Pediatric Cardiology and Pediatric Critical Care Medicine at the University of Arkansas for Medical Sciences College of Medicine solicit applications for a clinical fellowship in Pediatric Cardiac Intensive Care for the academic year 2006-2007 and 2007-08.

This training is available for a period of 6-12 months to individuals who are BC/BE in either Pediatric Cardiology or Pediatric Critical Care Medicine. All clinical activities will take place at the Arkansas Children's Hospital Heart Center. Care is provided in a 15 - Pediatric Cardiac Intensive Care Unit 24/7 by a dedicated and highly specialized team of intensivists, cardiologists, cardiac surgeons, cardiac anesthesiologists, advanced nurse practitioners, nurses and allied health professionals. The Cardiac Intensive Care Unit admits approximately 600 patients per year. The pediatric and congenital cardiovascular surgery team led by Dr Robert DB Jaquiss performs approximately 550 congenital heart surgeries yearly with approximately one half being cardiopulmonary bypass cases. The program has a very strong neonatal cardiac surgery, heart transplant, ventricular assist device and mechanical support focus. Arkansas Children's Hospital maintains a very busy ECMO program, with one of the Nation's only mobile ECMO programs, and provides formal training in ECMO support of cardiac patients. The fellows will also have the opportunity of working closely with dedicated pediatric cardiac anesthesiologists during their training. The hospital also houses the Donald W. Reynolds Pediatric Intensive Care Unit, a state-of-the-art 26-bed facility which receives approximately 1100 admissions annually, where the fellow will receive training in lung-protective ventilator strategies and support of multi-organ dysfunction.

The program presents a very conducive environment for clinical training in various aspects of care of critically ill children with congenital heart disease. In general, this position will entail approximately 85% clinical time and 15% time for clinical research. There are numerous research opportunities and the fellow is encouraged to carry out meaningful clinical research during the course of the fellowship. The clinical training and responsibilities will be tailored for the individual candidate, depending on prior fellowship experience (i.e. Critical Care or Cardiology) and personal interests.

Clinical fellows will be appointed to the Department of Pediatrics, UAMS at the Instructor level in a non-tenure track position with faculty benefits including health and liability insurance. Applicants accepted for this clinical fellowship will be required to obtain an Arkansas medical license prior to starting training. The University of Arkansas Medical Sciences is an Equal Opportunity Employer. Little Rock, the capital of Arkansas is a warm and friendly cosmopolitan community with affordable housing, is well connected to other parts of the country and offers an abundance of recreational activities.

Interested individuals please contact:

Parthak Prodhon, MD
Pediatric Critical Care and Cardiology
University of Arkansas for Medical Sciences
800 Marshall Street Slot 512-3
Little Rock, AR 72202-3591
Tel: 501-364-1479; Fax: 501-364-3667
ProdhonParthak@uams.edu

tions, the American team devoted significant time to teaching, both didactic and “hands on.” Dr. Grossfeld gave a lecture to the pediatric residents on interpretation of the pediatric EKG, Dr. Mark Greenberg lectured on ventilator management to the hospital staff, Mrs. Stephanie Moriarty lectured on post-operative nursing care issues. In addition, Drs. Jolene Kriett and Michael Madani spent hours demonstrating their surgical technique to the AHC general surgeons. By the end of the week, AHC surgeons were assisting Drs. Kriett and Madani during the cases. Dr. Greenberg shared his knowledge on state-of-the-art anesthesia approaches with the AHC anesthesiologists.

In line with the vision of Salah Hassanein, future missions are currently being planned, with the aim of creating a self-sufficient cardiac surgical program at AHC within the next five years: a lofty but noble goal! Based on their experience, after witnessing the resolve of this Cambodian medical community, the American team has no doubts that this goal can be achieved.

~CCT~

Corresponding Author

Paul D. Grossfeld, MD
 Assistant Adjunct Professor,
 Division of Pediatric Cardiology
 Department of Pediatrics
 University of California
 San Diego School of Medicine
 3020 Children’s Way, MC 5004
 San Diego, CA 92123 USA

Telephone: 858-966-5855
 Telefax: 858-571-7903

pgrossfeld@ucsd.edu

Susan T. Grossfeld, BS
 University of California, San Diego

Pediatric Cardiology

We are looking for a non-invasive Pediatric Cardiologist for the Orlando Florida area. Established in 1994, we serve the Central Florida area with outpatient clinics, inpatient consults, fetal echo’s and cardiac catheterizations.

Competitive salary and benefits, including paid health, disability, malpractice insurance and CME allowances.

Come enjoy Florida with its beautiful beaches, lakes, great outdoor activities, and many cultural and sporting events. The Orlando area boasts ‘A’ schools and a prominent local University.

For a glimpse into our practice visit our website at:
www.carson-appleton.com

Please contact: Thomas Carson, M.D. for more details on this great opportunity via email at:
reddivet@aol.com or our office at 407-902-2866.

Submit your CV via fax to 407-902-2585.



© 2006 by Congenital Cardiology Today
 (ISSN 1554-7787-print; ISSN 1554-0499-online)
 Published monthly. All rights reserved

Publishing Management

Tony Carlson, Founder & Editor
TCarlsonmd@gmail.com
 Richard Koulbanis, Publisher & Editor-in-Chief
RichardK@CCT.bz
 John W. Moore, MD, MPH, Medical Editor/
 Editorial Board
JMoore@CHSD.org
 Jeffrey Green, Contributing Editor

Editorial Board

Teiji Akagi, MD
 Zohair Al Halees, MD
 Mazeni Alwi, MD
 Felix Berger, MD
 Fadi Bitar, MD
 Jacek Bialkowski, MD
 Phillip Bonhoeffer, MD
 Anthony C. Chang, MD, MBA
 John P. Cheatham, MD
 Bharat Dalvi, MD, MBBS, DM
 Horacio Faella, MD
 Yun-Ching Fu, MD
 Felipe Heusser, MD
 Ziyad M. Hijazi, MD, MPH
 Ralf Holzer, MD
 Marshall Jacobs, MD
 R. Krishna Kumar, MD, DM, MBBS
 Gerald Ross Marx, MD
 Tarek S. Momenah, MBBS, DCH
 Toshio Nakanishi, MD, PhD
 Carlos A. C. Pedra, MD
 Daniel Penny, MD
 James C. Perry, MD
 Shakeel A. Qureshi, MD
 Andrew Redington, MD
 Carlos E. Ruiz, MD, PhD
 Girish S. Shirali, MD
 Horst Sievert, MD
 Hideshi Tomita, MD
 Gil Wernovsky, MD
 Zhuoming Xu, MD, PhD
 William C. L. Yip, MD
 Carlos Zabal, MD

To Contact an Editorial Board Member

Email to: BOARD@CCT.bz. Place the Board Member’s name in the Subject line.

FREE Subscription

Congenital Cardiology Today is available free to qualified professionals worldwide in pediatric and congenital cardiology. International editions available in electronic PDF file only; North American edition available in print. Send an email to Subs@CCT.bz. Be sure to include your name, title, organization, address, phone, fax and email.

Contacts and Other Information

For detailed information on author submission, sponsorships, editorial, production and sales contact, current and back issues, see website:
www.CongenitalCardiologyToday.com



11th Vail Symposium on Pediatric Cardiac Diseases

Hosted by The Children’s Hospital—Denver

Vail Cascade Resort, Vail, Colorado

March 4-7, 2007

Contact: Dixon.Jeannie@tchden.org or Manzanares.Heidi@tchden.org

MEDICAL NEWS, NEW PRODUCTS AND INFORMATION

Genetic Clues to Cardiomyopathy's Origins Revealed in Mice

A genetic discovery sheds new light on the cause of cardiomyopathy and sudden death in young adults, which originates in the previously overlooked right ventricle of the heart, said a researcher at Baylor College of Medicine (BCM) and Texas Children's Hospital (TCH) in Houston.

In a report that appeared online in the *Journal Circulation Research*, Dr. Jeffrey Towbin, professor of pediatrics at BCM and chief of pediatric cardiology at TCH, reported that a study in mice identifies conclusively for the first time genetic origins of cardiomyopathy, one of the leading causes of sudden cardiac death in young adults.

"We are getting to the underlying cause of this disease," said Towbin, principal investigator of the study. "For the first time, we have taken a human disease gene and put it into an animal model so that we can study its mechanisms in greater detail."

Arrhythmogenic Right Ventricular Cardiomyopathy (ARVC) is a rare, progressive condition that causes diseased heart muscle and impairs cardiac function. In many cases, ARVC leads to fatigue, irregular heartbeat (arrhythmia), and, potentially, heart failure and sudden cardiac death.

In a previous study, Towbin and colleagues first identified mutations in the desmoplakin gene, which encodes a protein in the connecting junction between heart cells. In this study, funded by the National Institutes of Health and the National Heart, Lung, and Blood Institute, the authors implanted a mutant human desmoplakin gene into mice, which re-

sulted in the mice's cardiac integrity being compromised, leading to dilation of the right ventricle, buildup of scar and fatty tissue, and arrhythmia.

Towbin calls ARVC "underrecognized" in the United States primarily because of its relative newness and difficulty evaluating the right ventricle technically, which can lead to misdiagnosis and improper treatment. Statistics of its prevalence in the United States have yet to be determined, but in Italy the disease is known to be the leading cause of sudden cardiac death in otherwise healthy young adults.

"ARVC is underrecognized here in the United States because of the novelty of the disorder and the lack of advances in technology that assess the right ventricle," said Towbin. "But I predict that in the next several years this will be shown to be a key player in sudden cardiac death."

The new findings will help pediatric and adult cardiology experts better understand the root cause of ARVC and advance the care of patients with this specific abnormality, Towbin said.

"We now have the genetic ability - that is, making a diagnosis off of a blood test of the gene - to evaluate these patients from the perspective of the disease's origin," said Towbin. "Hopefully we will be able to engineer new targeted therapies on the basis of these findings."

Towbin's coauthors include first author Dr. Zhao Yang, of BCM, as well as contributors from Johns Hopkins University, University of Arizona, Harvard Medical School, and the University of Padua in Italy.

For more information: www.bcm.edu/news

Pediatric Rapid Response Team at Yale Reduces Cardiorespiratory Arrests

Yale School of Medicine's Department of Pediatrics and the Pediatric Intensive Care Unit at Yale-New Haven Hospital have been recognized by the Institute for Healthcare Improvement for implementing a rapid response team that aims to reduce the numbers of cardiorespiratory arrests in pediatric patients.

Cardiorespiratory arrests, in which respiration and circulation stops, is usually associated with adults, but also affects about seven percent of pediatric patients. Rapid response teams made up of ICU nurses and physicians can immediately evaluate any child upon request by any staff member. These teams help identify earlier signs that a child may be in trouble. The Rapid Response Team at Yale-New Haven Hospital was created in 2004.

"We are one of the first pediatric hospitals in the country to have instituted this system, which is a key component of The Institute of Healthcare Improvement's 100,000 lives campaign," said Associate Professor of Pediatrics and Chief of Critical Care Medicine Clifford Bogue, MD. "This has resulted in a remarkable 50 percent decrease in cardiorespiratory arrests outside of the pediatric intensive care unit."

Yale-New Haven Hospital has also been named a Mentor Hospital by the National Association of Children's Hospitals and Related Institutions. As a result, faculty members in pediatrics will serve as a resource for training in this area to other children's hospitals around the country.

For more information: www.yale.edu/opa



Barth Syndrome
Foundation

The Barth Syndrome Foundation

P.O. Box 974, Perry, FL 32348

Tel: 850.223.1128

info@barthsyndrome.org

www.barthsyndrome.org

Symptoms: Cardiomyopathy, Neutropenia, Muscle Weakness, Exercise Intolerance, Growth Retardation