CONGENITAL CARDIOLOGY TODAY
Timely News & Information for Congenital/Structural Cardiologists & Cardiothoracic Surgeons Worldwide
International Edition
Vol. 19 - Issue 10
October 2021

Table of Contents

Use of AliveCor Kardia Mobile Device in the Detection of Supraventricular Tachycardia in a Pediatric Population

Aniqa Shahrier MD; Gretchen Hackett, DO, MS; Jill Cowen, MSPAS, PA-C; Thomas Chin, MD; Jason R. Imundo, MD, FHRS

We present a case of a 15-year-old female with supraventricular tachycardia (SVT) detected by AliveCor's Kardia Mobile device, who subsequently underwent successful catheter ablation. The patient initially presented to care under Pediatric Cardiology at age 13 due to palpitations which had been occurring for the previous two years. Her initial electrocardiogram demonstrated a normal sinus rhythm and an RSR pattern in lead V1 without evidence of ventricular pre-excitation. Baseline echocardiogram demonstrated a structurally normal heart with good function. She subsequently underwent a Holter study which demonstrated periods of sinus arrhythmia, a single premature ventricular complex, and single atrial premature complexes without any documented tachy-dysrhythmias. She was followed for over two years during which two additional echocardiograms, an exercise stress test, a thirty-day cardiac event monitor, and three additional ECGs were performed, all of which were non-revealing. The patient continued to experience palpitations lasting from minutes to hours with heart rates into the 200's, as noted by family throughout this period. With suspicion that these episodes represented SVT, it was suggested that the family utilize AliveCor's Kardia Mobile device. With the use of the device, the patient was able to capture and record an episode of SVT lasting 20 minutes with a heart rate of 230-250 bpm. A low-dose beta-blocker was initially trialed and not tolerated due to hypotension; an ablation was subsequently scheduled. In the interval leading to the ablation, the patient was able to capture multiple episodes of SVT utilizing the Kardia Mobile device **(Figure 1).** The Kardia Mobile device was able to document retrograde P waves during SVT that correlated to the patient's left lateral concealed accessory pathway found to be responsible for her reentry SVT on the electrophysiology study.

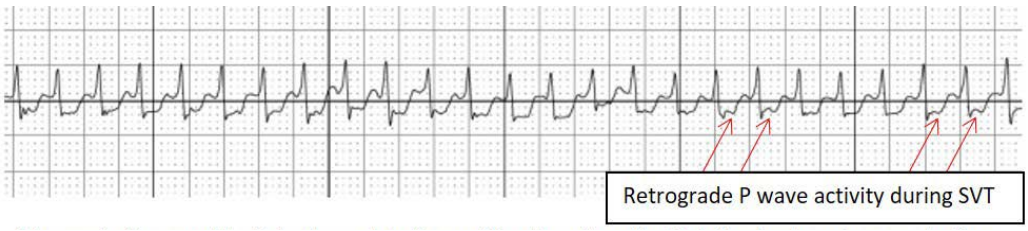

FIGURE 1 *Transmitted rhythm strip from AliveCor Kardia Mobile device demonstrating SVT at a rate of approximately 250 bpm.*

The electrophysiology study showed the earliest retrograde atrial activation during ventricular pacing at the CS distal electrode and easily inducible orthodromic reciprocating tachycardia with atrial and ventricular pacing maneuvers utilizing a left anterior lateral concealed accessory pathway at a tachycardia cycle length of 260msec (**Figure 2**). Radiofrequency current was delivered at the earliest activation site at the left anterior lateral mitral valve surface with immediate loss of accessory pathway conduction (**Figure 3**). Retrograde accessory pathway block was confirmed with intravenous adenosine greater than one hour post ablation with no inducible SVT at baseline or on Isuprel post ablation.

OCTOBER 2021

International Edition Vol. 19 - Issue 10

TABLE OF CONTENTS

CONGENITAL CARDIOLOGY TODAY

Publish

- Written by doctors and their team
- Case studies, articles, research findings
- Submit on your schedule
- Print and electronic
- Published within 3 months of submission
- No fees

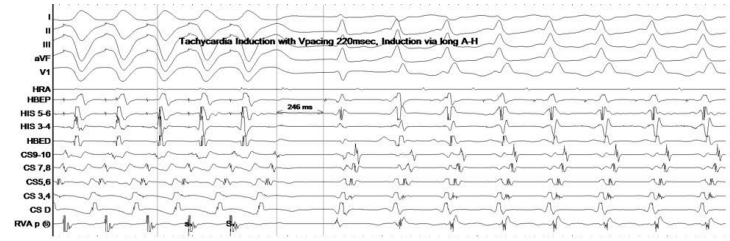

FIGURE 2 *Intracardiac tracing demonstrating a left anterior lateral concealed accessory pathway.*

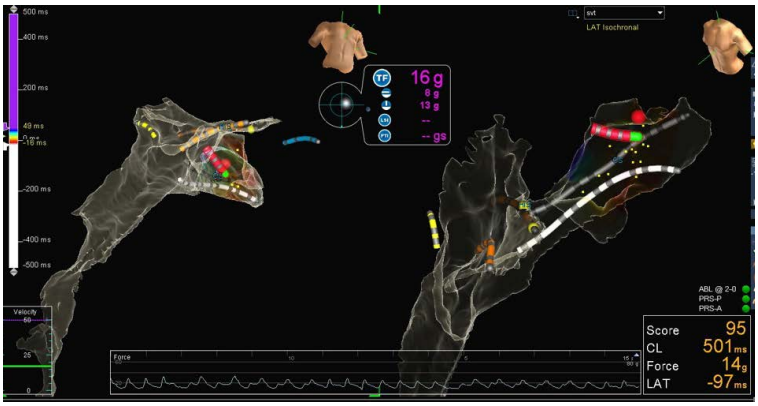

FIGURE 3 *EnSite 3D mapping system demonstrating the anatomical location and ablation site of the left anterior lateral concealed accessory pathway (red dot).*

Our case demonstrates a publicly sold, affordable home monitoring device marketed for detecting arrhythmias in adults successfully detecting an accessory pathway mediated reentry SVT in a pediatric patient which ultimately led to a successful catheter ablation. Although our subject had been symptomatic for a period of years, we were unable to successfully capture her arrhythmia utilizing standard practice measures. In the last several years, many companies have developed technology which can capture a rhythm strip remotely and transmit it via a device such as a smartphone. Development of this technology has brought about many questions regarding how we can move forward in utilizing and incorporating this technology into care of patients.[1]

AliveCor (San Francisco, CA) is one of these companies and is the developer of the Kardia Mobile ECG device which our patient used. This device transmits a single-lead rhythm strip which is comparable to Lead 1 on a standard 12-lead ECG with the use of a smartphone. At this time, AliveCor has marketed this device as being capable of detecting atrial fibrillation, bradycardia, tachycardia, and normal sinus rhythm. It does have FDA approval for use in adults with atrial fibrillation.[2] This product can be purchased directly by the consumer.

Many research studies have been published evaluating the use of the Kardia Mobile device in the detection of atrial fibrillation in an adult population. The study by Zaprutko et al demonstrated a sensitivity, specificity, and negative predictive value of 100% for the Kardia app detecting atrial fibrillation in a population aged ≥ 65 years without prior atrial fibrillation.[3] Multiple studies have evaluated similar data assessing the use of the Kardia Mobile device as a screening tool for atrial fibrillation in adults.[4,5] Other studies have evaluated the reliability between the Kardia Mobile device readings with a standard ECG with promising results.[6] A large-scale study out of the Netherlands by Selder et al evaluated ambulatory monitoring utilizing the Kardia Mobile device to assess 5,982 readings from 233 patients with a mean age of 58 years.[7] The results demonstrated that the device was successful in identifying atrial fibrillation. It was noted however, that other types of arrhythmias, specifically regular small complex tachycardias, would get flagged into the possible atrial fibrillation, unclassified, or unreadable results as provided by the Kardia Mobile device algorithm. With review by an experienced cardiologist however, these arrhythmias were correctly interpreted. A study focusing specifically on the pediatric population and use of the Kardia Mobile device by Gropler et al compared standard 12-lead ECG with the Kardia Mobile device recordings in 30 pediatric patients and found there to be accuracy between the two in terms of intervals.[2]

Overall, the use of the Kardia Mobile device is directed to an adult population and specifically to identify atrial fibrillation. At this time, the Kardia Mobile device does not have an algorithm built in to identify other arrhythmias, including SVT. However, some studies, in addition to our case, have shown that the tracings obtained from the Kardia Mobile device can be reviewed by a cardiologist to help identify and diagnose other types of arrhythmias. A study by Nguyen et al demonstrated successful capture of SVT episodes utilizing the Kardia Mobile device in pediatric patients with previously diagnosed SVT and also demonstrated excellent user satisfaction.[8] Our case emphasizes the benefit of this type of device in the pediatric population when the arrhythmias occur infrequently and may not be able to be captured on our standard monitors, which include 24/48 hour Holter studies and 30-day event/continuous telemetry monitors. This type of device may also be helpful in patients with skin sensitivity to lead adhesive. The quality of the tracing was similar to our standard monitors at heart rates of 250 bpm with retrograde P waves noted during our patient's episode of SVT.

Per Sacchetti et al, SVT is the most common dysrhythmia in children.[9] The incidence of SVT in the pediatric population was demonstrated to be 1.03 per 1000 patient years by Wu et al.[10] This study also demonstrated that almost 20% of patients with SVT had undergone an ablation, which is often curative. The incidence of SVT increases further to 7% in children with Congenital Heart Disease.[11] SVT most commonly occurs in two forms, atrioventricular reentrant tachycardia (AVRT) and atrioventricular nodal reentrant tachycardia (AVNRT), with the former being most common. Diagnosis and management of SVT is crucial as it can lead to rare, but serious consequences including syncope and heart failure. These risks are further increased in children with structural heart disease.

Arrhythmias in the pediatric population tend to be paroxysmal in nature and thus can be difficult to capture on standard 12-lead ECG, 24-hour Holter monitors, and event monitors. Our case demonstrated a period of years with symptoms and testing prior to the arrhythmia successfully being captured. As many patients with SVT experience distinct symptoms during events, the use of a long-term intermittent ambulatory monitoring device such as the Kardia Mobile device may prove to be beneficial, as in the case of our patient as it prompted an electrophysiology study and curative ablation. Our case raises the question as to whether the indications for use of these types of devices should be expanded to routinely include pediatric patients. More specifically, utilizing these devices in children with infrequent symptoms where other screening tools have failed may prove beneficial in capturing potential arrhythmia

RIGHT CHOICE.

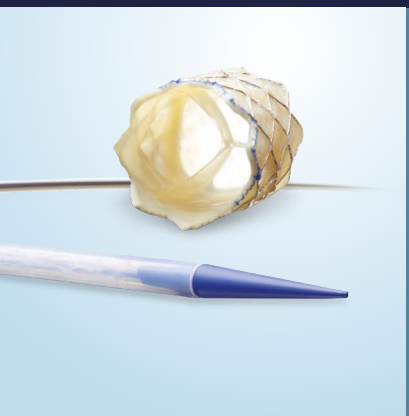

Melody™

Transcatheter Pulmonary Valve (TPV) System



Not intended to constitute medical advice or in any way replace the independent medical judgment of a trained and licensed physician with respect to any patient needs or circumstances. Melody TPV is not suitable for all patients and ease of use, outcomes, and performance may vary. See the Instructions for Use for indications, contraindications, precautions, warnings, and adverse events.

Restoring lives for

13

years and counting.

The only transcatheter pulmonary valve specifically designed for RVOT conduits and bioprosthetic valves. The longest studied transcatheter valve, with the largest body of clinical evidence at over 10 years.* More than 16,000 patients' lives have been changed over 13 years, and counting.

Melody TPV — The Right Choice for Your Patients

*Melody Transcatheter Pulmonary Valve Study: Post Approval Study of the Original IDE Cohort.

©2020 Medtronic. All rights reserved.
UC201809495b EN 11/2020

Medtronic
Further, Together

Important Labeling Information for the United States

Indications: The Melody TPV is indicated for use in the management of pediatric and adult patients who have a clinical indication for intervention on a dysfunctional right ventricular outflow tract (RVOT) conduit or surgical bioprosthetic pulmonary valve that has ≥ moderate regurgitation, and/or a mean RVOT gradient ≥ 35 mm Hg.

Contraindications: None known.

Warnings/Precautions/Side Effects

- **DO NOT implant in the aortic or mitral position. Pre-clinical bench testing of the Melody valve suggests that valve function and durability will be extremely limited when used in these locations.**
- DO NOT use if patient's anatomy precludes introduction of the valve, if the venous anatomy cannot accommodate a 22 Fr size introducer, or if there is significant obstruction of the central veins.
- DO NOT use if there are clinical or biological signs of infection including active endocarditis. Standard medical and surgical care should be strongly considered in these circumstances.
- Assessment of the coronary artery anatomy for the risk of coronary artery compression should be performed in all patients prior to deployment of the TPV.
- To minimize the risk of conduit rupture, do not use a balloon with a diameter greater than 110% of the nominal diameter (original implant size) of the conduit for pre-dilation of the intended site of deployment, or for deployment of the TPV.
- The potential for stent fracture should be considered in all patients who undergo TPV placement. Radiographic assessment of the stent with chest radiography or fluoroscopy should be included in the routine postoperative evaluation of patients who receive a TPV.
- If a stent fracture is detected, continued monitoring of the stent should be performed in conjunction with clinically appropriate hemodynamic assessment. In patients with stent fracture and significant associated RVOT obstruction or regurgitation, reintervention should be considered in accordance with usual clinical practice.

Potential procedural complications that may result from implantation of the Melody device include the following: rupture of the RVOT conduit, compression of a coronary artery, perforation of a major blood vessel, embolization or migration of the device, perforation of a heart chamber, arrhythmias, allergic reaction to contrast media, cerebrovascular events (TIA, CVA), infection/sepsis, fever, hematoma, radiation-induced erythema, blistering, or peeling of skin, pain, swelling, or bruising at the catheterization site. Potential device-related adverse events that may occur following device implantation include the following: stent fracture,* stent fracture resulting in recurrent obstruction, endocarditis, embolization or migration of the device, valvular dysfunction (stenosis or regurgitation), paravalvular leak, valvular thrombosis, pulmonary thromboembolism, hemolysis.

*The term "stent fracture" refers to the fracturing of the Melody TPV. However, in subjects with multiple stents in the RVOT it is difficult to definitively attribute stent fractures to the Melody frame versus another stent.

For additional information, please refer to the Instructions for Use provided with the product or available on http://manuals.medtronic.com.

CAUTION: Federal law (USA) restricts this device to sale by or on the order of a physician.

Important Labeling Information for Geographies Outside of the United States

Indications: The Melody™ TPV is indicated for use in patients with the following clinical conditions:

- Patients with regurgitant prosthetic right ventricular outflow tract (RVOT) conduits or bioprostheses with a clinical indication for invasive or surgical intervention, OR
- Patients with stenotic prosthetic RVOT conduits or bioprostheses where the risk of worsening regurgitation is a relative contraindication to balloon dilatation or stenting

Contraindications

- Venous anatomy unable to accommodate a 22 Fr size introducer sheath
- Implantation of the TPV in the left heart
- RVOT unfavorable for good stent anchorage
- Severe RVOT obstruction, which cannot be dilated by balloon
- Obstruction of the central veins
- Clinical or biological signs of infection
- Active endocarditis
- Known allergy to aspirin or heparin
- Pregnancy

Potential Complications/Adverse Events: Potential procedural complications that may result from implantation of the Melody device include the following: rupture of the RVOT conduit, compression of a coronary artery, perforation of a major blood vessel, embolization or migration of the device, perforation of a heart chamber, arrhythmias, allergic reaction to contrast media, cerebrovascular events (TIA, CVA), infection/sepsis, fever, hematoma, radiation-induced erythema, pain, swelling or bruising at the catheterization site. Potential device-related adverse events that may occur following device implantation include the following: stent fracture.* stent fracture resulting in recurrent obstruction, endocarditis, embolization or migration of the device, valvular dysfunction (stenosis or regurgitation), paravalvular leak, valvular thrombosis, pulmonary thromboembolism, hemolysis.

*The term "stent fracture" refers to the fracturing of the Melody TPV. However, in subjects with multiple stents in the RVOT it is difficult to definitively attribute stent fractures to the Melody frame versus another stent.

For additional information, please refer to the Instructions for Use provided with the product or available on http://manuals.medtronic.com.

The Melody Transcatheter Pulmonary Valve and Ensemble II Transcatheter Delivery System has received CE Mark approval and is available for distribution in Europe.

medtronic.com

710 Medtronic Parkway
Minneapolis, MN 55432-5604
USA
Tel: (763) 514-4000
Fax: (763) 514-4879
Toll-free: (800) 328-2518

LifeLine
CardioVascular Technical Support
Tel: (877) 526-7890
Fax: (651) 367-0918
rs.structuralheart@medtronic.com

©2020 Medtronic. All rights reserved. Medtronic, Medtronic logo, and Further, Together are trademarks of Medtronic. All other brands are trademarks of a Medtronic company.

UC201809495b EN 11/2020

Medtronic

episodes. Further studies should be performed to assess the use of the Kardia Moblie device in this regard to determine the usefulness of the device and number needed to treat. Given that this device carries minimal risk with use and has previously demonstrated excellent patient satisfaction scores, its use in a research setting could provide useful information. Overall, our case demonstrates a unique use of the AliveCor Kardia Mobile device in identifying previously undiagnosed SVT in a pediatric patient leading to successful ablation of AVRT utilizing a concealed accessory pathway.

References

1. Isakadze N, Martin SS. How useful is the smartwatch ECG? Trends in Cardiovascular Medicine 2019, https://doi.org/10.1016/j.tcm.2019.10.010.
2. Gropler MRF, Dalal AS, Van Hare GF, Silva JNA. Can smartphone wireless ECGs be used to accurately assess ECG intervals in pediatrics? A comparison of mobile health monitoring to standard 12-lead ECG. PLoS One 2018, https://doi.org/10.1371/journal.pone.0204403.
3. Zaprutko TZ, Zaprutko J, Baszko A, et al. Feasibility of atrial fibrillation screening with mobile health technologies at pharmacies. Journal of Cardiovascular Pharmacology and Therapeutics 2019, https://doi.org/10.1177/1074248419879089.
4. Cunha S, Antunes E, Antoniou S, et al. Raising awareness and early detection of atrial fibrillation, an experience resorting to mobile technology centred on informed individuals. Research in Social and Administrative Pharmacy 2019, https://doi.org/10.1016/j.sapharm.2019.08.036.
5. Godin R, Yeung C, Baranchuk A, Guerra P, Healey JS. Screening for atrial fibrillation using a mobile, single-lead electrocardiogram in Canadian primary care clinics. Canadian Journal of Cardiology 2019:35:840-845.
6. Koltowski L, Balsam P, Gllowczynska R, et al. Kardia Mobile applicability in clinical practice: A comparison of Kardia Mobile and standard 12-lead electrocardiogram records in 100 consecutive patients of a tertiary cardiovascular care center. Cardiology Journal 2019, https://doi.org/10.5603/CJ.a2019.0001.
7. Selder JL, Breukel L, Blok S, van Rossum AC, Tulevski II, Allaart CP. A mobile one-lead ECG device incorporated in a symptom-driven remote arrhythmia monitoring program. The first 5,892 Hartwacht ECGs. Netherlands Heart Journal 2019:27:38-45.
8. Nguyen HH, Van Hare GF, Rudokas M, Bowman T, Silva JNA. SPEAR Trial: Smartphone Pediatric ElectrocARdiogram Trial. PLoS One 2015, https://doi.org/10.1371/journal.pone.0136256.
9. Sacchetti A, Moyer V, Baricella R, Cameron J, Moakes ME. Primary cardiac arrhythmias in children. Pediatric Emergency Care 1999:15:95-98.
10. Wu MH, Chen HC, Kao FY, Huang SK. Postnatal cumulative incidence of supraventricular tachycardia in a general pediatric population: A national birth cohort database study. Heart Rhythm 2016:13: 2070-2075.
11. Tripathi A, Black GB, Park YM, Jerrell JM. Factors associated with the occurrence and treatment of supraventricular tachycardia in a pediatric congenital heart disease cohort. Pediatric Cardiology 2014:35:368-373.

ANIQA SHAHRIER, MD
Pediatric Cardiology Fellow
Penn State Health Children's Hospital
Hershey, PA, USA
aniqa.shahrier@gmail.com

GRETCHEN HACKETT, DO, MS
Pediatric Cardiology Fellow
Penn State Health Children's Hospital
Hershey, PA, USA

JILL COWEN, PA-C
Physician Assistant
Penn State Health Children's Hospital
Hershey, PA, USA

THOMAS CHIN, MD
Chief of Pediatric Cardiology
Penn State Health Children's Hospital
Hershey, PA, USA

JASON IMUNDO, MD, FHRS, CEPS-P
Associate Professor of Pediatrics
Penn State Health Children's Hospital
Hershey, PA, USA

Early Detection and Advocacy – A Survivor's Story

Natalie Poli, Ed.S

On January 6th, 2006 I was giving my oldest son (who was two and a half) a bath. I went into his room to get a pull-up off his bookshelf - something I had done literally hundreds of times before. This time was different - VERY different!

I remember watching my hand reach for a pull-up, but before I could do anything, I instead saw the entire stack of them fall to one side. It was actually ME falling to one side! I crawled into the hallway and shouted for my husband. He rushed in and I was barely able to say, "I think I'm having a stroke!" While this would be terrifying at any time, the fact that I was nine weeks postpartum was especially troubling; we had no idea what was happening. Was I tired? Was I having a reaction to the birth control I had just started? Or, was I truly having a stroke?

I didn't want my son to see me like this, so I told my husband to care for him; I'll be okay. After all, as the new mom I'M the caregiver, not someone to be fussed over. Luckily our newborn was still asleep in the car carrier since I had just driven us home about a half hour before this transient ischemic attack happened. My husband and I decided I should lay down while he cared for our two sons.

After a few moments, I realized this was not going to get better by itself; I was getting worse by the minute. Feeling like I was having an out-of-body experience, I watched myself reach for the phone and saw it fall to the floor. I reached for the doorknob without any ability to open it, then I fell down our stairs while trying to get my doctor's card out of my wallet - those were the days before smartphones. I had to get that card, and after great effort I finally succeeded. I made my way back upstairs, crawling up while dealing with sensations I had never felt before - and I remember thinking "ten minutes ago I was 100% fine!"

I called my physician's office. "XYZ Family Physicians answering service" I hear on the other end of the line. "I need the doctor on call paged" I responded - or at least I thought I responded, but of course no words were coming out of my mouth. Since the answering service didn't hear me, their response was a simple "Click." "Hello? Hello?" I thought I said, but again in reality I wasn't saying a word. I was so confused that for several minutes I didn't even think to simply dial 911.

I then called my in-laws at the time. They answer, I tell them it's me, but since I wasn't actually talking, after a while they hung up as well. Again, in my mind I was trying to speak to someone - anyone! - communicating I needed help, but no response. What was happening?? Finally, I dialed 911. "911 dispatch." Oh thank goodness I thought (but wasn't able to say). "I need an ambulance," "Hello? Are you there?" was the response, then click. My husband was in the other room with my son, my infant sleeping, and I'm not getting any help. Minutes later our doorbell rings. It's a police officer and he is responding to my 911 call. He sits me down on my stairway and asks me a few questions. I answered him, I knew in my mind I was answering, but again the words weren't coming. He then proceeded to hand me a pen and paper and asked me to write down what I was trying to say. I picked up the pen and immediately saw it fall to the ground. He replied over his radio, "I have a 29-year-old stroke victim, nine weeks postpartum, send the medics now."

"What?" I thought. "Can anyone understand me?" No, none of them. My husband, the officer, the paramedics, my neighbor who came to help care for my boys. None of them could understand me because I had lost all speech and all feeling in the right side of my body. I was having a stroke--big time.

After eight long days in the hospital, countless tests and multiple physician consults, one simple test determined why I had the stroke. An echocardiogram revealed I had two holes in my heart and an atrial septum aneurysm. I had lived 29 years and had no idea I had Congenital Heart Disease and was born with a heart defect. I had done everything right for so long, but in reality, I was lucky the outcome was not worse. I had been active as a dancer for over 20 years of my life, ate well, always went to my annual doctors' visits, and gave birth to two of my three boys by that time. How had no one previously found these holes in my heart? When I was a member of the University of Iowa Dance Team, I remember crying through the three miles we had to run as part of our circuit training program. There was also a time when I was a cheerleader for the Chicago Bulls when I came off the court gasping for air and used my friend's asthma inhaler. It was so bad. The doctor said I did not have asthma and so I kept on with my life.

After many doctor consultations and considering the possibility of becoming part of a research trial, I was blessed to find a wonderful staff of doctors and nurses led by Dr. Zyiad Hijazi who cared for me. I was a recipient of two Amplatzer devices because at the time I was not a candidate for the PFO devices due to FDA regulations and criteria.

I came out of my stroke with no residual damage and no brain damage. The physicians called me a mystery because they could not find any evidence of a blood clot in my brain, but they knew exactly what happened. A blood clot traveled from my heart to my brain and lodged in the area of my brain that controls speech, language and feeling in the right side of my body. Postpartum women have a higher blood volume due to pregnancy; that was a factor in the amount of blood that was moving through my heart, which already had incorrect channels of movement due to the holes.

If I had known I had two PFO's and an atrial septal defect in my heart since infancy, by one simple echocardiogram, I would not have experienced a stroke. Now, as a Public Education Professional and Senior Patient Advisor to the PICS Society, I am able to educate people about stroke, advocate for patients to have early detection resources to ensure that CHD is caught early on because not everyone is as lucky as I was. An echocardiogram in infancy is a simple test that can save and improve the lives of so many. That is what I am advocating for in addition to early detection, encouraging patients and families to come together with one voice, and advocating for the right procedure for each individual patient's needs. Having the right procedure available without any non-medical barriers is essential and key to our success.

I am now 44, have three boys, and live a normal, healthy life. This year celebrates 15 years of being a stroke survivor and heart device recipient. You can watch me share more about my platform and mission **Stroke of Insight** at my website www.NataliePoli.com and at this year's Mrs. Illinois

International 2022 pageant where I will put my advocacy into action to help bring CHD center stage.

NATALIE POLI, Ed.S
PICS Society Senior Patient Advocate
Public Education Professional
Successfully treated interventionally for CHD, 2006
Mrs. Illinois International 2021 1st Runner Up
Former Captain of the NBA Chicago Bulls Dance Team

Hospital Directory 2021-2022
Now Available

- Current updated listings
- Hospitals that Offer Open Heart Surgery for Children in North America
- Contact information at each hospital for Chief of Pediatric Cardiology & Fellowship Director
- Lists each hospital's Pediatric Cardiologists & Cardiothoracic Surgeons
- Distributed to Division Chiefs by mail
- Electronic version available on CCT's website: www.congenitalcardiologytoday.com

PICS Society
Pediatric and Congenital Interventional Cardiovascular Society
3D IMAGING I3

SAVE THE DATE
Symposium 2022

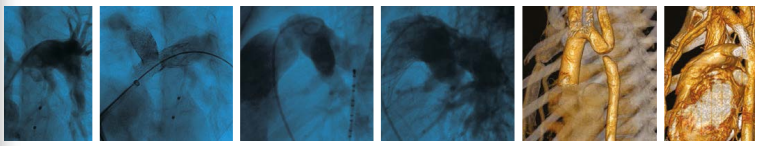

Focusing on the latest interventional catheter strategies for congenital and structural heart disease in children and adults.

www.picsymposium.com
www.CHDinterventions.org

Interventional Systems
B|BRAUN
SHARING EXPERTISE

INCREASE YOUR REACH

with the sizing balloon catheter trusted for over a decade.

What Clinicians Like:

- Comprehensive size offering with diameters ranging from 20mm – 40mm
- Four radiopaque marker bands to enable accurate defect sizing
- Low profile design for ease of deliverability and compatibility with D'VILL™ Introducer (65cm)
- Braided inner lumen for optimal pushability, trackability and kink-resistance

ESTABLISHED. PROVEN. EFFECTIVE.

PTS-X™

Sizing Balloon Catheter

Distributed by:
B. Braun Interventional Systems Inc. | Part of the B. Braun Group of Companies
Bethlehem, PA | USA | 877-836-2228 | www.bisusa.org

Refer to the Instructions for Use for complete indications, relevant warnings, precautions, complications, and contraindications.
PTS-X and D'VILL are trademarks of NuMED, Inc. **Rx only** CV-9137 2/21 ©2021 B. Braun Interventional Systems Inc.

UCI Health and CHOC Open One of the First Fetal Care Centers in Southern California

The Fetal Care Center of Southern California offers fetal diagnosis, education and support to expectant families whose babies have significant birth defects, as well as treatment of both the mother and newborn in a single location

A partnership between UCI Health and CHOC, the Fetal Care Center of Southern California has begun seeing its first patients; expectant parents experiencing the unexpected news of a high-risk pregnancy with a baby facing complex medical conditions. This unique collaboration, filling an unmet need in the region, brings together world-class experts in both Maternal-Fetal Medicine and Pediatrics, so both parents and baby are cared for in one patient-centered location.

"The Fetal Care Center of Southern California is a one-stop care center for pregnant parents whose babies have serious birth defects that will need treatment after delivery – or in some cases even before delivery," said Dr. Peter Yu, a CHOC General Surgeon and Co-Medical Director of the Fetal Care Center. "Expectant parents can put all their burdens, anxiety and concerns on us. We can take care of almost any issue a baby may be facing – and we'll be with each family every step of the way."

Complex fetal anomalies affect 1 to 3% of pregnancies with a number of these babies requiring neonatal intensive care and surgery immediately following birth. Located on CHOC's campus in Orange, Calif., the Fetal Care Center ensures families have access to this critically important care in a single location. Expectant parents can be seen by a full complement of maternal-fetal medicine and pediatric specialties in one day and in one center.

"When there is a special delivery expected with complicated fetal disease or a birth defect, the maternal-fetal medicine specialist works in concert with pediatric specialists to manage in-utero complications and delivery issues, as well as plan lifelong care for the baby," said Dr. Jennifer Jolley, OB/GYN and maternal-fetal medicine specialist with UCI Health. "Now, we can streamline that care through this unique collaboration between UCI Health and CHOC."

In addition to certain fetal interventions like amniocentesis, tube/shunt placement, transfusions and more, the multi-disciplinary, comprehensive Fetal Care Center will offer:

- Consultation
- Fetal diagnostics: ultrafast fetal MRI and board-certified pediatric radiologists; fetal echocardiograms performed by board-certified pediatric cardiologists; fetal genetic testing; and fetal ultrasound
- Treatment planning
- After-birth care
- A full complement of specialties:
  - Cardiology
  - Genetics
  - Maternal-fetal medicine
  - Neonatology
  - Neurology
  - Neurosurgery
  - Otolaryngology
  - Orthopaedic surgery
  - Pediatric general and thoracic surgery
  - Plastic surgery
  - Urology

"The Fetal Care Center of Southern California aims to provide families with every resource necessary – excellent diagnostics, comprehensive counseling, and neonatal and surgical planning, with an emphasis on multi-



disciplinary care coordination to meet the needs of the entire family," said Dr. Nita Doshi, a CHOC cardiologist. "An expectant family can now be seen by all needed specialists in one day in one location."

The Fetal Care Center team is with parents and baby at every step to bring peace of mind: confirming or further defining the baby's diagnosis; counseling parents on what to expect; providing prenatal interventions mom and baby may need; delivering the baby safely; and providing the medical treatment baby will receive afterward.

"The role of the Neonatology Division in the Fetal Care Center is to provide support for the families and the babies from the diagnosis all the way through to their perinatal care and care in the Neonatal Intensive Care Unit," said Dr. Kushal Bhakta, a neonatologist and medical director of CHOC's Small Baby Unit. "We deeply understand that this is likely the most stressful time of a parent's life, and we're here to help them navigate that."

A nurse coordinator serves as a concierge for the expectant parent, offering a single point of contact to answer questions and coordinate across specialties, from diagnosis to delivery.

"We understand that a new parent who is experiencing complications doesn't want to wait to see their provider – she wants to know right away what is happening with her baby," said Amy Cuevas MSN, RN-CCTM, manager of the Fetal Care Center. "Once we get a referral, we see the patient in our calming environment within seven days. Following an echocardiogram or ultrasound, they'll meet with their nurse coordinator for education about the baby's diagnosis and they'll leave here knowing that there is a plan of care in place."

The 2,200-square-foot Fetal Care Center features a spacious lobby, two echocardiogram rooms, one ultrasound room, two patient consultation rooms and a physician reading room, all set against soothing, spa-like aesthetics including warm wooden accents and sophisticated, vibrant artwork.

The total cost to build the Fetal Care Center, as well as CHOC's adjacent outpatient heart center, was $5.25 million, made possible through generous community support, in particular leadership donors the Glass Slipper Guild and Kathryn Hennigan.

UF Health Shands Children's Hospital

Doug Bennett

The University of Florida Health Shands Children's Hospital is the No. 1 children's hospital in Florida and stands among the nation's elite pediatric hospitals in eight medical specialties including a first-ever Top 10 ranking in cardiology and a historically high ranking for pulmonology, according to the 2021-22 Best Children's Hospital Rankings just released by U.S. News & World Report.

Every ranked medical specialty program improved its standing from last year and the eight ranked programs are the most for UF Health since 2016. The No. 7 ranking for pediatric cardiology punctuates 11 years among the nation's top programs, including six consecutive years in the Top 25.

Seven other specialties made significant gains in the rankings, including: pulmonology (No. 21), diabetes and endocrinology (No. 12), neurology and neurosurgery (No. 45), cancer (No. 45), urology (No. 46), neonatology (No. 47) and nephrology (No. 48). Overall, UF Health Shands Children's Hospital is ranked No. 5 among pediatric hospitals in the nine-state southeast region.

"These are exceptional achievements across a wide range of pediatric medical specialties. The rankings validate the skilled, attentive care that our physicians, nurses and staff members provide every day and night. Parents trust us to provide the very best care for their children and it is especially gratifying to deliver on that promise in so many specialties," said David R. Nelson, MD, Senior Vice President for health affairs at UF and president of UF Health.

The pediatric cardiology and heart surgery program is the highest-rated in Florida for the sixth consecutive year. Pulmonology and endocrinology are now in their fourth year as the state's top programs.

"It is an incredible accomplishment to move up the rankings in so many specialties, especially during an uncertain and turbulent pandemic year. This recognition reflects our deep, ongoing devotion to patient care, research and medical education," said Desmond A. Schatz, MD, the hospital's Physician-in-Chief and Interim Chair of the UF College of Medicine's Department of Pediatrics.

Schatz said he is particularly proud of the resilience and focus shown by pediatric faculty members and hospital staff. In the past year, those efforts included securing a $1 million grant to expand telemedicine services and medical monitoring equipment among underserved and vulnerable populations. Research funding has grown during the past year and UF continues to be a national leader in areas that include pediatric heart care and diabetes research and treatment, Schatz said. Two women faculty members are beginning a prestigious, nationally selective executive leadership program while others have emerged as expert voices on pandemic issues related to children, he noted.

"In every facet that can be measured there is a profound commitment to improving the lives of children. When parents bring their children to be seen by our physicians and providers, they can be assured they're in the right place for state-of-the-art care," he said.

Mark S. Bleiweis, MD, Director of the UF Health Congenital Heart Center, credits the cardiology and heart surgery ranking to several factors. One of those is achieving high-quality patient outcomes while also taking on highly complex cases and a large volume of procedures. Teamwork is another factor.

"This is a recognition of the extreme dedication, hard work and creativity among many people. They are all dedicated to the same vision of providing the highest levels of innovation and patient care," he said.

In addition to patient outcomes and volumes, Bleiweis said he is proud of efforts to develop advanced therapies for heart failure patients and research that has focused on single ventricle defects.

Sreekala Prabhakaran, MD, Interim Chief of the Pediatric Pulmonary Division, said the department's historically high ranking is a result of a long-standing commitment to patient care through multidisciplinary programs for neuromuscular diseases and severe asthma. Several subspecialties, including the severe asthma program, neuromuscular disease and cystic fibrosis programs use a family centered, culturally appropriate approach to develop individualized treatment plans for children. A medical-legal team, which helps to address barriers to care, is also embedded in the severe asthma program. This is the fourth consecutive year pulmonology is ranked among the nation's top 30 programs.

"Staying among the nation's very best pulmonary programs requires an intense amount of dedication across our entire team," Prabhakaran said. "That is evident every day as we approach patient care, physician training and medical research with determination and vigor."

In diabetes and endocrinology, the division continues to build on its well-established national and international reputation for exceptional care, research, education and

advocacy in Type 1 diabetes, said Michael J. Haller, MD, Professor and Chief of Pediatric Endocrinology.

The division also has a thriving metabolic program that uses individualized assessments of the underlying conditions that lead to obesity and pairs it with tailored therapy focused on healthier lifestyles.

One new initiative involves working on bringing telemedicine kiosks to UF/IFAS agricultural extension offices in rural, underserved counties. That, Haller said, will open up health care access to children without internet access at home. UF Health continues to be a world leader in comprehensive care for children with Prader-Willi Syndrome, a genetic condition that causes low muscle tone and early-onset weight gain and can lead to extreme appetites later in childhood. Haller said that expertise has broader implications because pharmaceutical companies are often interested in working with Prader-Willi patients to study potential obesity treatments.

"People are making UF Health a destination for specialized pediatric services because they know we have the expertise and experience to provide premier care," Haller said.

UF Health Shands CEO Ed Jimenez said ranking among the nation's elite pediatric hospitals in so many medical specialties is a natural outcome of putting children first.

"While we strive to be the best children's hospital in Florida, being among the nation's elite is great company. In a year of unprecedented challenges, these rankings affirm the best efforts of our pediatric researchers, physicians, nurses and staff. It vividly illustrates what everyone at UF Health strives for every day and what families expect: compassionate, world-class care supported by innovative medical research and expertise," Jimenez said.

The U.S. News Best Children's Hospital rankings are compiled from clinical data and a reputational survey of pediatric specialists across the country.

Watch the video: **https://www.youtube.com/watch?v=pDCUzL8EktQ**

NOVEMBER

12-13

CSI Focus LAA
Frankfurt, Germany
https://www.csi-congress.org/laa

19-20

2021 World Heart and Cardiothoracic Surgery Conference
Bangkok, Thailand
https://heart.episirus.org/

DECEMBER

03-04

CSI America 2021
Denver, Colorado
https://www.csi-congress.org/america

05-07

ICI for All 21 – Innovation in Cardiovascular Interventions Award
Tel Aviv, Israel
https://icimed.org/ici-award/

06-09

Echo on Marco Island: Case-Based Approach
Marco Island, Florida
https://cveducation.mayo.edu/store/echo-on-marco-island-case-based-approach

NEONATOLOGY TODAY
Peer Reviewed Research, News and Information in Neonatal and Perinatal Medicine

Neonatology Today is interested in publishing manuscripts from Neonatologists, Fellows, NNPs and those involved in caring for neonates on case studies, research results, hospital news, meeting announcements, and other pertinent topics.

Please submit your manuscript to: **LomaLindaPublishingCompany@gmail.com**

Making Waves in Predicting Aortic Aneurysms and Postpartum Complications

Pitt bioengineer Rama Mukkamala will study arterial waveforms as a predictive measure of aortic aneurysm size and fluid overload status in postpartum women

A ruptured abdominal aortic aneurysm is the 15th leading cause of death in the United States and has stolen the lives of everyday people and luminaries alike, such as Albert Einstein and George C. Scott. This unpredictable condition causes our body's largest vessel to dilate, often unnoticed until it is too late. Once ruptured, the mortality rate is roughly 80%.

The University of Pittsburgh's Ramakrishna Mukkamala will use his lab's expertise in cardiovascular health technology to advance a convenient monitoring device that can predict aortic aneurysm (AA) growth and the risk of rupture, using devices as common as a smartphone camera or smart scale. The project recently received a $410,344 award from the National Institutes of Health.

"This condition is typically detected by chance," said Mukkamala, Professor of Bioengineering at Pitt's Swanson School of Engineering and Professor of Anesthesiology and Perioperative Medicine at Pitt's School of Medicine. "Despite the risks associated with rupture, ultrasound scans are hardly used to screen for aortic aneurysms because they are too inconvenient. Our proposed device could create a bridge to ultrasound scans by providing a convenient and cost-effective way to indicate aneurysm size."

In this project, Mukkamala's team will study arterial waveforms to determine if they can be used as a non-imaging solution for AA screening. These measurements are easy to obtain because they can be recorded by placing a smartphone's camera on the neck or stepping onto a smart scale.

"We have already established that there is a connection between waveform measurements and aneurysm size," Mukkamala said. "We will use a collection of patient data to develop methods that can predict aneurysm size from these waveforms as accurately as possible."

If successful, the lab will develop a point-of-care device for AA screening and surveillance. This simple tool could be better than a physical exam and used in a routine doctor appointment to indicate if a more accurate ultrasound should be ordered.

"Ultimately, this simple step could be of value to patients unaware of a ticking time bomb in their chest," Mukkamala added. "As the general population ages, this type of work becomes increasingly more relevant."

Predicting Complications Postpartum

Another relevant cardiac health trend is the United States' growing maternal mortality rate -- the worst among industrialized countries.

The majority of maternal deaths occur postpartum and result from hypertensive disorders like preeclampsia and gestational hypertension. "A subset of women with high blood pressure in pregnancy develop fluid overload and heart failure symptoms postpartum, which can lead to an increased risk of hospital readmission and significant complications after delivery," explained Alisse Hauspurg, Assistant Professor of Obstetrics, Gynecology, and Reproductive Sciences at Pitt's School of Medicine.

Mukkamala is a co-investigator on an NIH Trailblazer award led by Hauspurg that also uses arterial waveforms to predict fluid buildup in patients with preeclampsia. Pitt's Sanjeev Shroff, Distinguished Professor and Gerald E. McGinnis Chair of Bioengineering; and Aman Mahajan, Peter and Eva Safar Professor and Chair of Anesthesiology and Perioperative Medicine and Professor of Bioengineering, will also collaborate on the project.

"Home blood pressure monitors improve manageability of hypertension," Mukkamala said, "but they do not reduce the incidence of postpartum hospital readmission related to fluid overload."

Mukkamala and Hauspurg will develop a smartphone-based device for convenient monitoring of postpartum fluid overload. Such a device could indicate which patients should receive more aggressive treatment prior to discharge and may potentially save the life of a new mother.

The aortic aneurysm R21 also includes Jin-Oh Hahn (Co-I), Associate Professor of Mechanical Engineering at the University of Maryland; Hao-min Cheng, Professor at the National Yang Ming Chiao Tung University; and Rabih Chaer, Professor of Surgery at Pitt. Hyagriv Simhan, Professor of Obstetrics, Gynecology, and Reproductive Sciences at Pitt, will collaborate on the Trailblazer award.

CHiP NETWORK
CONGENITAL HEART INTERNATIONAL PROFESSIONALS

CONGENITAL CARDIOLOGY TODAY

CORPORATE OFFICE

11500 Elk Horn Drive
Clarksburg, MD 20871 USA

CORPORATE TEAM

FOUNDER & SENIOR EDITOR
Tony Carlson
tcarlsonmd@gmail.com

CO-FOUNDER & MEDICAL EDITOR
John W. Moore, MD, MPH
jwmmoore1950@gmail.com

PUBLISHER & EDITOR-IN-CHIEF
Kate Baldwin
kate.f.baldwin@gmail.com

STAFF EDITOR & WRITER
Virginia Dematatis

EDITOR-IN-CHIEF EMERITUS
Richard Koulbanis

STAFF EDITOR
Loraine Watts

EDITORIAL BOARD

Teiji Akagi, MD
Zohair Al Halees, MD
Mazeni Alwi, MD
Felix Berger, MD
Fadi Bitar, MD
Jacek Bialkowski, MD
Mario Carminati, MD
Anthony C. Chang, MD, MBA
John P. Cheatham, MD
Bharat Dalvi, MD, MBBS, DM
Horacio Faella, MD
Yun-Ching Fu, MD
Felipe Heusser, MD
Ziyad M. Hijazi, MD, MPH
Ralf Holzer, MD
Marshall Jacobs, MD
R. Krishna Kumar, MD, DM, MBBS
John Lamberti, MD
Gerald Ross Marx, MD
Tarek S. Momenah, MBBS, DCH
Toshio Nakanishi, MD, PhD
Carlos A. C. Pedra, MD
Daniel Penny, MD, PhD
James C. Perry, MD
Shakeel A. Qureshi, MD
P. Syamasundar Rao, MD
Andrew Redington, MD
Carlos E. Ruiz, MD, PhD
Girish S. Shirali, MD
Horst Sievert, MD
Hideshi Tomita, MD
Gil Wernovsky, MD
Zhuoming Xu, MD, PhD
William C. L. Yip, MD
Carlos Zabal, MD

OFFICIAL NEWS & INFORMATION PARTNER OF

PICS Society

Pediatric *and Congenital* Interventional Cardiovascular Society

Statements or opinions expressed in Congenital Cardiology Today reflect the views of the authors and sponsors and are not necessarily the views of Congenital Cardiology Today.

© 2021 by Congenital Cardiology Today
ISSN 1554-7787 print. ISSN 1554-0499 electronic.
Published monthly. All rights reserved.