CONGENITAL CARDIOLOGY TODAY

Timely News and Information for BC/BE Congenital/Structural Cardiologists and Surgeons

August 2015; Volume 13; Issue 8
International Edition

IN THIS ISSUE

Upcoming Medical Meetings

2nd Annual Basic & Advanced Fetal Cardiac Symposium and Workshop
Sep. 10-12, 2015; Chicago, IL USA
www.FetalCardiacSymposium.com

PICS-AICS
Sep.18-21, 2015; Las Vegas, NV USA
www.picsymposium.com

34th Annual Echocardiography Symposium
Sep. 25-26, 2015; Miami, FL USA
MiamiEcho.Baptisthealth.net

48th Annual Southeast Pediatric Cardiiology Society Conference
Sep. 25-26, 2015; Birmingham, AL USA
www.ChildrensAL.org/SPCS2015

CONGENITAL CARDIOLOGY TODAY

Coarctation of the Aorta to the Rescue? Aortic Coarctation Assisting Pulmonary Circulation in a Patient with Einsenmenger Syndrome

By Joseph Tseng, BS; Jason McCourt, MD; Ernerio Alboliras, MD; Randall Fortuna, MD; Pankaj Jain, MD; Randy Richardson, MD

Introduction

Eisenmenger Syndrome (ES), a reversal of intracardiac blood flow resulting from an untreated congenital intracardiac shunt, is a condition with considerable morbidity and mortality. It represents pulmonary arterial hypertension (PAH) associated with a Congenital Heart Disease (CHD), as well as a multi-system disorder with multiple severe clinical complications.[1] Occurring in about 4% of adult congenital heart patients today, there has been a 50% decrease in frequency of ES since the 1950s due to increasing awareness and management techniques.[2] Patients with this condition frequently survive into their third or fourth decade of life, but may experience various symptoms such as dyspnea, cyanosis, and even sudden death due to cardiac arrhythmias.[2,3] Aortic coarctation, segmental stenosis of the aorta, is another cardiac anomaly that represents 5%-10% of all congenital cardiac lesions. It also represents 7% of all critically ill infants with heart disease.[4]

While ventricular septal defects are known to occur in a minor percentage of patients with aortic coarctation, the occurrence of resulting Eisenmenger Syndrome is extremely rare. The unique pathology causing this form of Eisenmenger Syndrome presents multiple difficult clinical decisions in patient management. We believe radiographic imaging and 3D reconstruction provides a detailed anatomical definition for optimal treatment planning and management.

> ***"Eisenmenger Syndrome (ES), a reversal of intracardiac blood flow resulting from an untreated congenital intracardiac shunt, is a condition with considerable morbidity and mortality."***

Case Report

An 18-year-old male that is oxygen dependent with a history of congenital aortic coarctation status post stent placement and pulmonary hypertension presented with a chief complaint of shortness of breath for two days. He had a temperature of 36.3˚C, heart rate of 80 bpm, blood pressure of 118/67, respiratory rate of 18 bpm, and oxygen saturation of 82% on 5L of oxygen.

NIT-OCCLUD®

COIL SYSTEM FOR PDA CLOSURE

A SAFER, EASIER WAY TO CLOSE

The Nit-Occlud® coil system for PDA closure is designed to match individual morphologies and sizes

The delivery system facilitates optimal device positioning

The Nit-Occlud® PDA coil is repositionable and retrievable prior to release

Tight and compact windings ensure efficient occlusion

The Nit-Occlud® PDA coil was determined to be MRI conditional

Radiopaque

For more information or to place an order, contact your B. Braun Interventional Systems Inc. representative or call 1-877-VENA-CAV (836-2228)

pfmmedical

Manufacturer:
pfm medical, ag
Wankelstraße 60
50996 Köln, Germany
T +49 (0)2236 9641-10
F +49 (0)2236 9641-20

B|BRAUN Interventional Systems

Distributed by:
B. Braun Interventional Systems Inc.
824 Twelfth Avenue
Bethlehem, PA 18018 USA
Tel: 1-877-VENA CAV (836-2228) (USA)
Fax: 1-610-849-1334
www.bisusa.org

Indication: The Nit-Occlud® PDA coil is a permanently implanted prosthesis indicated for percutaneous, transcatheter closure of small to moderate size patent ductus arteriosus with a minimum angiographic diameter less than 4mm. Nit-Occlud Brief Statement: Do not implant the Nit-Occlud PDA into patients who have endocarditis, endarteritis, active infection, pulmonary hypertension (calculated PVR greater than 5 Wood Units), thrombus in a blood vessel through which access to the PDA must be obtained, thrombus in the vicinity of the implantation site at the time of the implanttion or patients with a body weight < 11 lbs (5 kg). An angiogram must be performed prior to implantation for measuring length and diameter of the PDA. Only the pfm medical implantation delivery catheter should be used to implant the device. Administration of 50 units of heparin per kg body weight should be injected after femoral sheaths are placed. Antibiotics should be given before (1 dose) and after implantation (2 doses) in order to prevent infection during the implant procedure. Do not implant the Nit-Occlud PDA in an MR environment. Do not pull the Nit-Occlud coil through heart valves or ventricular chambers. Contrast media should not be injected through the implantation catheter. The catheter must not be connected to high pressure injectors. Patients may have an allergic response to this device due to small amounts of nickel that has been shown to be released from the device in very small amounts. If the patient experiences allergic symptoms, such as difficulty in breathing or swelling of the face or throat, he/she should be instructed to seek medical assistance immediately. Antibiotic prophylaxis should be performed to prevent infective endocarditis during first 6 months after coil implantation. Potential Adverse Events: Air embolism, Allergic reaction to drug/contrast, Apnea, Arrhythmia requiring medical treatment or pacing, Arteriovenous fistula, Bacterial endocarditis, Blood loss requiring transfusion, Chest pain, Damage to the tricuspid or pulmonary valves, Death, Embolization of the occluder, requiring percutaneous or surgical intervention, Endarteritis, False aneurysm of the femoral artery, Fever,Headache/migraine, Heart failure, Hemolysis after implantation of the occluder, Hypertension, Hypotension or shock, Infection, Myocardial infarction, Occluder fracture or damage, Perforation of the heart or blood vessels, Stenosis of the left pulmonary artery or descending thoracic aorta, Stroke/TIA, Thromboembolism (cerebral or pulmonary), Valvular Regurgitation, Vessel damage at the site of groin puncture (loss of pulse, hematoma etc.)

A CT chest angiogram with 3D renderings was obtained for further workup and evaluation. The CT demonstrated aortic coarctation with a stent in place and prominent aortic dilatation proximal to the coarctation (Figures 1 and 2). Additional findings included two ventricular septal defects and severely dilated right ventricle, main pulmonary trunk, and bilateral pulmonary arteries (Figures 3-5). Right main stem bronchus compression from the dilated pulmonary artery was also observed (Figure 6). Although directional blood flow was not evaluated, findings were consistent with Eisenmenger Syndrome resulting from chronic VSDs.

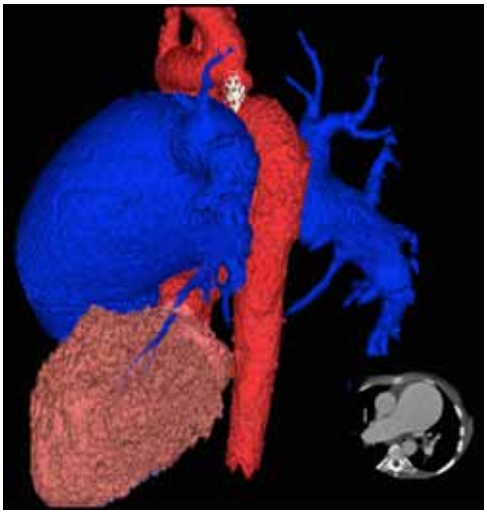

Figure 1. CT 3D reconstruction demonstrating aortic coarctation with stent placement (white) and prominent aortic dilatation distal to the coarctation.

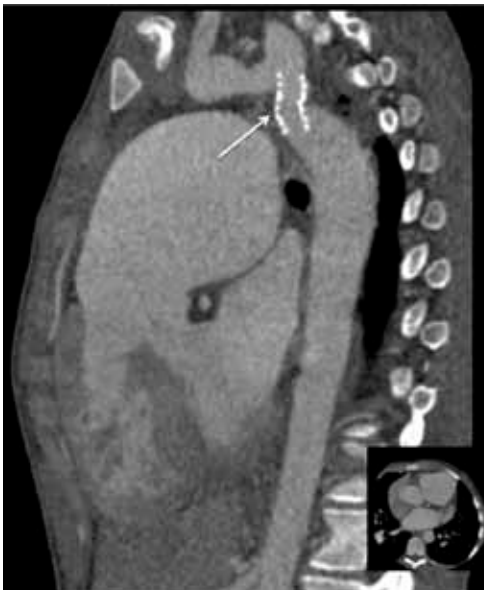

Figure 2. Saggital CT demonstrating aortic stent placement (arrow) in the region of coarctation.

Discussion

An extreme manifestation of PAH, Eisenmenger Syndrome is reversed blood flow away from the pulmonary arterial system toward the aorta through a ventricular septal defect. Typically, this process begins as a left-to-right shunt, which results in increased blood flow to the pulmonary system. As this occurs, the pulmonary arterial vasculature experiences shear stress and circumferential stretch, which leads to endothelial dysfunction and vascular remodeling. Specifically, the smooth muscle cells proliferate and there is a concomitant increase in extracellular matrix production. In some cases, this cellular damage and remodeling may even promote formation of an intravascular thrombosis. These developments eventually lead to an increase in pulmonary vascular resistance and ultimately result in cyanosis due to an inverted, or right-to-left shunt. Shunt reversal causes blood flow being directed away from the pulmonary system and towards the systemic circulatory system.

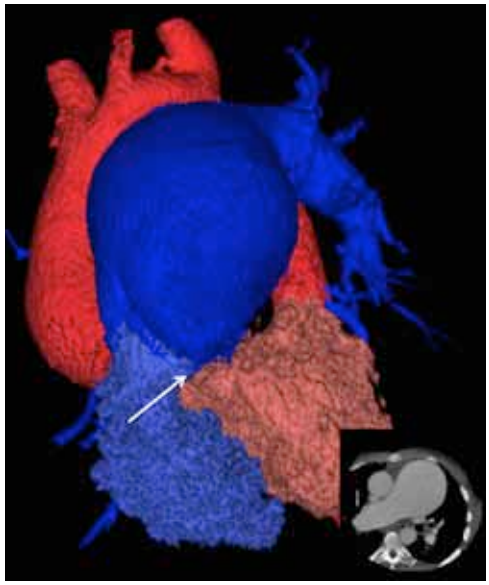

Figure 3. CT 3D reconstruction demonstrating pulmonary artery dilatation and subpulmonic VSD (arrow).

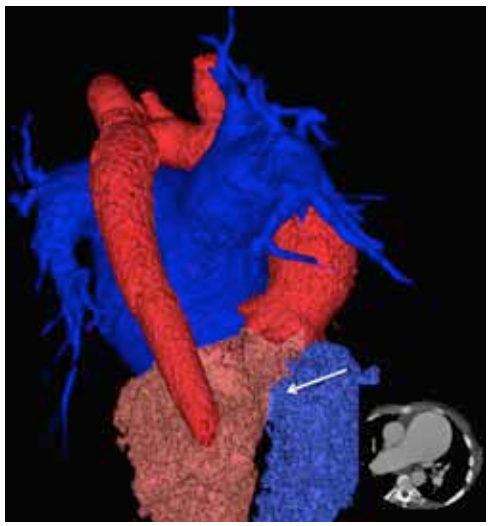

Figure 4. CT 3D reconstruction demonstrating distal pulmonary arterial pruning (blue) and perimembranous VSD.

Traditionally, management options for patients with ES were limited to palliative measures or heart-lung transplantation. Unfortunately, heart-lung transplant is typically reserved for patients with more severe ES and, like most transplant operations, is associated with a high

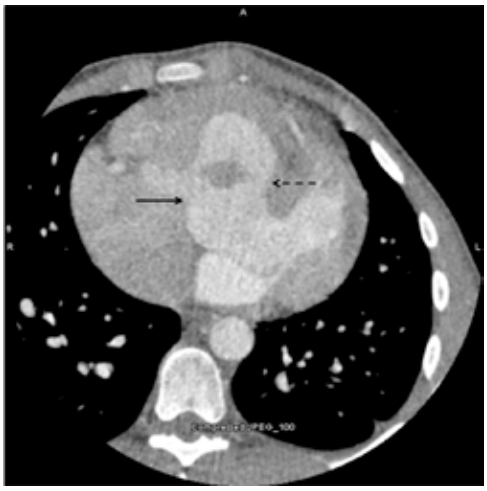

Figure 5. Axial CT demonstrating perimembranous (dashed arrow) and subpulmonic (arrow) VSDs.

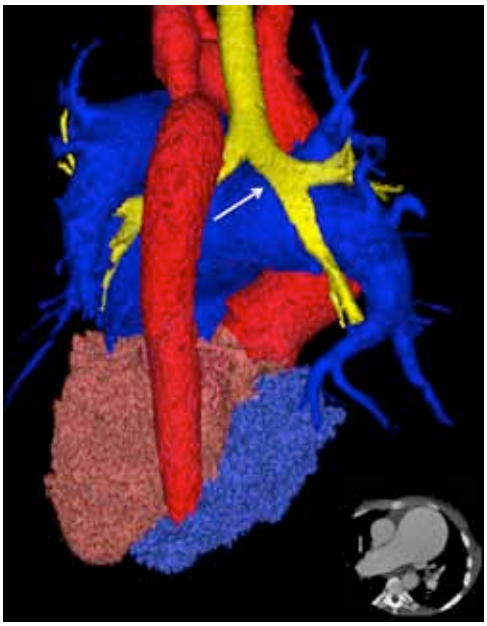

Figure 6. CT 3D reconstruction demonstrating right main stem bronchus compression from dilated pulmonary artery (arrow).

perioperative mortality.[5,6] The mainstay of care has generally focused on not disturbing the balanced systemic and pulmonary circulation.[7] Pharmacological treatment with medications such as digitalis, diuretics, antiarrhythmics, and anticoagulants have also been investigated, though none of these approaches have indicated modified survival or risk of deterioration.[8] Since right heart failure is a potential complication of ES, digoxin has also been proposed as a management option, although the evidence supporting this is still weak.[9] While there has been no definitive evidence supporting the use of these pharmacological treatments, an increase in the understanding of the molecular biology of right heart failure development in ES may offer novel therapeutic agents in the future.

This case describes a rare type of Eisenmenger Syndrome. The existence of the aortic coarctation is believed to provide sufficient backpressure on the right heart system to promote blood flow to the lungs. While this aortic coarctation may be assisting in pulmonary circulation, it creates additional difficulties in clinical management. It is theorized that repair of the VSD will remove the backpressure caused by the coarctation, and the right ventricle will not be able to produce adequate pressure to overcome the pulmonary arterial hypertension and circulate blood through the lungs. Heart transplant may be the ultimate solution. Together, contrast enhanced cross-sectional imaging and 3D reconstructions produce superior anatomical detailing, which undoubtedly provides optimal clinical management on a personalized case basis.

"Traditionally, management options for patients with ES were limited to palliative measures or heart-lung transplantation."

Biographical Sketch of Corresponding Author

Joseph Tseng is currently a third year medical student at Creighton University School of Medicine, Phoenix Regional Campus. He is from Southern California, and completed his Bachelor of Arts in molecular biology at Pomona College.

References

1. Wood P. The Eisenmenger syndrome or pulmonary hypertension with reversed central shunt. British medical journal. Sep 27 1958;2(5099):755-762.
2. Diller GP, Gatzoulis MA. Pulmonary vascular disease in adults with congenital heart disease. Circulation. Feb 27 2007;115(8):1039-1050.
3. Beghetti M, Galie N. Eisenmenger syndrome a clinical perspective in a new therapeutic era of pulmonary arterial hypertension. Journal of the American College of Cardiology. Mar 3 2009;53(9):733-740.
4. Teo LL, Cannell T, Babu-Narayan SV, Hughes M, Mohiaddin RH. Prevalence of associated cardiovascular abnormalities in 500 patients with aortic coarctation

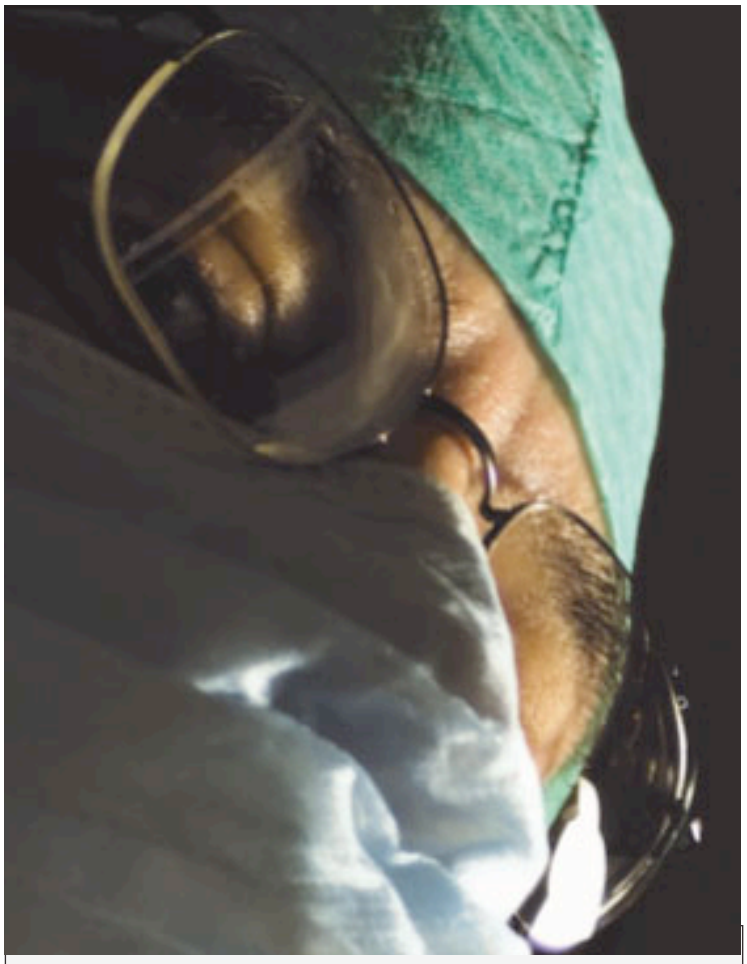

PROVEN PERFORMANCE. SIMPLY DELIVERED.

MELODY TPV DELAYS CONDUIT REPLACEMENT

98% Patients at 2 years

91% Patients at 5 years

Data from US IDE Study

Melody®
Transcatheter Pulmonary Valve Therapy

Important Labeling Information for Geographies Outside of the United States

Indications: The Melody® Transcatheter Pulmonary Valve is indicated for use in patients with the following clinical conditions:

- Patients with regurgitant prosthetic Right Ventricular Outflow Tract (RVOT) conduits with a clinical indication for invasive or surgical intervention, OR
- Patients with stenotic prosthetic RVOT conduits where the risk of worsening regurgitation is a relative contraindication to balloon dilatation or stenting.
- Existence of a full (circumferential) RVOT conduit that was equal to or greater than 16 mm in diameter when originally implanted.
- The intended lifetime for the Melody® device is 2 years.

Contraindications

- Venous anatomy unable to accommodate a 22 Fr size introducer sheath; Implantation in left heart;
- Unfavorable right ventricular outflow tract for good stent anchorage;
- Severe right ventricular outflow obstruction, which cannot be dilated by balloon;
- Obstruction of the central veins;
- Clinical or biological signs of infection;
- Active endocarditis;
- Known allergy to aspirin or heparin;
- Pregnancy.

Potential Complications / Adverse Events

Potential procedural complications that may result from implantation of the Melody device include the following: rupture of the RVOT conduit, compression of a coronary artery, perforation of a major blood vessel, embolization or migration of the device, perforation of a heart chamber, arrhythmias, allergic reaction to contrast media, cerebrovascular events (TIA, CVA), infection/sepsis, fever, hematoma, radiation-induced erythema, pain at the catheterization site.

Potential device-related adverse events that may occur following device implantation include the following: stent fracture resulting in recurrent obstruction, endocarditis, embolization or migration of the device, valvular dysfunction (stenosis or regurgitation), paravalvular leak, valvular thrombosis, pulmonary thromboembolism, hemolysis.

For additional information, please refer to the Instructions For Use provided with the product.

The Melody® Transcatheter Pulmonary Valve and Ensemble® Transcatheter Delivery System has received CE Mark approval and is available for distribution in Europe. Additionally, a Medical Device Licence has been granted and the system is available for distribution in Canada.

Non destiné au marché français.

Melody-TPV.com

Europe
Medtronic International Trading Sàrl
Route du Molliau 31
Case postale 84
CH-1131 Tolochenaz
Switzerland
Tel: 41.21.802.7000
Fax: 41.21.802.7900

LifeLine
CardioVascular Technical Support
Tel: (877) 526-7890
E-mail: rs.cstechsupport@medtronic.com

Medtronic

referred for cardiovascular magnetic resonance imaging to a tertiary center. Pediatric cardiology. Dec 2011;32(8): 1120-1127.
5. Galie N, Torbicki A, Barst R, et al. Guidelines on diagnosis and treatment of pulmonary arterial hypertension. The Task Force on Diagnosis and Treatment of Pulmonary Arterial Hypertension of the European Society of Cardiology. European heart journal. Dec 2004;25(24):2243-2278.
6. Berman EB, Barst RJ. Eisenmenger's syndrome: current management. Progress in cardiovascular diseases. Sep-Oct 2002;45(2):129-138.
7. Oechslin E, Mebus S, Schulze-Neick I, et al. The Adult Patient with Eisenmenger Syndrome: A Medical Update after Dana Point Part III: Specific Management and Surgical Aspects. Current cardiology reviews. Nov 2010;6(4):363-372.
8. Daliento L, Somerville J, Presbitero P, et al. Eisenmenger syndrome. Factors relating to deterioration and death. European heart journal. Dec 1998;19(12):1845-1855.
9. Satoh T, Yagi T, Kato S, et al. A 38-year-old man with pulmonary hypertension, who had undergone atrial septal closure 26 years previously. The Keio journal of medicine. Dec 2003;52(4):250-262.

CCT

Joseph Tseng, BA
St. Joseph's Hospital and Medical Center and Creighton University School of Medicine
350 West Thomas Rd.
Phoenix, AZ 85013 USA
Tel. 714.336.6914
josephjtseng@gmail.com

Ernerio Alboliras, MD
Pediatric Cardiology and Cardiothoracic Surgery
Cardon Children's Medical Center
1400 S. Dobson Rd., 2nd Floor
Mesa, AZ 85202 USA

Randall Fortuna, MD
Pediatric Cardiology and Cardiothoracic Surgery
Cardon Children's Medical Center
1400 S. Dobson Rd., 2nd Floor
Mesa, AZ 85202 USA

Pankaj Jain, MD
Pediatric Cardiology and Cardiothoracic Surgery
Cardon Children's Medical Center
1400 S. Dobson Rd., 2nd Floor
Mesa, AZ 85202 USA

Randy Richardson, MD
Department of Radiology
St. Joseph's Hospital and Medical Center and Creighton University School of Medicine
350 West Thomas Rd.
Phoenix, AZ 85013 USA

Image of the Month #11 – August 2015 from the Archiving Working Group

Contributors: Charles W. Shepard, MD; Robert H. Anderson, MD; Vera D. Aiello, MD; Diane E. Spicer, BS, MD; Jeffrey P. Jacobs, MD; James St. Louis, MD; Jorge M. Giroud, MD; Allen D. Everett, MD

IPCCC: Codes for coronary fistulas or sinusoids associated with:
- Pulmonary atresia and intact ventricular septum: 01.01.07, 09.45.00
- HLHS with aortic atresia: 01.01.09, 09.15.03, 06.02.92, 09.45.00, 10.10.12, 12.10.00

AEPC Derived Term
- For pulmonary atresia and intact ventricular septum
  - Pulmonary atresia + intact ventricular septum (01.01.07)
  - Coronary fistula(s) or sinusoids (09.45.00)
- For HLHS
  - Hypoplastic Left Heart Syndrome (01.01.09)
  - Aortic atresia (09.15.03)
  - Mitral stenosis (06.02.92)
  - Coronary fistula(s) or sinusoids (09.45.00)
  - Endocardial fibroelastosis (10.10.12)
  - Norwood-type procedure (12.10.00)

EACTS-STS Derived Term
- For pulmonary atresia and intact ventricular septum
  - Pulmonary atresia-IVS (01.01.07)
  - Coronary artery fistula(s) or sinusoid(s), (Coronary-cameral fistula(s)) present (09.45.00)
- For HLHS
  - Hypoplastic Left Heart Syndrome (HLHS), Aortic atresia + Mitral stenosis (01.01.09, 09.15.03, 06.02.92)
  - Coronary artery fistula(s) or sinusoid(s), (Coronary-cameral fistula(s)) present (09.45.00)
  - Endocardium disease[s], Endocardial fibroelastosis (10.10.12)
  - Norwood (Stage 1) (12.10.00)

ICD10 Derived Term
- For pulmonary atresia and intact ventricular septum
  - Pulmonary valve atresia (Q22.0)
  - Malformation of coronary vessels (Q24.5)
- For HLHS
  - Hypoplastic Left Heart Syndrome (Q23.4)
  - Congenital stenosis of aortic valve: Congenital aortic atresia (Q23.0)
  - Congenital mitral stenosis: Congenital mitral atresia (Q23.2)
  - Malformation of coronary vessels (Q24.5)
  - Endocardial fibroelastosis (I42.4)

Commentary

The presence of coronary arterial-to-ventricular fistulas with intact ventricular septum, in association with ventricular outflow tract atresia, has long been noted. Most commonly, it is in the setting of pulmonary atresia with intact ventricular septum that this phenomenon is seen. Less commonly, it is also recognized in the Hypoplastic Left Heart Syndrome with aortic atresia, intact ventricular septum and a patent mitral valve. It is thought that the underlying relationship is the presence of a patent inlet valve (tricuspid or mitral) and anatomical atresia of the outflow tract (pulmonary or aortic).

Understanding why there should be persistence of fistulous communications between the ventricular cavities and the coronary arteries is now aided by recent findings regarding the development of the coronary arteries. Although there are subtle differences between the arrangement of the coronary arteries in mice as opposed to humans, in that the arteries are directly subepicardial in man, but located within the superficial parts of the ventricular myocardium in mice, the mechanisms of formation are the same. Prior to closure of the embryonic interventricular communication, which occurs at around eight weeks of development in man, and during the thirteenth and fourteenth days of development in the mouse, the ventricular walls are made up largely of a meshwork of trabeculations, with minimal formation of the compact components of the walls. Subsequent to closure of embryonic interventricular communication, there is rapid proliferation of the compact myocardium, which then requires nourishment from the developing epicardial coronary arteries, which at more-or-less the same time establish their connections with the developing aortic root. Prior to this stage, when the ventricular walls have been composed largely of the trabecular meshwork, nourishment of the myocardial components is feasible by direct perfusion from the ventricular cavities. With ongrowing development of the compact part of the ventricular walls, there is effective diminution in the thickness of the trabecular components of the wall. Sometimes, however, the trabecular components continue to proliferate, producing the arrangement inappropriately described as "non-compaction." It is better considered as persistent fetal trabeculation. The fistulous communications seen in both pulmonary atresia and aortic atresia in the setting of an intact ventricular septum almost certainly represent persistence of the connections between the trabecular components of the wall and the developing intramural coronary arteries, connections that would normally disappear if ventricular development had proceeded in normal fashion, without the production of outlet atresia. The finding, on occasion, of persistent fetal trabeculation in both ventricles in the setting of pulmonary atresia with intact septum (PA-IVS), but with a well-formed cavity of the right ventricle (RV), and a large fistulous communication with the anterior interventricular artery (Additional Images 1 and 2), is supportive of these notions of development.

With some important exceptions, the routine surgical palliation of PA/IVS with RV-dependent coronary circulation is focused on the eventual creation of a total cavo-pulmonary circulation. In general, patients with RV-dependent coronary circulation lack a typical tripartite RV, and have a hypoplastic tricuspid valve precluding a two-ventricle repair. The initial decisions during the neonatal period are crucial to the overall survival of the patient. The initial surgical strategy should focus on the degree of coronary perfusion from the right ventricle, and the need for adequate pulmonary blood flow. Regardless of the degree of dependence, any procedure that has the potential to lower the systemic or supra-systemic pressures within the RV may result in significant myocardial ischemia. If the origin of the coronary arteries is typical, in other words with origin from the aorta, then a routine Modified Blalock-Taussig shunt may be undertaken. This will ensure both adequate coronary arterial and pulmonary blood flow while palliating the child for a second stage superior cavo-pulmonary shunt. When the coronary arteries do not originate from the aorta, then the mortality from even a routine shunt is significant, and immediate consideration of cardiac transplantation should be considered.

AWG Web Portal Link for This Series of Images

http://ipccc-awg.net/Coronary_Disease/Coronary_Artery_Fistula_09_45_00/Coronary_Artery_Fistula_PAA_09_45_00.html
http://ipccc-awg.net/HLHS/HLHS_AA_MS_Fistula_01_01_09/HLHS_AA_MS_Fistula_01_01_09.html

Innovations in Pediatric Heart Failure Symposium

Sponsored by

December 3-5, 2015, San Diego, CA

LOEWS CORONADO BAY RESORT

www.SDPedsCardiology.com

This state-of-the-art, interactive program is specifically designed for those involved in the care of patients with pediatric heart disease including pediatric cardiologists, surgeons, intensivists, nurses, trainees and other allied health professionals. Nationally recognized faculty members from over 20 institutions will cover challenging heart failure topics related to: cardiomyopathies, end stage congenital heart disease (including failing Fontans), heart transplantation, ventricular assist devices, interventional cardiology, cardiac ICU management, nursing care, genomics, cardiac imaging, pharmacotherapeutics, ethics and end of life care, electrophysiology and more!

Our focus will be on innovation, and as such, the conference format will be unique! There will be interactive sessions that are case-based and dependent on audience participation. Expert panels will be assembled to help answer the difficult management questions the clinician faces in their practice. Didactic sessions will be limited to short PowerPoint presentations. Workshops will be available to provide hands-on training for trainees, nurses and junior faculty members.

Confirmed guest faculty members include:

Juan Chuck Alejos, MD
Mattel Children's Hospital UCLA

Daniel Bernstein, MD
Lucile Packard Children's Hospital Stanford

Elizabeth Blume, MD
Boston Children's Hospital

Charles E. Canter, MD
St. Louis Children's Hospital

Brian Feingold, MD, MS
Children's Hospital of Pittsburgh of UPMC

Daphne T. Hsu, MD
The Children's Hospital at Montefiore

John Lynn Jefferies, MD, MPH, FAAP, FACC, FAHA
Cincinnati Children's Hospital Medical Center

Paul F. Kantor, MBBCh, FRCPC
Stollery Children's Hospital

Yuk M. Law, MD
Seattle Children's Hospital

Steven Lipshultz, MD, FAAP, FAHA
Children's Hospital of Michigan

Seema Mital, MD, FACC, FAHA, FRCP(C)
The Hospital for Sick Children Toronto

Shelley Miyamoto, MD
Colorado Children's Hospital

David L.S. Morales, MD
Cincinnati Children's Hospital Medical Center

Elfriede Pahl, MD, FACC, FAHA
Ann and Robert Lurie Children's Hospital

Jack F. Price, MD
Texas Children's Hospital

David Rosenthal, MD
Lucile Packard Children's Hospital Stanford

Joseph W. Rossano, MD, MS
The Children's Hospital of Philadelphia

Robert E. Shaddy, MD
The Children's Hospital of Philadelphia

Jeffrey A, Towbin, MD
Le Bonheur Children's Hospital

Steven A. Webber, MBChB, MRCP
Monroe Carell Jr. Children's Hospital at Vanderbilt

Steven Zangwill, MD
Phoenix Children's Hospital

Course Director:
Rakesh K. Singh, MD, MS
Rady Children's Hospital-San Diego

Need more information? cme@rchsd.org
858-576-1700, ext. 4972.

innovation
belongs in every moment

The outcomes and management of patients with coronary arterial to ventricular fistulas associated with Hypoplastic Left Heart Syndrome (HLHS) is far less understood than other anomalies with this association. The overall incidence of these fistulas is between 10% to 15%. They are arguably less frequent than the communications seen in the setting of pulmonary atresia with intact septum because of the usual presence of dense endocardial fibroelastosis when the left ventricle is grossly hypoplastic, but receives blood through a stenotic mitral valve. In this regard, these communications occur exclusively in the subset of patients with mitral stenosis and aortic atresia. Although no significant series currently is available, there does not appear to be an increased mortality associated with this particular subset of patients. An important point is that, in those patients who failed to survive the initial stage of palliation, the death was attributed to ongoing myocardial ischemia. This would lead to the observation that perhaps a shunt placed from the right ventricle to the pulmonary arteries during the Norwood procedure would be beneficial, as opposed to a traditional Modified Blalock-Tausig shunt.

Pulmonary Atresia and Intact Ventricular Septum

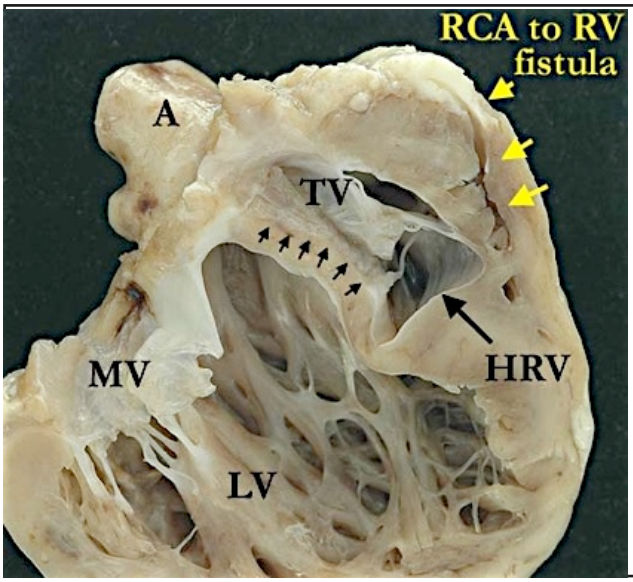

Description: This four-chamber view of a heart with pulmonary atresia and intact ventricular septum demonstrates a hypoplastic right ventricle (HRV) with a right coronary artery (RCA) to right ventricular (RV) fistula. Although not shown in this image, the right coronary artery is dilated and thick walled along nearly its entire length. The muscular ventricular septum is thin, and there is an Ebstein-like malformation of the septal leaflet of the tricuspid valve (TV). The septal leaflet is adherent to the septum along is entire length (black arrows). (A-aorta, LV-left ventricle, MV-mitral valve).

Contributor: Diane E. Spicer, BS
Source: Congenital Heart Institute of Florida

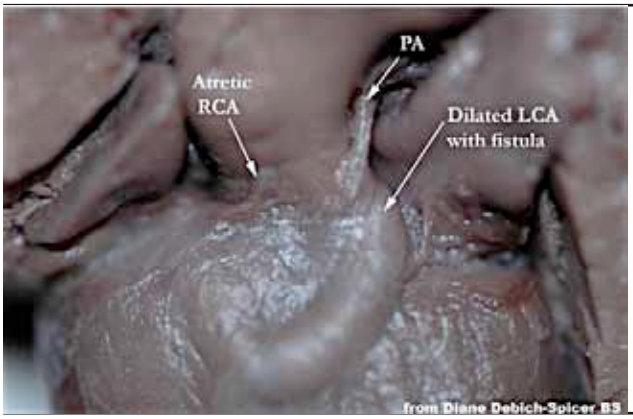

Description: This antero-superior view of a different heart with pulmonary atresia and intact ventricular septum (not shown) demonstrates an atretic pulmonary trunk (PA) with a fistulous communication from the left coronary artery (LCA) to the right ventricular cavity (not shown). The left coronary artery is dilated along nearly its entire length.

Contributor: Diane E. Spicer, BS
Source: Congenital Heart Institute of Florida

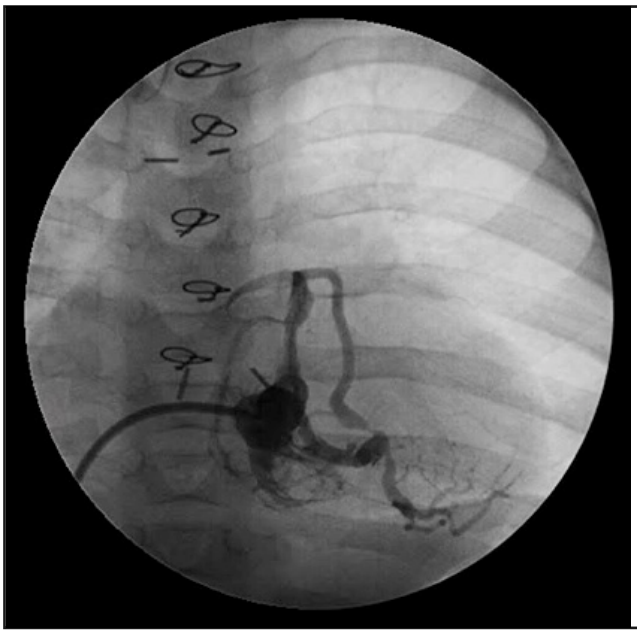

Description: This angiocardiogram, from another patient with pulmonary atresia and intact ventricular septum, illustrates the fistulous connection between the left coronary artery and the hypoplastic right ventricular cavity. Note that there is a significant obstruction in the mid-portion of the anterior interventricular coronary artery created by the fistulous connection. Flow occurs only during systole, and there is retrograde filling of the ascending aorta.

Contributor: Jorge M. Giroud, MD
Source: Congenital Heart Institute of Florida

Watch video (Internet required)

http://ipccc-awg.net/Coronary_Disease/Coronary_Artery_Fistula_09_45_00/Angio_PA_Atresia_Fistula_flv.htm


International Cardiology Neonatology Symposium™
International Cardiology Neonatology Symposium
October 8-10, 2015
InterContinental® • Miami, FL
TARGET AUDIENCE:
• pediatric cardiologists
• neonatologists
• cardiac surgeons
• intensivists
• physician assistants
• advanced practice nurses
• bedside clinical nurses in NICU and CVICU
• perfusionists
• pediatric cardiology and neonatology fellows
• pediatric residents
www.neocardisymposium.com

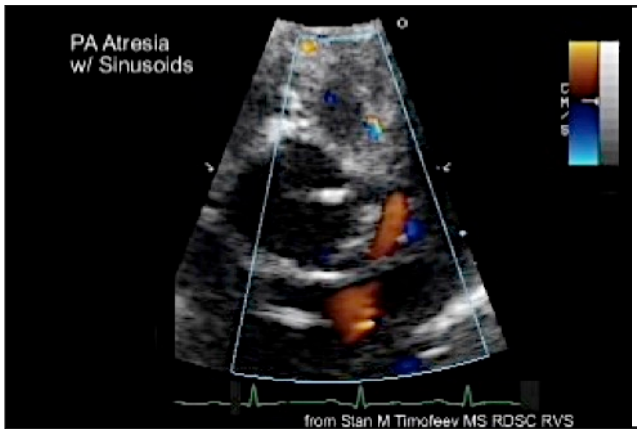

Description: This echocardiogram from a patient with pulmonary atresia illustrates the fistulous connection between the left coronary artery and the hypoplastic right ventricular cavity. Note that the color doppler evaluation demonstrates the abnormal connections between the coronary arteries and right ventricle, but cannot image obstructions to the coronary arteries with the precision of an angiogram.

Contributor: Stan Timofeev, MS
Source: Congenital Heart Institute of Florida

Watch for video (Internet required)

http://ipccc-awg.net/Coronary_Disease/Coronary_Artery_Fistula_09_45_00/Echo_PA_Atresia_Fistula_flv.htm

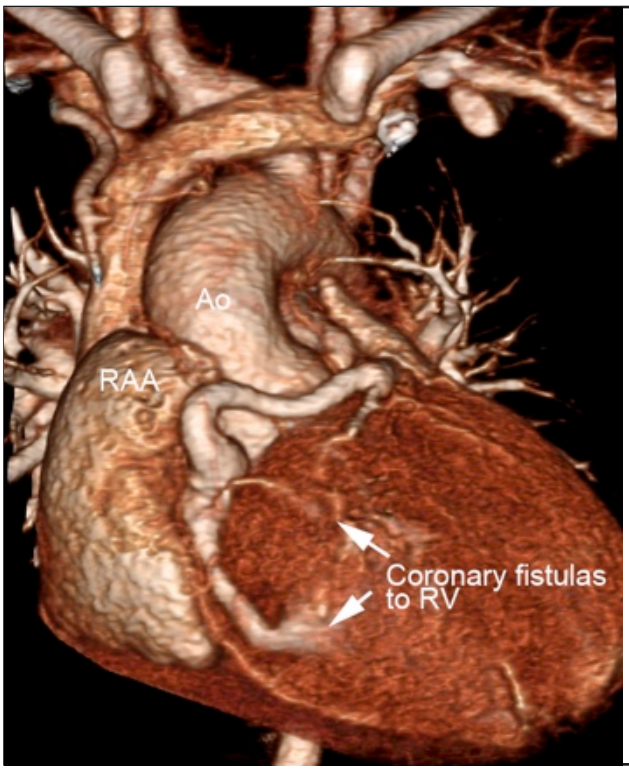

Description: This CT angiographic image from an anterior view is of a newborn with pulmonary atresia with intact ventricular septum. A common coronary artery originates from the left-sided adjacent aortic sinus, with fistulous connections to the right ventricle.

Contributor: Charles Shepard, MD
Source: University of Minnesota Children's Hospital

HLHS with Aortic Atresia

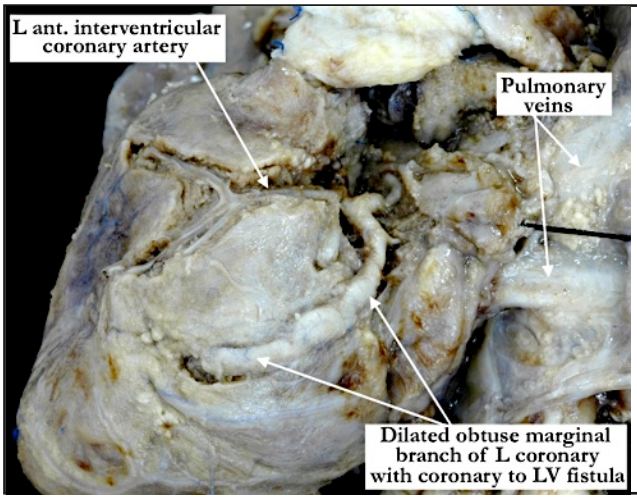

Description: This hypoplastic left heart is from a patient who has undergone the Norwood procedure. The anterior interventricular branch of the left coronary artery is small, and lies within the muscle along the majority of its course. There is a markedly dilated obtuse marginal branch that dives into the muscle toward the apex of the hypoplastic left ventricle. The neoaorta and the pulmonary veins provide anatomic orientation.

Contributor: Diane E. Spicer, BS
Source: Idriss Archive, Lurie Children's Hospital, Chicago, IL

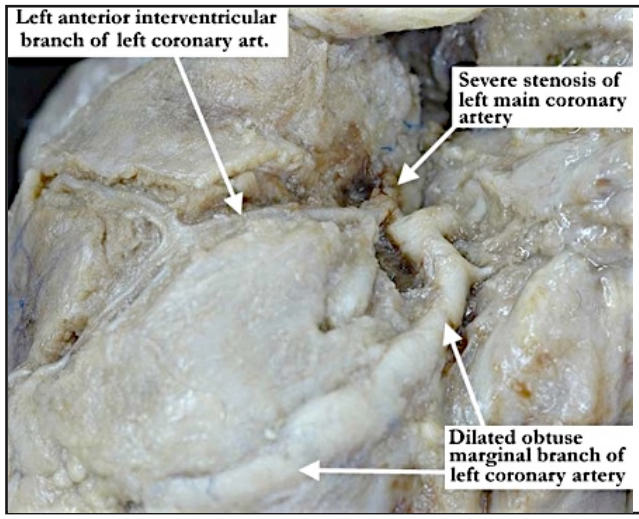

Description: A close-up view of the image shown on the left panel reveals the severe stenosis of the left main stem of the left coronary artery. The thickened, dilated obtuse marginal branch is very stenotic at its branch point from the left main stem coronary artery.

Contributor: Diane E. Spicer, BS
Source: Idriss Archive, Lurie Children's Hospital, Chicago, IL

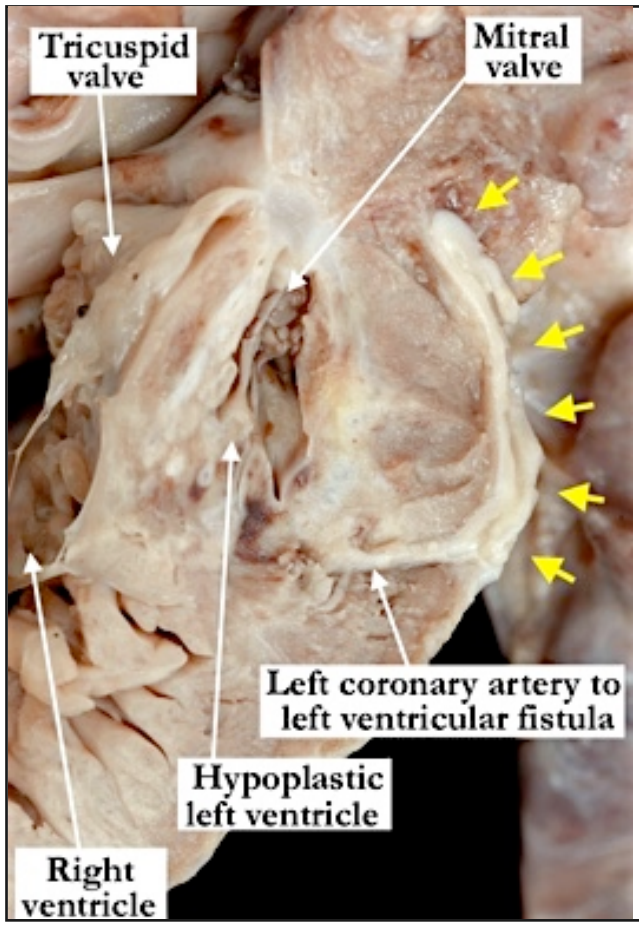

Description: This close-up view simulates a four chamber echocardiographic view. There is endocardial fibroelastosis of the small left ventricle along with multiple, white fibrotic areas in the subendocardial region of both the ventricle and the interventricular septum. The thickened, dilated obtuse marginal branch (yellow arrows) of the left coronary artery has been bisected as it extends over the epicardial surface. Where it dives into the myocardium, a fistula is formed between it and the hypoplastic left ventricle. A thickened, markedly hypoplastic mitral valve guards the left ventricular inlet.

Contributor: Diane E. Spicer, BS
Source: Idriss Archive, Lurie Children's Hospital, Chicago, IL

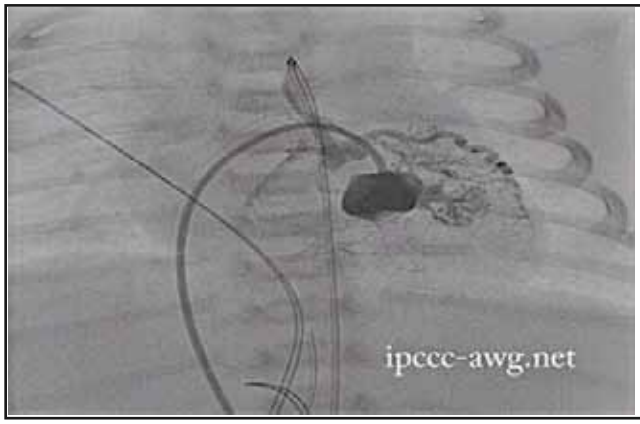

Description: This injection shows the hypoplastic left ventricle with opacification of the anterior interventricular coronary artery, filling from the left ventricle through ventriculo-coronary fistulas. The hypoplastic aorta is filled by the abnormal coronary arterial connections in a retrograde fashion. Note the distance between the mass of the left ventricle and aorta.

Contributor: Jorge M. Giroud, MD
Source: Congenital Heart Institute of Florida

Watch video (Internet required)

http://ipccc-awg.net/HLHS/HLHS_AA_MS_Fistula_01_01_09/Angio_LV_CA_Fistula.html

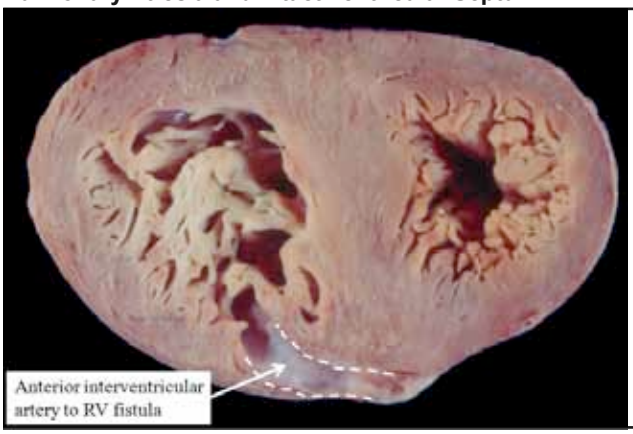

Additional Images 1- Short-axis section of a heart with pulmonary atresia and intact ventricular septum showing a huge fistulous communication (outlined) between the anterior interventricular branch of the left coronary artery and the right ventricle.

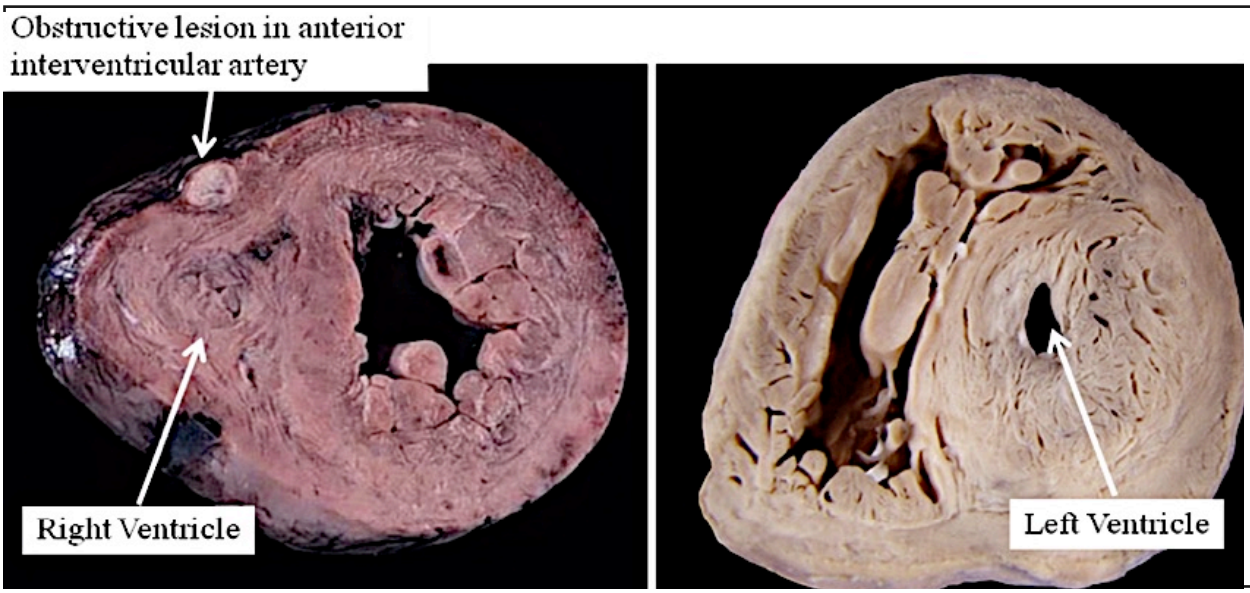

Additional Images 2 - Short-axis sections of two hearts showing deep trabecular recesses in the myocardial walls, which provide coronary-cavitary communications. Left panel - pulmonary atresia; Right panel- aortic atresia.

Please visit us at the AWG Web Portal a http://ipccc-awg.net/, and help in the efforts of the Archiving Working Group and the International Society for Nomenclature of Paediatric and Congenital Heart Disease.

The authors would like to acknowledge the Children's Heart Foundation (www.childrensheartfoundation.org/) for financial support of the AWG Web Portal.

CCT

Charles W. Shepard, MD
Archiving Working Group
University of Minnesota
Amplatz Children's Hospital, Department of Pediatrics,
Minneapolis, MN USA

Robert Anderson, MD
Co-Chairman, Archiving Working Group
Institute of Genetic Medicine, Newcastle University, Newcastle upon Tyne, United Kingdom

Vera D. Aiello, MD
Co-Chairman, Archiving Working Group
Heart Institute (InCor), São Paulo University School of Medicine,
São Paulo, Brazil

Diane E. Spicer, BS
Senior Archivist, Archiving Working Group
University of Florida, Department of Pediatrics-Cardiology, Gainesville, Florida and the Congenital Heart Institute of Florida, St. Petersburg & Tampa, FL USA

Jeffrey P. Jacobs, MD
Archiving Working Group
Professor of Surgery, Cardiovascular and Thoracic Surgeon, Johns Hopkins Children's Heart Surgery,
All Children's Hospital and Florida Hospital for Children
Saint Petersburg, FL USA

James D. St. Louis, MD
Archiving Working Group
Professor and Surgical Director, Cardiac Transplantation
University of Missouri-KC School of Medicine
Children's Mercy Hospital
Kansas City, MO USA

Allen D. Everett, MD
Archiving Working Group
Johns Hopkins University
Helen B. Taussig Heart Center
Charlette R. Bloomberg Children's Center
Baltimore, MD USA

Corresponding Author

Jorge M. Giroud, MD
Co-Chairman, Archiving Working Group
Congenital Heart Institute of Florida & Pediatrix Medical Group
St. Petersburg & Tampa, FL USA
jorgemgiroud@gmail.com

And the members of the Archiving Working Group of the International Society for Nomenclature of Paediatric and Congenital Heart Disease

Physician Considerations in Selecting a Procedure-Specific Medical Device

By Mark Cibuzar

Decisions, Decisions!

Given the growing number of new products and technologies for the treatment of congenital and structural heart defects and disease, choosing the best device for a particular patient's clinical condition can be a daunting task. The type and number of products to address patient conditions such as such as Atrial Septic Defect (ASD), Left Atrial Appendage (LAA)-related stroke, and diseased aortic, mitral, and pulmonary valves has proliferated over recent years as medical device companies enter or expand these markets with new and varied product offerings. These product decisions become more complex for the implanting physician as other healthcare providers (clinicians, materials management, and administrators) and often the patient's family, may weigh in on the final product/therapy selected. Such collaboration seems to be the norm; whether or not the collaboration makes for a better decision is the subject for another article.

The opening statement does not imply that only new products should be considered. Older products, having withstood the test of time and generally having substantive clinical evidence, are usually good options and in many cases may actually be preferred.

While this article may or may not make the ultimate device decision any easier, its purpose is to outline key points that implanting physicians and healthcare providers should consider. The theme focuses on but is not exclusive only to implantable devices, but does consider the international community and the wider variety of available devices.

Assuming the patient's need and indication can be treated via minimal intervention (device implantation) and not surgery, many things other than a specific product's indication for use need to be considered, and may be grouped as follows:

- Patient Anatomy and Device Characteristics
- Device Regulatory Approvals
- Physician Experience
- Clinical Evidence
- Manufacturer/Supplier/Sales Representation
- Commercial Terms and Pricing
- Insurance and Reimbursement

Patient Anatomy and Device Characteristics

Is it available in the needed size(s) to treat the patient anatomy? "Available" implies local regulatory approval and local supply: more on this in the next section.

Are there nuances with the patient anatomy requiring a uniquely shaped or otherwise configured device? Is the device standard issue or is customization required? Note: Custom devices are not available in many countries. Check with the manufacturer and/or local regulatory authorities if you have questions.

Are there restrictions in sheath size due to patient age/weight and/or other conditions, which may limit the available device selection? This is a common issue in the pediatric population.

Device Regulatory Approvals

Perhaps most important to the question of device availability is its approval (i.e., CE Mark) and indication for use. A product having such approval implies that the device is proven to be safe and effective for use in the stated indication.

In addition to local/regional regulatory approval, it may also require registration in the country of intended use. For example, some countries allow the CE Mark for approval, while others may require additional documents such as Country of Origin, local listing/registration, etc.

Exceptions to regulatory approvals may include devices studied under strict clinical protocol. Naturally, implanted devices have much more stringent clinical and patient monitoring follow-up requirements than non-implants.

Physician Experience with the Device in Question

In addition to the implanting physician's own experience, an important part of the decision is if the device is or seems "user-friendly" such that it is relatively easy to use and thus gives the physician added confidence during the procedure.

A key tradeoff in the selection process could be: might simpler devices reduce the chance of complications and improve clinical results? Or, do extra device features have benefits that outweigh the simplicity factor?

Certainly the manufacturers all provide at least some rationale for their respective product features and benefits. Which features are important and which are trivial?

Is additional physician proctoring, or other outside product-related assistance desired? Finally, is on-site, surgical back up required for this device and procedure?

Clinical Evidence

Which device is the "gold standard" for the procedure? While not necessarily the best option, it may give the implanting physician at least some comfort that it has withstood the test of time. Are there clinical studies to back this up? If not, post-market data or individual case studies may help justify your choice. Referring and/or consulting physicians will also have their opinions. These can be especially important when a device is new to the market and/or has limited clinical publications.

Manufacturer/Supplier/Sales Representation

Is the company known for its quality manufacturing? What has been the experience with the local agent or distributor company supplying the devices? Is there a degree of trust with the supplier and organization?

One component that may be important is if the manufacturer and/or distributor warrant and/or replace devices if their product is mis-

sized during the procedure, or only if the product is out of specification?

What claims does the company make about the product? What claims are valid and what may be referred to as "market hype"?

Commercial Terms and Pricing

Are the devices available via consignment to the hospital, or will the hospital place stocking orders? This may depend upon the local sales representation; i.e., if the devices are supplied directly by the manufacturer or from a local distributor. Practices and policies differ by manufacturer and often by country.

Insurance and Reimbursement

Will the product cost be covered solely by the patient, reimbursed via private insurance, or by a governmental reimbursement policy? This answer often drives the patient decision, particularly if the device(s) in question are seen as commodities or otherwise are in a highly price-sensitive medical economy.

Conclusions

In short, the decision making process to use a particular medical device is rarely an easy task. However, if the implanting physician, hospital providers, and the patient's family factor the items listed above into the process, then the product selection decision has been comprehensive.

CCT

Mark Cibuzar
Independent Medical Device Consultant
Minneapolis, MN USA

markcibuzar@gmail.com

Preview of the International Cardiology Neonatology Symposium to be held October 8th-10th, 2015 at the InterContinental Hotel – Miami, Florida, USA

By Mitchell Cohen, MD; Alan Spitzer, MD

October in Miami is perfect! This coming October, neonatologists and cardiologists will gather for a three-day innovative, collaborative scientific meeting, *International Cardiology Neonatology Symposium*. As neonatal care becomes increasingly complex, optimal outcomes will be obtained as neonatologists and cardiologists depart from traditional silos and work together as a team. This conference pairs over 30 internationally-recognized leaders in the field of Pediatric Cardiology and Neonatology along with pediatric cardiothoracic surgeons, anesthesiologists, pediatric cardiac intensivists, and bedside and clinical nurses to discuss and debate the challenges and dilemmas that face the neonate with Congenital Heart Disease (CHD). This conference is designed to present the most up-to-date clinically relevant information on topics related to the diagnosis, management and outcomes of neonates with cardiovascular disease. We will present the daily challenges faced in the management of neonates with congenital heart disease, an isolated patient ductus arteriosus, pulmonary hypertension and arrhythmias. We will also explore the secondary effects of cardiovascular disease on the neonatal lung, brain and kidney. It is the focus of the organizing committee and all the speakers to provide valuable information for all of our attendees to take back to their respective neonatal and cardiac intensive care units. The meeting begins with a fantastic optional pre-conference, followed by 12 plenary sessions over the three days. The meeting departs from smaller breakout sessions so that all attendees can be part of the entire larger symposium. There are numerous discussion periods so that the audience can ask pertinent and relevant questions. By having physicians, advanced nurse practitioners and clinical bedside nurses all within the same plenary sessions, the content, interaction and discussion will be relevant for the entire team caring for babies with congenial heart disease.

"As neonatal care becomes increasingly complex, optimal outcomes will be obtained as neonatologists and cardiologists depart from traditional silos and work together as a team."

The optional pre-conference, surely not to be missed, begins Thursday morning with a primer dedicated to Critical Congenital Heart Disease in the neonate. Dr. Paul Weinberg, Children's Hospital of Philadelphia, is one of the preeminent cardiac anatomists in the world and will be showing anatomic specimens with D-transposition of the great arteries, total anomalous pulmonary venous return, Hypoplastic Left Heart Syndrome, Ebstein's anomaly, pulmonary atresia with intact septum as well as with Tetralogy of Fallot. After each specimen is reviewed, a cardiologist will review the pertinent echocardiographic findings and discuss the pathophysiology of the lesion and what to expect in the NICU or CVICU. The specimen session will conclude with a cardiothoracic surgeon reviewing the surgical approach and, in some cases, intra-operative videos will be used. By the end of the pre-conference the attendee should have an excellent refresher in the anatomy, pathophysiology, and medical and surgical approaches to over 10 congenital heart substrates.

The main conference starts Thursday afternoon, October 8th, 2015 and runs through Saturday evening, October 10th. *The Cardiology Neonatology Symposium* is arranged thematically around either a specific organ system related to CHD or to the concepts of infrastructure and team building. The

opening plenary session features key lectures by some of the best-known cardiologists in the country. Dr. Gil Wernovsky, Director of Family-Centered Care at Miami Children's Hospital, will introduce the concepts of refining neonatal CHD along a paradigm of teamwork. Dr. Jack Rychik, Director of the Cardiac Fetal Program at The Children's Hospital of Philadelphia, will bridge the gap between fetus and neonate, and discuss ways to categorize CHD based upon complexity and expected postnatal course. The plenary will continue with discussions from neonatology, cardiology, surgery and nursing on managing the neonate with CHD and what each discipline brings to the team and how to continue to strive to be better. The plenary ends with a remarkable guest speaker, Tiffany Christensen, a patient advocate at Duke University, author of "Sick Girl Speaks," and who is the recipient of two lung transplants for cystic fibrosis (CF). Ms. Christensen will discuss CF as a chronic condition, much akin to CHD, and the decisions parents make for their children and how those decisions can impact their lives. This opening session promises to be an extraordinary and special one that will set the tone for the meeting and should not be missed.

The second day, October 9th, begins with a review of the Patent Ductus Arteriosus (PDA). While the PDA in the neonate seems so simple, it continues to generate discussion and controversy about how to best approach this remnant of the distal portion of the left 6th embryonic aortic arch. This session will feature two excellent debates. The first debate will feature two well-known neonatologists: Ron Clyman, MD, UCSF, and Alan Groves, MD, New York-Presbyterian Hospital. These physicians will discuss closure of the PDA in the preterm infant. As echocardiography becomes more universal, discussion has arisen regarding neonatologists performing echocardiograms after an initial study ruled-out CHD. We will have two world-renowned echocardiographers, Dr. Meryl Cohen, Children's Hospital of Philadelphia, and Dr. Leo Lopez, Miami Children's Hospital, debate this question.

The third plenary will review issues of brain development and maturation in neonates with CHD. Over the last 15 years, much has been learned about associative cerebral structural abnormalities in neonates with CHD as well as pre-operative and post-operative strategies to improve neurologic outcomes. Many heart centers have developed proactive neurodevelopmental clinics to track and follow children following complex neonatal heart surgery. This session will look back at the accomplishments of the last 15 years, but also focus on the challenges and dilemmas moving forward. Recently, there has been a tremendous focus on growing the fetal brain and new information will be presented at this meeting regarding this particular strategy. This session features three preeminent cardiologists, a cardiac neurologist, surgeon and cardiac intensivist. Given the tremendous interest in this particular topic we have a lengthy discussion period built in to encourage audience participation.

The afternoon fourth plenary will probe the issues surrounding feeding neonates with CHD and how to manage caloric needs in the setting of ductal dependent systemic circulation. How should feeds be introduced and maintained? What should the neonatal nurse be monitoring during feeds? When is it time to stop the feeds and move to surgery? This will undoubtedly be a hot topic for all attendees and will likely generate many questions during the panel discussion. Friday afternoon will continue with a plenary dedicated to neonates with arrhythmias with interactive rhythm strips and electrocardiograms. This is a must for the neonatologist, nurse practitioner and bedside nurse.

The last decade has seen a major shift in the number of neonatal interventional cardiac procedures that previously could only be done with a sternotomy or thoracotomy. We will review the current state-of-the-art of interventional catheterization in the neonate with CHD, as well as probe the issue of when to refer to the cath lab and what to watch for when returning from the cath lab to the NICU or CICU. Friday evening will conclude with a session on the kidney and congenital heart disease. We will review the current understanding of neonatal GFR maturation in the first month of life and balance the needs of the neonate against the risk of fluid overload in some forms of complex CHD. Dr. Michael Zappitelli, MD. MSc, Director of the Dialysis and Aphaeresis Program at Montreal Children's Hospital, is a world expert in acute kidney injury and will review how we best identify AKI and manage it once it is identified.

Saturday morning, October 10th, the meeting will resume with a plenary on resuscitation, ECMO and neonatal CHD. The speakers will review issues

"The last decade has seen a major shift in the number of neonatal interventional cardiac procedures that previously could only be done with a sternotomy or thoracotomy. We will review the current state-of-the-art of interventional catheterization in the neonate with CHD, as well as probe the issue of when to refer to the cath lab and what to watch for when returning from the cath lab to the NICU or CICU."

on preparing for a cardiac arrest, use of VV ECMO in CHD, ECPR in the NICU, and where the future of mechanical circulatory support in the neonate with heart disease is headed. The ninth plenary will open with a discussion on the issues of family support as well as a frank discussion about the advantages and disadvantages of social media. Amy Basken, President of the Pediatric Congenital Heart Association, will discuss family support from the parent's perspective; this will be followed by a remarkable talk by Kathy Mussatto, RN, PhD, on the view of family support from a nurse's vantage.

The noon lecture promises to be one of the highlights of the meeting. Dr. Andrew Redington, Executive Co-Director, Heart Institute; Professor and Chief of Pediatric Cardiology at Cincinnati Children's Hospital will give the first Annual Roger Medel Lecture, titled, "Understanding Myocardial Function and Failure in the Neonate." Dr. Redington is one of the most remarkable speakers who captivates an audience and, no doubt, this will prove to be an insightful talk.

The organizing committee encourages all attending physicians, neonatologists, cardiologists, advanced practice nurses, clinical nurses, and neonatal and cardiology fellows to submit an abstract. The abstracts should be relevant to the field of neonatal cardiology and the top five abstracts chosen by the scientific organizing committee will be presented in an oral fashion at the main plenary. The abstracts will be presented in poster fashion at multiple times throughout the meeting and will allow the presenter to meet with neonatologists, cardiologists and nurses to discuss their research. This is a great opportunity for young investigators to have one-on-one dialogue with clinicians from around the world.

The tenth plenary will focus on the premature infant with CHD. In every NICU these are the most troubling and difficult patients to manage. Dr. Ganaga Krishnaumurthy, a leading neonatologist from Presbyterian-New York Hospital, will discuss low birth weight neonates with CHD and present outcomes data. While discussions will focus on the best place to care for such a complex neonate, the better question may be how we, as a team, should care for our most difficult patients, location aside. The eleventh plenary will be a didactic review on understanding BPD, pulmonary hypertension and PVR. What can the neonatologist learn from the cardiologist and what can the cardiologist learn from the neonatologist? The meeting will conclude Saturday evening with a look to future. What will be the future state of imaging babies with CHD? Will MRI replace the echocardiogram in certain diagnosis? Dr. Groves will also review how a neonatologist can better use the ECHO to assess circulatory function. Much information is available on the echocardiogram. Is all that information being shared and how as a team do we take the bedside information and put it together with the echocardiogram so as to best care for the baby? We promise you a remarkable journey through neonatal cardiology. Of course there will also be great food at the meeting and the Miami atmosphere is second to none.

"The organizing committee encourages all attending physicians, neonatologists, cardiologists, advanced practice nurses, clinical nurses, and neonatal and cardiology fellows to submit an abstract. The abstracts should be relevant to the field of neonatal cardiology and the top five abstracts chosen by the scientific organizing committee will be chosen and presented in an oral fashion at the main plenary."

The meeting promises to be as good as the views from the InterContinental Hotel looking out at Biscayne Bay, the giant cruise ships and South Beach a few miles away. The InterContinental Hotel is located in the heart of downtown Miami with excellent restaurants, shopping, night-life and a short ride to South Beach. If you choose to stay at the hotel there is an excellent mySpa with 10 treatment rooms and a fitness center on site. We look forward to seeing you at the first *International Cardiology Neonatology Symposium.*

For more information, go to: www.neocardisymposium.com.

CCT

Corresponding Author

Mitchell Cohen, MD, FACC, FHRS
Co-Director Heart Center
Chief, Pediatric Cardiology
Phoenix Children's Hospital
1919 East Thomas Rd.
Phoenix, AZ 85016 USA

Clinical Associate Professor of Pediatrics,
University of Arizona School of Medicine
Director of Cardiac Research
MEDNAX Services, Inc.
mitchcohenmd@gmail.com

Alan R. Spitzer, MD
Senior Vice President for Research, Education, and Quality
MEDNAX Services/Pediatrix Medical Group/American Anesthesiology
1301 Concord Terrace
Sunrise, FL 33323 USA

Medical News, Products & Information

Compiled and Reviewed by Tony Carlson, Senior Editor

Study in Animal Model Paving Way Forward for Tissue Repair

Newswise - The heart tissue of mammals has limited capacity to regenerate after an injury such as a heart attack, in part due to the inability to reactivate a cardiac muscle cell and proliferation program. Recent studies have indicated a low level of cardiac muscle cell (cardiomyocytes) proliferation in adult mammals, but it is insufficient to repair damaged hearts.

A team led by Ed Morrisey, PhD, a Professor of Medicine and Cell and Developmental Biology and the Scientific Director of the Institute for Regenerative Medicine in the Perelman School of Medicine at the University of Pennsylvania, has now shown that a subset of RNA molecules, called microRNAs, is important for cardiomyocyte cell proliferation during development and is sufficient to induce proliferation in cardiomyocytes in the adult heart. MicroRNAs, which do not generate proteins, repress gene expression by binding messenger RNAs, which do generate proteins, and promote their degradation. The findings appeared the March 17th issue in *Science Translational Medicine.*

The team found that the loss of the microRNA cluster miR302-367 in mice led to decreased cardiomyocyte cell proliferation during development. In contrast, increased expression of the microRNA cluster in adult hearts led to a reactivation of proliferation in the normally non-reproducing adult cardiomyocytes.

This reactivation occurred, in part, through repression of a pathway called Hippo that governs cell proliferation and organ size. "The Hippo pathway normally represses cell proliferation when it is turned on. The cluster miR302-367 targets three of the major kinase components in the Hippo pathway, reducing pathway activity, which allows cardiomyocytes to re-enter the cell cycle and begin to regrow heart muscle," explains Morrisey. "This is a case of repressing a repressor."

In adult mice, re-expression of the microRNA cluster reactivated the cell cycle in cardiomyocytes, resulting in reduced scar formation after an experimental myocardial infarction injury was induced in the mice. There was also an increase in the number of heart muscle cells in these same mice.

However, long-term expression of more than several months of the microRNA cluster caused heart muscle cells to dedifferentiation and become less functional. "This suggested to us that persistent reactivation of the cell cycle in adult cardiomyocytes could be harmful and causes the heart to fail," says Morrisey. The investigators surmised that cardiomyocytes likely need to de-differentiate to divide, but they may lose their ability to contract over time.

"We overcame this limitation by injecting synthetic microRNAs with a short half-life called mimics into the mice," says Morrisey. Mimic treatment for seven days after cardiac infarction led to the desired increase in cardiomyocyte proliferation and regrowth of new heart muscle, which resulted in decreased fibrosis and improved heart function after injury.

Importantly, the team found that the transient seven-day treatment did not lead to the progressive loss of cardiac function as seen in the genetic models of increased microRNA expression. Overall, these results suggested that any treatment

that promotes cardiomyocyte proliferation to improve cardiac regeneration will likely need to be transient to avoid the deleterious effects of maintaining a high level of proliferation and de-differentiation in a tissue that is normally non-proliferative.

"The next stage in this study is to determine whether miRNA mimics will work in a larger animal model and to collaborate with bioengineers to create a local delivery system for the heart, rather than giving it systemically," notes Morrisey.

Coauthors are: Ying Tian (previously a postdoctoral fellow in the Morrisey Lab who is now an assistant professor at Temple University), Ying Liu, Tao Wang, Ning Zhou, Jun Kong, Li Chen, Melinda Snitow, Michael Morley, Deqiang Li, Nataliya Petrenko, Su Zhou, Minmin Lu, and Kathleen M. Stewart, all from Penn. Erhe Gao and Walter J. Koch are from Temple University.

This study was funded by grants from National Heart, Lung, and Blood Institute (R01-HL064632, R01-HL087825, U01-HL100405, K99/R00, and K99/R00-HL111348).

Studies Find Increase in Use of Bystander Interventions for Out-of-Hospital Cardiac Arrest; Associated With Improved Outcomes

Two studies in the July 21st issue of *JAMA* find that use of interventions such as cardiopulmonary resuscitation and automated external defibrillators by bystanders and first responders have increased and were associated with improved survival and neurological outcomes for persons who experienced an out-of-hospital cardiac arrest.

Out-of-hospital cardiac arrest (OHCA) is an increasing health concern worldwide, with poor prognoses. Shinji Nakahara, MD, PhD, of the Kanagawa University of Human Services, Yokosuka, Japan, and colleagues examined the associations between bystander interventions and changes in neurologically-intact survival among patients with OHCA in Japan. The researchers used data from Japan's nationwide OHCA registry, which started in January 2005. The registry includes all patients with OHCA transported to the hospital by emergency medical services (EMS) and recorded patients' characteristics, prehospital interventions (including defibrillation using public-access automated external defibrillators [AEDs] and chest compression) and outcomes.

The study included 167,912 patients with bystander-witnessed OHCA between January 2005 and December 2012. The researchers found that during this time period, the number of these events increased and the rate of bystander chest compression, bystander-only defibrillation, and bystander defibrillation combined with EMS defibrillation also increased. In addition, likelihood of neurologically-intact survival improved (age-adjusted proportion, 3.3% to 8.2%), but remained quite low. The increase in neurologically intact survival was associated with bystander defibrillation and chest compressions.

The authors write that further increases in use of chest compression by bystanders should be promoted. "In Japan it is

used in just 50% of patients and is increasing slowly. Simplifying the basic life support procedure by omitting mouth-to-mouth breathing may have reduced hesitancy and increased its use. Facilitating chest compression has an economic advantage over deployment of expensive public-access AEDs. Fire departments provide training to more than 1,400,000 citizens every year to increase the prevalence of skills in basic resuscitation procedures, including chest compression and AED use. This effort should be further strengthened."

Carolina Malta Hansen, MD, of the Duke Clinical Research Institute, Durham, NC, and colleagues examined the outcomes and changes in bystander and first-responder resuscitation efforts for cardiac arrest patients before arrival of the EMS following statewide initiatives to improve these efforts in North Carolina.

Out-of-hospital cardiac arrest is a major public health issue, associated with low survival and accounting for approximately 200,000 deaths per year in the United States. Early cardiopulmonary resuscitation (CPR) and defibrillation can improve outcomes if more widely adopted, according to background information in the article.

This study included 4,961 patients with out-of-hospital cardiac arrest for whom resuscitation was attempted and who were identified through the Cardiac Arrest Registry to Enhance Survival (2010-2013). First responders included police officers, firefighters, rescue squad, or life-saving crew trained to perform basic life support until arrival of the EMS. Statewide initiatives to improve bystander and first-responder interventions included training members of the general population in CPR and in use of AEDs, training first responders in team-based CPR including AED use and high-performance CPR, and training dispatch centers in recognition of cardiac arrest.

The combination of bystander CPR and first-responder defibrillation increased from 14% (51 of 362) in 2010 to 23% (104 of 451) in 2013. Survival with favorable neurological outcome increased from 7 percent in 2010 to 10% in 2013 and was associated with bystander-initiated CPR. Bystander and first-responder interventions were associated with higher survival to hospital discharge. Survival following EMS-initiated CPR and defibrillation was 15% compared with 34% following bystander-initiated CPR and defibrillation; 24% following bystander CPR and first-responder defibrillation; and 25% following first-responder CPR and defibrillation

"Our study presents novel findings indicating that improvements in bystander and first-responder CPR and defibrillation are both associated with increased survival," the authors write. "Our findings suggest the possibility of improving outcomes by strengthening first-responder programs, in addition to increasing the number of bystanders who could then provide CPR, including those assisted by emergency dispatchers, and by improving EMS systems. This is particularly important for cardiac arrests that occur in residential areas and in areas with a long EMS response time, where public access defibrillation programs are unlikely to be implemented."

This study was supported by the HeartRescue Project, which is funded by the Medtronic Foundation. Please see the article for additional information, including other authors, author contributions and affiliations, financial disclosures, etc.

Thermometer-Like Device Could Help Diagnose Heart Attacks

Diagnosing a heart attack can require multiple tests using expensive equipment. But not everyone has access to such techniques, especially in remote or low-income areas. Now scientists have developed a simple, thermometer-like device that could help doctors diagnose heart attacks with minimal materials and cost. The report on their approach appeared in the *ACS journal Analytical Chemistry.*

Sangmin Jeon and colleagues note that one way to tell whether someone has had a heart attack involves measuring the level of a protein called troponin in the person's blood. The protein's concentration rises when blood is cut off from the heart, and the muscle is damaged. Today, detecting troponin requires bulky, expensive instruments and is often not practical for point-of-care use or in low-income areas. Yet three-quarters of the deaths related to cardiovascular disease occur in low- and middle-income countries. Early diagnosis could help curb these numbers, so Jeon's team set out to make a sensitive, more accessible test.

Inspired by the simplicity of alcohol and mercury thermometers, the researchers created a similarly straightforward way to detect troponin. It involves a few easy steps, a glass vial, specialized nanoparticles, a drop of ink and a skinny tube. When human serum with troponin -- even at a minute concentration -- is mixed with the nanoparticles and put in the vial, the ink climbs up a protruding tube and can be read with the naked eye, just like a thermometer.

The authors acknowledge funding from the National Research Foundation of Korea.

Hearts with Hope's Mission to Arequipa Peru

Hearts with Hope will be going on a mission to Arequipa Peru for the 9th year. We will be performing complex congenital heart surgery, interventional cardiac catheterizations and diagnostic procedures including echocardiography. The mission will take place from September 29th to October 11th.

They are currently looking for:

- ICU Nurse(s)
- Pediatric cardiologist with interest in echo
- Pediatric cardiology fellow

Mission contribution will be required. Spots are few and they will accept those who confirm first. Please email: jalejos@heartswithhope.org with questions or interest.

Hybrid Tissue-Engineered Valves May Expand Options for Heart Valve Surgery Patient - ***Novel technology creates patient-specific valve that won't degrade over time***

Newswise — Chicago – Researchers have created a new heart valve that combines a patient's own cells with metal alloy for a more durable replacement with potentially fewer complications, according to an article in the June 2015 issue of *The Annals of Thoracic Surgery.*

S. Hamed Alavi, PhD, and Arash Kheradvar, MD, PhD, from the University of California in Irvine, developed the potentially revolutionary hybrid tissue-engineered heart valve.

Current valve replacement options are limited to those made solely from manufactured products (mechanical valves) or animal tissue (bioprosthetic valves). Mechanical heart valves tend to last longer than bioprosthetic valves, but they carry a greater long-term risk for blood clots that may lead to stroke and arterial thrombosis (clotting in the arteries), as well as bleeding from anticoagulant medications designed to prevent thrombosis.

"Bioprosthetic valve replacements, on the other hand, are prone to limited durability, which means patients may need a reoperation usually 10 to 15 years after implantation," said Dr. Alavi.

Traditionally, tissue-engineered valves are built on a scaffold that will degrade once the tissue is more mature. Once the scaffold has degraded, however, the valve leaflets often shrink, which can cause leaks and result in valve failure.

"For our research, we decided to use a non-degradable scaffold that stays within the valve to provide the support it needs without interfering with its normal function," said Prof. Kheradvar. "The valve we created uses an ultra-flexible scaffold made of an alloy of nickel and titanium (Nitinol) that is enclosed within the patient's own cultured tissue. The entire process takes about 3 to 8 weeks."

The researchers said that they expect the hybrid valve to self-regenerate inside the body, eventually incorporating itself into the patient's heart structure. By using the patient's own cells, the valve will become a "living" replacement for the diseased valve.

"We believe this new hybrid technology will significantly improve a patient's quality of life by eliminating the need for lifelong medications and without compromising the durability of the valve," said Dr. Alavi. "This is particularly beneficial for younger

patients who are in need of a heart valve replacement."

The researchers have completed initial lab testing and now plan to initiate the next phase of trials. If all goes well, they anticipate the hybrid heart valve will be available for use in patients in 5 to 10 years.

Link to the artcle, "A Hybrid Tissue-Engineered Heart Valve" - www.annalsthoracicsurgery.org/article/S0003-4975(15)00271-4/abstract

Letters to the Editor

Congenital Cardiology Today welcomes and encourages Letters to the Editor. If you have comments or topics you would like to address, please send an email to: LTE@CCT.bz, and let us know if you would like your comment published or not.

MEDICAL MEETING FOCUS

2nd Annual Basic & Advanced Fetal Cardiac Symposium and Workshop
Sep. 10-12, 2015; Chicago, IL
www.FetalCardiacSymposium.com

This symposium will discuss various concepts and common CHD malformations encountered in the fetus, with emphasis on imaging and practical tips for diagnosis. In particular, it will include sessions focusing on the following areas:

- Fetal Cardiovascular Physiology and Pathophysiology
- Latest Guidelines in Prenatal Screening and Red Flags in the Diagnosis of Fetal CHD
- Live Demonstration on Performing a Fetal Echocardiogram
- Practical Tips in the Diagnosis of Commonly Encountered Cardiac Defects
- Evaluation of Fetuses with Borderline Cardiac Findings
- Diagnosis and Management of Fetal Arrhythmia
- Updates on Fetal Genetic Evaluation

The symposium will provide the audience with the unique experience of hands-on and live demonstration sessions, as well as opportunities for the audience to discuss interesting cases and interact with experts in the field. Registrants will have the chance to submit interesting cases to be presented during the course of the symposium.

Hands-on Scanning Workshop: There will be two separate sessions focusing on scanning the fetal heart under the supervision of experienced faculty and using various up-to-date machines.

Participants become familiar with: Identifying Situs; Obtain the 4-chamber View; Demonstrate Pulmonary Venous Flow; Obtain the Right and Left Ventricular Arterial Outflow Tracts View; Obtain the 3-vessel View; Obtain the Arch Views.

Sponsored for CME credit by Rush University Medical Center which designates this live activity for a maximum of 19.25 AMA PRA Category 1 Credit(s)™ & 19.25 Continuing Nursing Education credit(s). This activity is also approved by the Society for Diagnostic Medical Sonography (SDMS), and is eligible for up to 19.25 SDMS credits.

Course Director: Karim A. Diab, MD

Invited and Local Faculty: Ra-id Abdulla, MD; Alfred Abuhamad, MD; Emerio T. Alboliras, MD; Sawsan M. Awad, MD, MSC; John Bokowski, PhD, RDCS, FASE; Massimo Caputo, MD, Mch, FRCS; Lisa Hornberger, MD; Edgar Jaeggi, MD; Carolyn Jones, MD, PhD; Michelle Rexilius, RDCS; Mark Sklansky, MD; Wayne Tworetzky, MD; Xavier Pombar, DO; Luciana T. Young, MD

CONGENITAL CARDIOLOGY TODAY

www.CongenitalCardiologyToday.com

8100 Leaward Way, PO Box 444, Manzanita, OR 97130 USA
Tel: +1.301.279.2005; Fax: +1.240.465.0692