

# CONGENITAL CARDIOLOGY TODAY

Timely News and Information for BC/BE Congenital/Structural Cardiologists and Surgeons

Volume 6 / Issue 8  
August 2008  
International Edition

## IN THIS ISSUE

### Intra-operative Balloon Angioplasty for Branch Pulmonary Artery Stenosis

by Masataka Kitano, MD; Satoshi Yazaki, MD; Koji Kagisaki, MD; Ikuo Hagino, MD; Kenichi Kurosaki, MD; Toshikatsu Yagihara, MD; and Osamu Yamada, MD  
~Page 1

### Highlights from the 2008 Scientific Sessions of the American Society of Echocardiography (ASE)

by Judy Mangion, MD, FASE,  
FACC, FAHAMM  
~Page 8

### DVD Textbook Review:

#### "Congenital Heart Disease Cardiac Morphology & Echocardiography A Multimedia Presentation"

- Authors: Dr. Siew Yen Ho  
BSc, PhD, FRCPath, FESC, and  
Dr. William Chin Ling Yip  
MBBS, M Med, MD, FRCP, DCH,  
FAMS(ASE)

by John W. Moore, MD, MPH  
~Page 12

## DEPARTMENTS

### Medical News, Products and Information

~ Page 10

## CONGENITAL CARDIOLOGY TODAY

Editorial and Subscription Offices  
16 Cove Rd, Ste. 200  
Westerly, RI 02891 USA  
[www.CongenitalCardiologyToday.com](http://www.CongenitalCardiologyToday.com)

© 2008 by Congenital Cardiology  
Today ISSN: 1544-7787 (print);  
1544-0499 (online). Published  
monthly. All rights reserved.

Statements or opinions expressed in  
Congenital Cardiology Today reflect  
the views of the authors and spon-  
sors, and are not necessarily the  
views of Congenital Cardiology Today.

## Intra-operative Balloon Angioplasty for Branch Pulmonary Artery Stenosis

By Masataka Kitano, MD; Satoshi Yazaki,  
MD; Koji Kagisaki, MD; Ikuo Hagino, MD;  
Kenichi Kurosaki, MD; Toshikatsu  
Yagihara, MD; and Osamu Yamada, MD

### Background

After pulmonary artery banding (PAB), a shift of the band to the distal position can result in right pulmonary artery stenosis (RPS) with low blood flow and in left pulmonary hypertension (LPH) with high blood flow, except isomeric pulmonary arteries (Figure 1). Some intervention should be performed to improve the imbalance between the right and left pulmonary blood flows because this condition is not favorable especially to Fontan candidates.

For RPS with or without LPH due to band dislocation, we performed intra-operative right pulmonary artery (RPA)-plasty using balloon catheters and re-PAB without cardiopulmonary support (CPS) in young infants. Although we judged these stenotic parts to be fully enlarged from their outward appearances immediately after balloon angioplasty, it is not clear that the effect of this procedure continues for a long time: The enlarged parts may get stenotic again a few weeks later because of pulmonary arterial compliance. Therefore, we reviewed the outcome of this procedure and reconsidered the way to perform it.

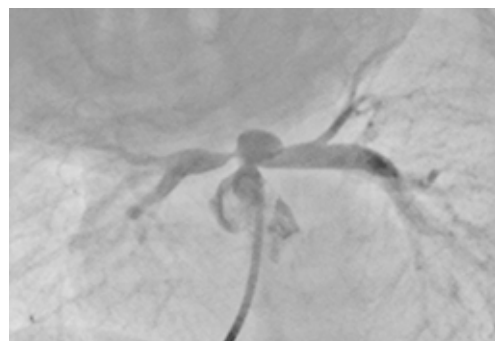
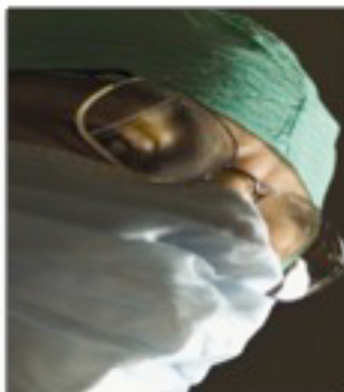
Figure 1. Pulmonary arteriogram in an infant with DIRV and DORV after arch reconstruction and PAB for CoA. The band dislocation to the distal position resulted in right pulmonary artery stenosis with low blood flow and in left pulmonary hypertension with high blood flow.

DIRV, double inlet right ventricle; DORV, double outlet right ventricle; PAB, pulmonary artery banding; CoA, coarctation of the aorta.

### Methods

Between October 2004 and November 2005, Intra-operative balloon RPA-plasty and re-PAB without CPS was performed in five infants with univentricular physiology who got RPS with or without LPH after arch reconstruction and PAB. The patients in age and weight ranged from 1 to 4 months (me-



## RECRUITMENT ADVERTISING IN CONGENITAL CARDIOLOGY TODAY

- Pediatric Cardiologists
- Congenital/Structural Cardiologists
- Interventionalists
- Echocardiographers
- Imaging Specialists
- Electrophysiologists
- Congenital/Structural Heart Failure Specialists
- Cardiac Intensivists

Contact: Tony Carlson [tcarlsonmd@gmail.com](mailto:tcarlsonmd@gmail.com)

# WATCH LIVE CASES ON THE WEB

Hosted by Congenital Cardiology Today  
[www.Live-Cases.com](http://www.Live-Cases.com)

Watch Live Cases from Milan, Italy; Columbus, OH, USA; Toronto, Canada,  
performed by experts in the field:

**Perventricular Muscular VSD** - Drs. Emile Bacha, Ziyad M. Hijazi and Daniel Rowland,

**Perventricular Membranous VSD** - Drs. Hakan Akintuerk, Zahid Amin and Qi-Ling Cao

**Hybrid Stage I Palliation for HLHS PA Bands and PDA Stent** - Drs. Mark Galantowicz and John P. Cheatham

**Intraoperative Aortic Stent for CoA** - Drs. Redmond Burke and Evan Zhan

**Intraoperative LPA Stent Using Endoscopic Guidance** - Drs. Alistair Phillips, Ralf J. Holzer, and Vincent Olshove, CCP

**Creation of ASD after PA Bands & PDA Stent for HLHS in a Premie** - Dr. John P. Cheatham, Sharon L. Hill, ACNP

**Perventricular Implant of Edwards Valve Stent in the Pulmonary Position** - Drs. Ziyad M. Hijazi and Jinfen Lin

**Closure of Septal Defect Using Real Time 3D Echo Guidance** - Drs. Nikolay V. Vasilyev and Qi-Ling Cao

**High Frequency Ultrasound Creation of ASD** - Drs. Nikolay V. Vasilyev and Qi-Ling Cao

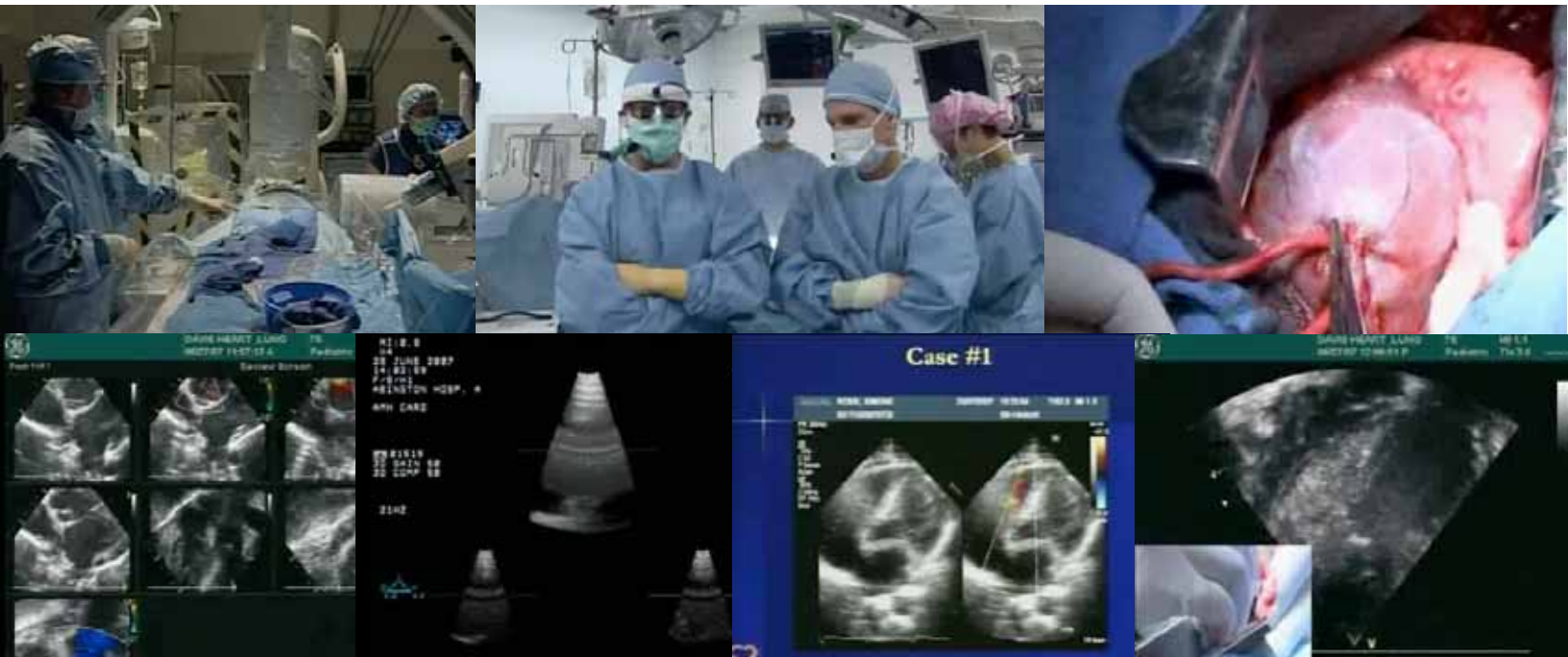**PmVSD Closure** - Dr. Mario Carminati

**Transcatheter Implantation of Implantable Melody Valve** - Dr. John Cheatham

**Percutaneous Closure of ASD(s) with TEE or ICE Guidance - Percutaneous Valve Implantation** - Drs. Eric Horlick  
and Lee Benson

**Perimembranous VSD Closure with Amplatzer Membranous VSD Occluder** - Drs. M. Carminati, J. Bass, G.F. Butera,  
D. Hagler and M. Carrozza

*New live cases will be added in the following months.*



If you would like to be notified when additional live cases have been added, please send an email to: [LiveCases@CHDVideo.com](mailto:LiveCases@CHDVideo.com).  
For more information on the symposiums that produced these live cases, and how to attend, please visit:

- **ISHAC** (International Symposium on the Hybrid Approach to Congenital Heart Disease) [www.hybridsymposium.com](http://www.hybridsymposium.com)
- **PICS-AICS** (Pediatric and Adult Interventional Cardiac Symposium) [www.picsymposium.com](http://www.picsymposium.com)
- **International Workshop IPC** (International Workshop on Interventional Pediatric Cardiology) [www.workshopipc.com](http://www.workshopipc.com)

[www.Live-Cases.com](http://www.Live-Cases.com)

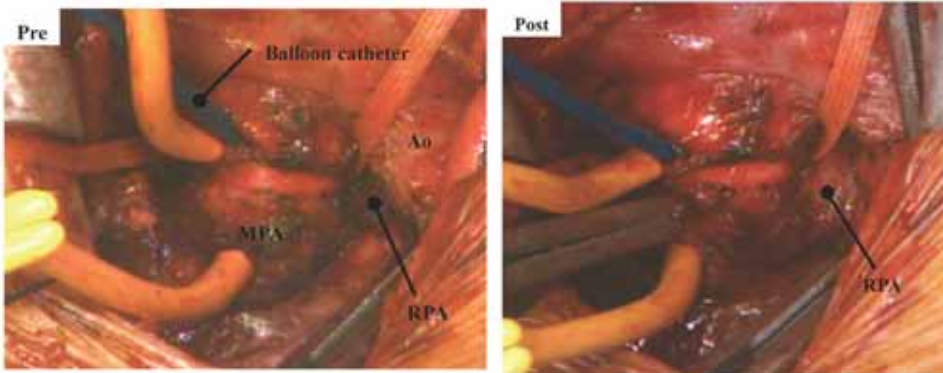


Figure 2. Intra-operative photographs before (the upper panel) and after (the lower panel) balloon RPA-plasty in a patient with CoA, TGA, VSD and RV hypoplasia after arch reconstruction and PAB who was accompanied with RPS due to MPA band dislocation.

A balloon catheter is advanced into the stenotic part of the RPA through the purse-string-suture site on the anterior wall of the MPA. The RPA is fully dilated after balloon dilation (the lower panel). There is little bleeding to disturb the sight during the procedure. Ao, aorta; MPA, main pulmonary artery; RPA, right pulmonary artery; CoA, coarctation of the aorta; TGA, transposition of the great arteries; RV, right ventricle; PAB, pulmonary artery banding; RPS, right pulmonary artery stenosis.

dian, 2 months) and from 2.3 to 5.5 kg (median, 3.0 kg), respectively (Table 1).

The details of the surgical procedure are as follows: After median sternotomy, the adhesion around the pulmonary artery bifurcation was dissected and the previous

band was removed. While surgeons made a purse string suture on the anterior wall of the main pulmonary artery proximal to the dislocated banding line, a pediatric cardiologist prepared a balloon catheter whose middle was bent by setting a tip-bent stiff wire into the catheter lumen to fit the balloon onto the stenotic part of the RPA. The bent balloon catheter was advanced into the stenotic part through the purse string suture site. Then the balloon was inflated at 14 atm a few times until the stenotic part was fully dilated from its appearance (Figure 2). After pulling the catheter out and ligating the insertion site, re-PAB was performed in appropriate position. The balloon diameters (BDs) used ranged from 4.0 to 9.0 mm for the minimum lumen diameters (MLDs) ranging from 0.8 to 2.7 mm on angiograms (Table).

In the five patients, we collected the following data before and 1 month after the procedure: the MLDs and the reference vessel diameters (RVDs) by angiography; the left pulmonary artery (LPA) pressures by cardiac catheterization; and the right/left ratios by lung perfusion scintigraphy, which was employed in only three patients. Then we evaluated the changes in this data and

Table 1: Patient's Profile

No.	Age	Weight	Diagnosis	MLD	BD	BD/MLD	BD/RVD	The Period
	[month(s)]	[kg]		[mm]	[mm]			[days]
1	1	3.0	CoA, DIRV, DORV	1.0	6.0	6.0	1.4	21
2	1	3.3	IAA, AVSD, LV hypo	0.8	4.0	5.0	1.2	46
3	2	3.7	CoA, DORV, VSD, LV hypo	0.9	4.0	6.0	1.7	83
4	4	2.5	CoA, AVSD, LV hypo	2.7	8.0	3.0	1.4	128
5	4	5.5	CoA, TGA, VSD, RV hypo	1.9	9.0	4.7	1.5	107

BD, balloon diameter; MLD, minimum lumen diameter; The Period, period from previous pulmonary artery banding to right pulmonary artery-plasty; CoA, coarctation of the aorta; DIRV, double inlet right ventricle; DORV, double outlet right ventricle; IAA, interrupted aortic arch; AVSD, atrioventricular septal defect; LV hypo, left ventricular hypoplasia; VSD, ventricular septal defect; RV hypo, right ventricular hypoplasia; TGA, transposition of the great arteries; EDA, extended end-to-end direct anastomosis; PAB, pulmonary artery banding



For information, please call 1-800-BRAUN2 (227-2862)  
www.bbraunusa.com



Working Together to Develop a Better Tomorrow

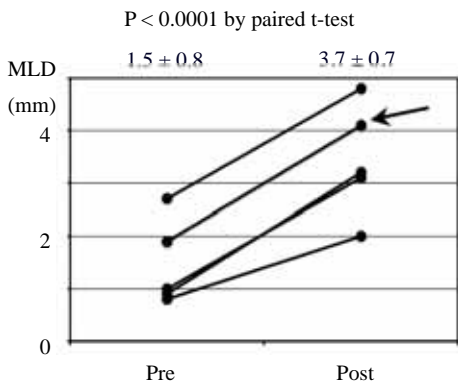


Figure 3. Change in MLD.

One month after intra-operative balloon RPA-plasty and re-PAB, the mean MLD significantly increased from 1.5 ± 0.8 to 3.7 ± 0.7 mm (p<0.0001 by paired t-test). The arrow indicates the data in the patient who was accompanied with RPA rupture.

MLD, minimum lumen diameter; RPA, right pulmonary artery; PAB, pulmonary artery banding.

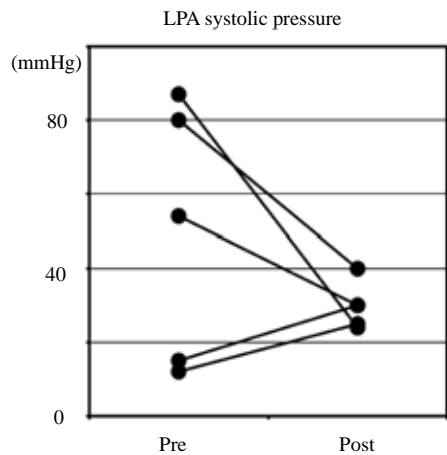


Figure 4. Change in LPA systolic pressure.

Before intra-operative balloon RPA-plasty and re-PAB, LPH was recognized in three patients without LPS, whereas LPH was not recognized in the other two patients with mild LPS in addition to severe RPS. One month after the procedure, each of the LPA systolic pressures changed into more suitable pressures for a Fontan procedure.

LPA, left pulmonary artery; RPA, right pulmonary artery; PAB, pulmonary artery banding; LPH, left pulmonary hypertension; LPS, left pulmonary artery stenosis; RPS, right pulmonary artery stenosis.

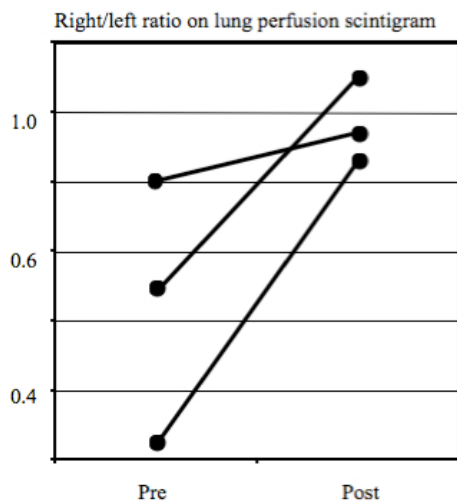


Figure 5. Change in right/left ratio on lung perfusion scintigram.

One month after intra-operative balloon RPA-plasty and re-PAB, each of the right/left ratios on the lung perfusion scintigrams changed close to 1.0: The imbalances between the right and left pulmonary blood flows were improved.

RPA, right pulmonary artery; PAB, pulmonary artery banding.

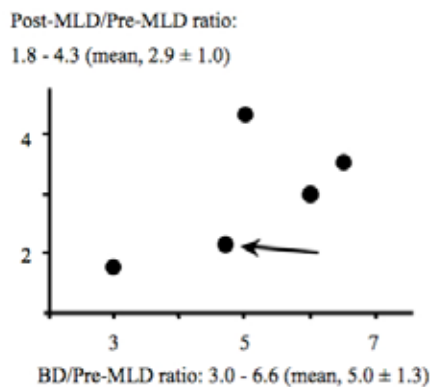


Figure 6. Relationship between BD/pre-MLD and post-MLD/pre-MLD ratios.

There is a tendency that the larger a BD/pre-MLD ratio is, the larger the Post-MLD/Pre-MLD ratio is. The arrow indicates the data in the patient who was accompanied with RPA rupture.

BD, balloon diameter; MLD, minimum lumen diameter; RPA, right pulmonary artery.

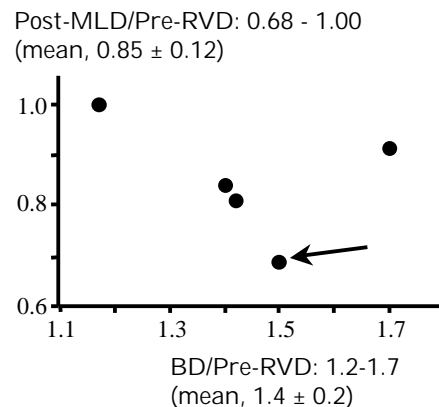


Figure 7. Relation between BD/pre-RVD and post-MLD/pre-RVD ratios.

There is no relationship between the BD/pre-RVD ratio and the post-MLD/pre-RVD ratio.

BD, balloon diameter; MLD, minimum lumen diameter; RPA, right pulmonary artery.

studied the relationships between the BD/pre-MLD and the post-MLD/pre-MLD ratios and between the BD/pre-RVD and the post-MLD/pre-RVD ratios

A successful dilation was defined as a post-MLD that was larger than 150% of the pre-MLD. The mean pre-MLD and post-MLD were compared by paired t-test with Stat View 5.0 software (Abacus Concepts, Berkeley CA, USA). A value of p < 0.05 was considered as significant.

**Results**

In the five patients, the time to perform balloon RPA-plasty, which is from making a purse string suture to ligating the site, ranged from 8 to 15 minutes (median, 10 minutes). RPA rupture accompanied the third balloon-inflation in one patient (No. 5). The rupture was recognized on the right posterior side of the RPA origin where the dislocated band had compressed. The ruptured part was sutured within 5 minutes, although red blood cell products were transfused into the patient. She is the only patient that needed blood transfusion. No other complication was recognized during and after the procedures.

One month after the procedure, the mean MLD significantly increased from 1.5 ± 0.8 to 3.7 ± 0.7 mm (Figure 3) and the mean RVD was maintained or slightly increased (pre-RVD: 4.6 ± 1.2 mm, post-RVD: 4.9 ± 1.4 mm). Every balloon RPA-plasty was evaluated as successful dilation. Before the

procedure, LPH was recognized in three patients without left pulmonary artery stenosis (LPS), whereas LPH was not recognized in the other two patients with mild LPS. Each of the LPA systolic pressures improved, making the patients more suitable candidates for the Fontan procedure (Figure 4). Each of the right/left ratios on the scintigrams turned close to 1.0. The imbalances between the right and left pulmonary blood flows were also improved (Figure 5).

Figure 6 shows the relationship between the BD/pre-MLD ratio and the post-MLD/pre-MLD ratio. There is a tendency that the larger the BD/pre-MLD ratio is, the larger the post-MLD/pre-MLD ratio is. However, there is no relationship between the BD/pre-RVD ratio and the post-MLD/pre-RVD ratio (Figure 7).

**The Outcome of the Five Patients**

In four patients, bidirectional Glenn procedure and Damus-Kaye-Stansel anastomosis were performed at ages ranging from 6 to 15 months, and total cavopulmonary connection was achieved at ages ranging from 16 to 23 months. In another patient (No. 2), subaortic stenosis got worse rapidly and Damus-Kaye-Stansel anastomosis and right modified Blalock-Taussig shunt were performed at her age of 2 months. But right ventricular dysfunction gradually worsened and she died of right ventricular failure at age 6 months.

**Discussion**

We considered several procedures to improve the RPS due to band dislocation. Although it must be possible to perform bidirectional Glenn procedure with RPA-plasty, pulmonary vascular beds will not grow if it is performed in very early infancy[1,2]. RPA patch enlargement is difficult to do without CPS, and may also require blood transfusion. Therefore, we selected this procedure. Balloon RPA-plasty also causes little bleeding, which is not the case in RPA enlargement using instruments like Pean's forceps without CPS.

There is no evidence for how much BD should be selected for RPS due to band dislocation. RPS was not recognized in any of these five patients before PAB. It is thought that a band dislocated to the distal position squeezes the RPA origin, and the squeezed part of the RPA shrink. We do not think of this condition as true stenosis for a certain time because in Post-PAB cases, the adhesion around the bands is not so prominent that the debanded parts of the main pulmonary arteries expand without such procedures as patch enlargement within 8 weeks [3,4]. On the other hand, pulmonary artery stenosis surrounded by significant scar tissue is recognized as soon as 14 weeks after PAB [5-7]. Namely, we think that the squeezed and shrinking part of the RPA with trivial adhesion can expand to nearly the same size as that before band dislocation within a certain period. Therefore, we selected the balloon catheters whose diameters were about 150 % (140 ± 20 %) of the RVDs. As a result, the mean BD used was 5.0 ± 1.3 times as large as the mean MLD although balloon catheters whose diameters are 3-5 times larger than the MLDs that are usually used



Heart Valves • Cannulae • Oxygenators & Filters  
RVOT Conduits • Ablation Technologies • Pacemakers • ICDs

*Committed to providing more options  
for the lifetime care of patients  
with congenital heart disease.*



UC200029144 EN © Medtronic, Inc. 2007



SPECIALTY REVIEW IN **Pediatric Cardiology**  
SEPTEMBER 15-19, 2008 • CHICAGO

**A BOARD REVIEW COURSE PRESENTED BY**  
UIC University of Illinois at Chicago College of Medicine  
— in collaboration with —  
• Society of Pediatric Cardiology Training Program Directors  
• Children's Memorial Hospital (Chicago)  
**[www.conferences.uiuc.edu/PedCardReview](http://www.conferences.uiuc.edu/PedCardReview)**

to perform percutaneous transluminal angioplasty for branch pulmonary artery stenosis [8-10].

RPA rupture was recognized in the Case No. 5 (Table). In this case, the BD/MLD ratio is not larger, but the period from previous PAB to balloon RPA-plasty is longer than in others. The longer a time from previous PAB to RPA-plasty is, the more fibrosis must grow around the shifted band and the banded vessel wall itself also may get firm. Taking the time into consideration, the BD used in the Case No. 5 is thought to be relatively large. Vessel rupture might have happened in the Case No. 3 because of its relatively large BD/MLD ratio and long period from previous PAB to balloon RPA-plasty.

As a result of intra-operative balloon RPA-plasty and re-PAB in these five cases, we will select balloon catheters to perform this procedure as follows: Within the first six weeks from the previous PAB, one should select a balloon catheter whose diameter is 150% of the RVD, because the major cause of RPS is probably shrink of the vessel wall. On the other hand, beyond the early period from previous PAB, one should select a balloon catheter whose diameter is 3.0-5.0 times the MLD because the cause of RPS may be scarring, as well as shrinkage of the vessel wall. Although it is commonly thought that a minimum of 6 weeks must pass for adequate formation of scar tissue around new surgical sites, there is not clear evidence of how long the early period is after PAB [11,12].

As we have performed this procedure in only five cases; we need to accumulate more experience in order to establish clearer guidelines.

#### Conclusion

We performed intra-operative balloon RPA-plasty and re-PAB without CPS for RPS due to band dislocation in five infants with functional single ventricle. The procedure was evaluated as effective by cardiac catheterization and angiography performed one month after the procedure. To make this procedure most effective without complications, we will perform it with a balloon catheter whose diameter is 150 % of the RVD within 6 weeks from previous PAB.

#### References

1. Reddy VM, Liddicoat JR, Hanley FL. Primary bidirectional superior cavopulmonary shunt in infants between 1 and 4 months of age. *Ann Thorac Surg* 1995; 59: 1120-26.
2. Mendelsohn AM, Bove EL, Lupinetti FM, Crowley DC, Lloyd TR, Beekman III RH. Central pulmonary artery growth patterns after the bidirectional Glenn procedure. *J Thorac Cardiovasc Surg* 1994; 107: 1284-90.
3. Iyer KS, Sharma R, Kumar K, Bhan A, Kothari SS, Saxena A, Venugopal P. Serial echocardiography for decision making in rapid two-stage arterial switch operation. *Ann Thorac Surg* 1995; 60: 658-64.
4. Jonas R, Giglia TM, Sanders SP, Wernovsky G, Nadal-Ginard B, Mayer Jr JE, Castaneda AR. Rapid, two-stage arterial switch for transposition of the great arteries and intact ventricular sep-

## MELODY™ Transcatheter Pulmonary Valve ENSEMBLE™ Transcatheter Delivery System

Providing new options  
for the lifetime management  
of patients with congenital  
heart disease

The Melody™ Transcatheter Pulmonary Valve and Ensemble™ Transcatheter Delivery system have received CE Mark approval and are available for distribution in Europe. Additionally, a Medical Device Licence has been granted and the system is available for distribution in Canada. Products are not available for sale in the United States.

© Medtronic, Inc. 2007

**Medtronic**  
Alleviating Pain · Restoring Health · Extending Life

CURRENT TOPICS IN *Patent Ductus Arteriosus*

Strategies for Improved Outcomes

CME ON-DEMAND WEBCAST

[www.5StarMedEd.org](http://www.5StarMedEd.org)

- tum beyond the neonatal period. Circulation 1989; 80 (supple I): I-203-08.
5. Van Nooten G, Deuvaert FE, De Paepe J, Primo G. Pulmonary artery banding. Experience with 69 patients. J Cardiovasc Surg 1989; 30: 334-37.
  6. Gomez R, Sanchez PA, Martinez R, Leon JP, Arteaga M, Villagra F, Verduras MJ, Checa SL, Brito JM. Ventricular septal defect in infancy. Surgical criteria and experience. Jpn Heart J 1983; 24: 699-710.
  7. Dobell ARC, Murphy DA, Poirier NL, Gibbons JE. The pulmonary artery after debanding. J Thorac Cardiovasc Surg 1973; 65: 32-36.
  8. Hoshina M, Tomita H, Kimura K, Ono Y, Yagihara T, Echigo S. Factors determining peripheral pulmonary artery stenosis remodeling in children after percutaneous transluminal balloon angioplasty. Circ J 2002; 66: 345-48.
  9. Gentles TL, Lock JE, Perry SB. High pressure balloon angioplasty for branch pulmonary artery stenosis: Early experience. J Am Coll Cardiol 1993; 22: 867-72.
  10. Hosking MCK, Thomaidis C, Hamilton R, Burrows PE, Freedom RM, Benson LN. Clinical impact of balloon angioplasty for branch pulmonary artery stenosis. Am J Cardiol 1992; 69: 1467-70.
  11. Zahn EM, Dobrolet NC, Nykanen DG, Ojito J, Hannan RL, Burke RP. Interventional catheterization performed in the early postoperative period after congenital heart surgery in children. J Am Coll Cardiol 2004; 43: 1264-69.
  12. Rosales AM, lock JE, Perry SB, Geggel RL. Interventional catheterization management of perioperative peripheral pulmonary stenosis: Balloon angioplasty or Endovascular stenting. Cathet Cardiovasc Intervent 2002; 56: 272-77.

**CCT**

**Recruiting a Pediatric Cardiologist?**

Advertise in Congenital Cardiology Today, the only monthly publication totally dedicated to pediatric and congenital cardiology. For more information, send an email to: [TCarlsonmd@mac.com](mailto:TCarlsonmd@mac.com)

**Corresponding Author**

*Masataka Kitano, MD  
Pediatric Cardiologist  
Department of Pediatrics, National Cardiovascular Center  
Address: 5-7-1, Fujishirodai, Suita, Osaka, 565-8565, Japan  
Voice: 06-6833-5012; Fax: 06-6833-9865*

*kitanom@hsp.ncvc.go.jp*

*Satoshi Yazaki, MD  
Department of Pediatrics  
National Cardiovascular Center,  
Osaka, Japan*

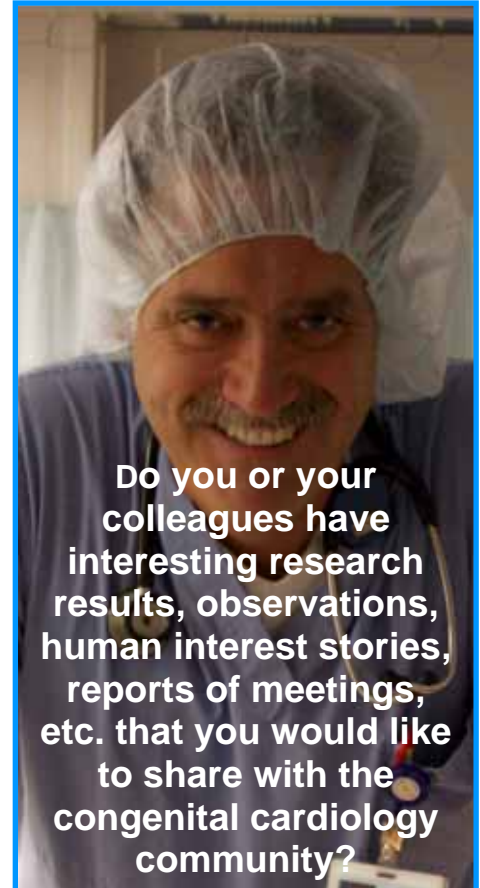*Koji Kagisaki, MD  
Cardiovascular Surgery  
National Cardiovascular Center,  
Osaka, Japan*

*Ikuo Hagino, MD  
Cardiovascular Surgery  
National Cardiovascular Center,  
Osaka, Japan*

*Kenichi Kurosaki  
Department of Pediatrics  
National Cardiovascular Center,  
Osaka, Japan*

*Toshikatsu Yagihara, MD  
Cardiovascular Surgery  
National Cardiovascular Center,  
Osaka, Japan*

*Osamu Yamada, MD  
Department of Pediatrics  
National Cardiovascular Center,  
Osaka, Japan*



**Do you or your colleagues have interesting research results, observations, human interest stories, reports of meetings, etc. that you would like to share with the congenital cardiology community?**

If so, submit a brief summary of your proposed article to Congenital Cardiology Today at: [RichardK@CCT.bz](mailto:RichardK@CCT.bz). Final manuscripts may be between 400 and 4,000 words, contain tables, graphs, charts and pictures.



**6th SPR SYMPOSIUM  
ON PEDIATRIC CARDIOVASCULAR MR  
Dec. 10-14, 2008; Toronto, Canada**

[www.pedrad.org](http://www.pedrad.org) or contact Ms. Vicki Corris ([vicki.corris@sickkids.ca](mailto:vicki.corris@sickkids.ca))



## Highlights from the 2008 Scientific Sessions of the American Society of Echocardiography (ASE)

By Judy Mangion, MD, FASE, FACC, FAHAMD

The 2008 Scientific Sessions of the American Society of Echocardiography (ASE), held June 7-11 in Toronto, Ontario included research presentations, education sessions and awards dealing with pediatric and fetal echocardiography. Original research indicated that a fetal heart ultrasound could be used to determine prenatal markers for congenital heart disease. Education sessions included several presentations on pediatric cardiovascular heart disease and "How-To" demonstrations for the pediatric echo lab. Additionally, several conference attendees were recognized for their research or participation in pediatric echocardiography. The 19th Annual Scientific Sessions provides the leading forum for cardiologists, sonographers and researchers to promote their work and learn about other breakthroughs and developments in the field.



2008 ASE Pediatric and Congenital Heart Disease Council Travel Grant Recipients Shaji C. Menon, MD, Grace R. Choi, MD, and Lowell Frank, MD.

Researchers based at The Children's Hospital of Philadelphia presented findings which identify specific prenatal markers by fetal echocardiogram in fetuses with L-R/VD that predict critical congenital heart disease after birth thereby allowing doctors to plan treatment sooner. The study is titled, "Left Ventricle to Right Ventricle Size Discrepancy in the Fetus: Can We Reliably Predict the Presence of Critical Congenital Heart Disease?"



Pediatric Council Chair Dr. Peter Frommelt with 2008 Award for Excellence in Teaching in Pediatrics winner Norman H. Silverman, MD.

Fetuses who are believed to be at high risk for heart disease based on a specific maternal condition, presence of a genetic abnormality, family history of CHD, or findings of extracardiac anomalies in the obstetrician's office are often referred to a pediatric cardiologist for a fetal echocardiogram. During this exam, doctors look for a variety of markers for CHD, including prenatal ventricular size discrepancy.

Prenatal ventricular size discrepancy with a disproportionately smaller left ventricle than right ventricle (L-R/VD) in the fetus is a strong marker for various forms of congenital heart disease. This study sought to identify specific prenatal markers by fetal echocardiogram in fetuses with L-R/VD that predict critical congenital heart disease after birth. An echocardiogram can help detect if certain fetal parameters are present that predict significant congenital heart disease after birth.

Of the 35 fetuses included in the study, 20 (57%) had critical aortic arch obstruction and underwent neonatal intervention; 15 (43%) did not require newborn intervention. Those with indices that suggested smaller dimensions of left-sided cardiac structures compared to the right-sided structures were more likely to require neonatal intervention. The study concluded that fetal parameters expressing the magnitude of L-R/VD can help identify those who will require neonatal intervention. The findings will improve the ability to determine which fetuses are likely to need neonatal intervention and which will not.



Barth Syndrome  
Foundation

### The Barth Syndrome Foundation

P.O. Box 974, Perry, FL 32348


Tel: 850.223.1128

info@barthsyndrome.org

www.barthsyndrome.org

**Symptoms:** Cardiomyopathy, Neutropenia, Muscle Weakness, Exercise Intolerance, Growth Retardation





2008 Award for Excellence in Teaching in Pediatrics winner Norman H. Silverman, MD poses with outgoing ASE President, Thomas Ryan, MD.

The research was conducted and presented by Michael D Quartermain, Meryl S. Cohen, Troy E. Dominguez, Zhiyun Tian, Denise D. Donaghue and Jack Rychik.

Education sessions throughout the conference included presentations and discussions on pediatric cardiovascular heart disease. Session titles included: "Pulmonary Valve Replacement Improves, but Doesn't Normalize Right Ventricular Function in Children with Repaired Congenital Heart Disease: A Comparative Assessment Utilizing Velocity Vector Imaging" and "Echocardiographic Predictors of Ductus Arteriosus Closure in Extremely Low-Birth Weight Preterm Infants." Additionally, there was an entire session devoted to "How To" instruction for the pediatric echo lab. Tutorials addressed situations like: "How to Introduce New Technology into Your Pediatric Echo Lab," "How to Develop a Comprehensive Fetal Heart Program," and "How to Perform Quality Assurance in the Pediatric Echo Lab." An Online Library of the educational sessions presented at ASE's Scientific Sessions is available for purchase. Visit [www.prolibraries.com/ase](http://www.prolibraries.com/ase).

As part of an ongoing effort by the ASE Pediatric Council to encourage fellows to enter the pediatric cardiovascular imaging field, and to create a meaningful mentoring opportunity for trainees and established imaging faculty at the ASE Scientific Sessions, three trainees received the Pediatric and Congenital Heart Disease Council's travel grant. Dr. Grace R. Choi of Texas Children's Hospital and Baylor College of Medicine, Dr. Lowell Frank of the Children's National Heart Institute and the Children's National Medical Center, and Dr. Shaji C. Menon of the Mayo Clinic, Rochester were awarded \$1,500 toward their travel expenses to attend the 19th annual Scientific Sessions.

There were also awards given out to specifically credit ASE members working in pediatrics. Dr. Norman H. Silverman of Lucile Packard Children's Hospital in Palo Alto, California was named the second recipient of the Award for Excellence in Teaching in Pediatrics. Established in 2005, this biannual award recognizes an ASE member who demonstrates exceptional commitment and skill in teaching pediatric echocardiography, who has been

***"Education sessions throughout the conference included presentations and discussions on pediatric cardiovascular heart disease"***

a mentor to students, serves as a role model for the profession, and fosters a sense of clinical excellence and research investigation in the individuals they teach. Additionally, as part of the 2008 ASE Research Awards, an ASE Echo Investigator Award of \$50,000 was given to Dr. G. Hamilton Baker of the Medical University of South Carolina for research entitled "Pre-load Recrutable Stroke Volume Derived from Three Dimensional Echocardiographic Pressure: Volume Loop Analysis in Congenital and Pediatric Heart Disease."

The Scientific Sessions is the pre-eminent event for the echocardiography community. Each year thousands of attendees, presenters and exhibitors gather to see the latest research, educational programs and products the industry has to offer. Those interested in getting more information or presenting at the 20th Annual Scientific Sessions in Washington, DC should visit [www.ASEScientificSessions.org](http://www.ASEScientificSessions.org).

#### CCT



Judy Mangion, MD, FASE, FACC, FAHAMD  
Associate Director, Noninvasive Cardiac Laboratory  
Brigham and Women's Hospital  
Cardiovascular Division  
75 Francis Street, PBB-1  
Boston, MA 02115 USA  
(P) 617-732-7850  
[jmangion@partners.org](mailto:jmangion@partners.org)

## Medical News, Products and Information

### Biomedical Systems Expands Digisonics DigiView Network



Digisonics, a leading provider of image management and reporting systems for cardiology, vascular, OB/GYN, and radiology, announced that Biomedical Systems, a global provider of centralized diagnostic services for clinical trials, has expanded its DigiView network to include additional workstations for review, analysis and reporting of cardiovascular studies.

Biomedical Systems' physicians interpret clinical studies using the DigiNet Pro system, and rely on secure, web-based cardiovascular image analysis and reporting from virtually anywhere at anytime to ensure timely completion of research projects.

DigiNet Pro provides Biomedical's global readers full edit and measurement capability from over 11 countries simultaneously: the United States, United Kingdom, France, Spain, Portugal, Germany, the Netherlands, Belgium, Mexico, Canada, Puerto Rico, Columbia, and Argentina.

"In the clinical trial industry, meeting critical milestones is crucial," said Beth Gregory, Director of Echocardiography for Biomedical Systems. "Using the DigiNet Pro software allows our readers the flexibility to maintain their active lifestyle without interrupting the trial flow. We have had readers access the system from all over the world, even while vacationing, at anytime of day or night. The flexibility is amazing and a nice luxury for our cardiologists."

Digisonics has set the standard for image management and reporting software systems for over 30 years – with the first review station, the first fully-functional web-based system and the most configurable multi-modality reporting.

Digisonics image management & reporting solutions combine: high-performance image analysis systems, professional reporting, an integrated clinical database, a powerful PACS image archive, and exceptional solutions for remote connectivity.

For further information, contact: Digisonics, Inc., James Devlin, VP Sales & Marketing; 3701 Kirby Dr., Houston, TX 77098; Tel: 800-940-3240; email: [jdevlin@digison.net](mailto:jdevlin@digison.net); url: [www.digison.net](http://www.digison.net)

### The 2nd Asia-Pacific Congress of Pediatric Cardiology and Cardiac Surgery (PCCS2008)



The Second Asia-Pacific Congress of Pediatric Cardiology and Cardiac Surgery (PCCS2008), jointly hosted by the Korean Pediatric Heart Association (KPHA) and the Asia Pacific Pediatric Cardiac Society (APPCS), was held at the Shilla Hotel in Jeju Island, Korea from May 26-30, 2008.

The conference held under the theme of "Leading to the Better Future for Children" aimed to lay the foundation for the further growth of the Asia-Pacific Region to serve as a global center for pediatric cardiology and pediatric cardiac surgery by bringing together distinguished scholars in related fields including: pediatric cardiology, pediatric cardiac surgery, pathology, anesthesia, perfusion, imaging, neonatology, obstetrics, and ICU nursing to exchange the latest developments and knowledge and to build a strong international network.



**Inaugural Congress of Babies without Borders**  
Fairmont Acapulco Princess Hotel & Resort  
Acapulco, Mexico  
September 18-20, 2008

[www.fepece.org](http://www.fepece.org) or [BWBSF@aol.com](mailto:BWBSF@aol.com)



© 2008 by Congenital Cardiology Today  
ISSN: 1544-7787 (print); 1544-0499 (online).  
© 2007 by Congenital Cardiology Today  
(ISSN 1544-7787-print; ISSN 1544-0499-  
online). Published monthly. All rights re-  
served.

#### Headquarters

9008 Copenhaver Dr. Ste. M  
Potomac, MD 20854 USA

#### Publishing Management

*Tony Carlson, Founder & Editor*  
TCarlsonmd@mac.com  
*Richard Koulbanis, Publisher & Editor-in-Chief*  
RichardK@CCT.bz  
*John W. Moore, MD, MPH, Medical Editor/*  
*Editorial Board*  
JMoore@RCHSD.org

#### Editorial Board

Teiji Akagi, MD  
Zohair Al Halees, MD  
Mazeni Alwi, MD  
Felix Berger, MD  
Fadi Bitar, MD  
Jacek Bialkowski, MD  
Philipp Bonhoeffer, MD  
Mario Carminati, MD  
Anthony C. Chang, MD, MBA  
John P. Cheatham, MD  
Bharat Dalvi, MD, MBBS, DM  
Horacio Faella, MD  
Yun-Ching Fu, MD  
Felipe Heusser, MD  
Ziyad M. Hijazi, MD, MPH  
Ralf Holzer, MD  
Marshall Jacobs, MD  
R. Krishna Kumar, MD, DM, MBBS  
Gerald Ross Marx, MD  
Tarek S. Momenah, MBBS, DCH  
Toshio Nakanishi, MD, PhD  
Carlos A. C. Pedra, MD  
Daniel Penny, MD  
James C. Perry, MD  
P. Syamasundar Rao, MD  
Shakeel A. Qureshi, MD  
Andrew Redington, MD  
Carlos E. Ruiz, MD, PhD  
Girish S. Shirali, MD  
Horst Sievert, MD  
Hideshi Tomita, MD  
Gil Wernovsky, MD  
Zhuoming Xu, MD, PhD  
William C. L. Yip, MD  
Carlos Zabala, MD

#### FREE Subscription

Congenital Cardiology Today is available free to qualified professionals worldwide in pediatric and congenital cardiology. International editions available in electronic PDF file only; North American edition available in print. Send an email to Subs@CCT.bz. Include your name, title, organization, address, phone and email.

#### Contacts and Other Information

For detailed information on author submission, sponsorships, editorial, production and sales contact, current and back issues, see website or send an email to: INFO@CCT.bz.



A total of 729 participants from 29 countries including Sudan, UAE, Iran, Saudi Arabia, USA, Canada, UK, Germany, as well as member countries from the Asia-Pacific Region attended this conference. Seventy-six invited speakers from around the world gave state-of-the-art lectures, and had heated discussions with other participants through an electronic voting system. Two-hundred-sixty-two scientific paper presentations (200 oral presentations and 62 posters) were highlights of the congress. Also luncheon symposiums were held everyday.

In an attempt to nurture young researchers, two excellent abstracts were selected to receive the Sejong Young Investigator Award with US \$1,000 in cash grants, sponsored by Sejong Hospital. In addition, 20 participants were chosen among abstract submitters from the Asia-Pacific Region, who had difficulty attending the congress due to financial constraints, to present the *Save the Children Korea Travel Award* with US \$500 in cash grants sponsored by the *Save the Children Korea*. These two awards will be continued for every future PCCS meeting, which will be held every two years, thus establishing a new, and very encouraging tradition in this part of the world. Also, the Asia-Pacific Society of Adult Congenital Heart Disease (APSACHD), as a member society of ISACHD, held their first organizing meeting as a satellite function during PCCS2008. Dr. Koichiro Niwa (Japan)

and Dr. Heung Jae Lee (Korea) organized this memorable event.

In particular, the performance by the Heart Chamber Orchestra (founder and director: Dr. In-Sook Park) was very moving to see and included: Dr. Young Min Eun (a professor of pediatric cardiology), Dr. Taejin Yoon (a professor of pediatric cardiac surgery), and Ms. Hyun Kyung Yoon (member of Jeju City Orchestra) playing chamber music. A fantastic performance of traditional Korean percussion music by "Happinist," a group that included disabled children, received a standing ovation from some 550 participants at the gala dinner.

Dr. In-Sook Park, a professor of the Department of Pediatric Cardiology at the University of Ulsan College of Medicine and Asan Medical Center in Seoul, Korea, and the chairperson of the organizing committee of PCCS 2008, will act as the 3rd President of the Asia-Pacific Pediatric Cardiac Society for the next two years. She has made a great contribution to the advancement in the field of pediatric cardiology and cardiac surgery of Asia through this congress. The 3rd Asia-Pacific Congress (PCCS 2010) will be held in Tokyo, Japan in 2010.

For more details and photographs of the congress, please visit the website at [www.pccs2008.com](http://www.pccs2008.com).

### Do you Want to Recruit a Pediatric Cardiologist?

Advertise in Congenital Cardiology Today, the only monthly publication totally dedicated to pediatric and congenital cardiology. For more information, send an email to: [TCarlsonmd@mac.com](mailto:TCarlsonmd@mac.com)

# DVD Textbook Review: "Congenital Heart Disease Cardiac Morphology & Echocardiography A Multimedia Presentation"

- Authors: Dr. Siew Yen Ho BSc, PhD, FRCPath, FESC, and Dr. William Chin Ling Yip MBBS, M Med, MD, FRCP, DCH, FAMS

By John W. Moore, MD, MPH

In this DVD Text Book ("Congenital Heart Disease Cardiac Morphology & Echocardiography A Multimedia Presentation"), Dr. Ho, a Reader in Cardiac Morphology, Imperial

College, London, and Dr. Yip, a Consultant Paediatric Cardiologist, Gleneagles Hospital, Singapore have created an excellent basic resource for students of congenital heart disease. This DVD is a major multi-media effort as it contains 239 images and 62 narrated video clips of cardiac morphology and a total of 683 images and 525 video clips of echocardiography.

The content includes 26 chapters, each divided into sections on morphology and on echocardiography. The morphology sections include colorful descriptive diagrams and numerous demonstrations of anatomic specimens by narrated videos. The echocardiography sections include examples of still images of 2-D, M mode, and Doppler echocardiograms and of real time 2-D images. The initial chapters cover normal anatomy and the sequential segmental analysis of malformed hearts. The subsequent 24 chapters cover most of the common heart defects.

This is a major contribution to available educational aids; however, there are limitations to this DVD text. Most significantly, the 2-D real time echocardiographic images are of relatively poor quality. In most cases, the images adequately demonstrate the defects of record; however, they almost uniformly fall short of the quality of images commonly acquired in current congenital cardiology echocardiography laboratories. Moreover, the echo examples provided are neither exhaustive nor comprehensive. For example, Chapter 16 on *Univentricular AV Connections* discusses tricuspid atresia, double inlet left ventricle and double inlet right ventricle in the morphology section; however in the echocardiographic section only tricuspid atresia with transposition of the great arteries is demonstrated. Furthermore, the echocar-

**"I found myself 'surfing' the DVD, and I ended up reviewing virtually all of the DVD chapters when my initial plan was only to look at representative ones."**

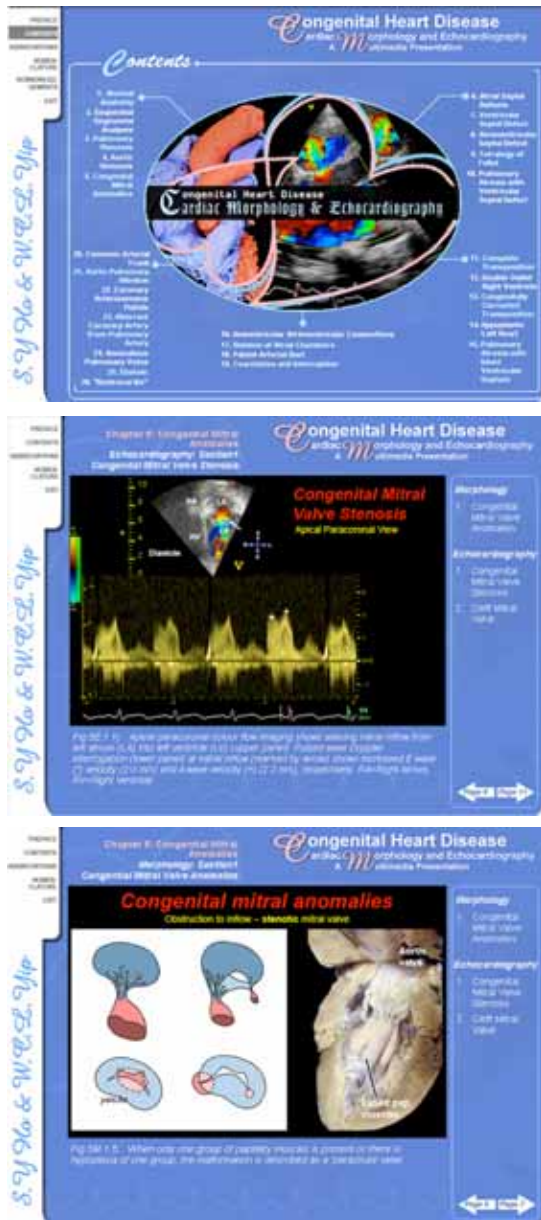
diographic assessment of cardiac chamber size and function and of valve function is not covered in any significant way.

In my view the authors achieve their stated goal of "delivering fundamental knowledge in an interesting format." I found myself "surfing" the DVD, and I ended up reviewing virtually all of the DVD chapters when my initial plan was only to look at representative ones. I believe that this is an excellent instructional aid for students of congenital heart disease (both physicians and echo-technologists) and that it could also function well as a review for many more seasoned practitioners.

CCT

(ISBN 978-981-05-7231-0)  
 Inquiries to: [Morphology@rbht.nhs.uk](mailto:Morphology@rbht.nhs.uk)  
 Distributed by **CARDIOTEXT**,  
[www.cardiotext.com](http://www.cardiotext.com)

John W. Moore, MD, MPH  
 Professor of Pediatrics  
 Chief, Section of Cardiology  
 Department of Pediatrics, UCSD  
 School of Medicine  
 Director, Division of Cardiology  
 Rady Children's Hospital, San Diego  
 3020 Children's Way, MC 5004  
 San Diego, CA 92123 USA  
 (P) 858-966-5855; (F) 858-571-7903  
[jmoore@rchsd.org](mailto:jmoore@rchsd.org)



# BioSTAR<sup>®</sup>

Bioabsorbable Septal Repair

Introducing an Important Advance  
in Structural Heart Repair



## NMT Medical, Inc.

Customer Service: [europesales@nmtmedical.com](mailto:europesales@nmtmedical.com)

27 Wormwood Street  
Boston, MA 02210-1625 USA  
+1-617-737-0930 ext. 304  
Fax: +1-617-737-1084  
[www.nmtmedical.com](http://www.nmtmedical.com)

CE 0086

©2007 NMT Medical, Inc. BioSTAR<sup>®</sup> is a registered trademark of NMT Medical, Inc. All rights reserved.  
BioSTAR<sup>®</sup> is not available in United States.