

CONGENITAL CARDIOLOGY TODAY

News and Information for Pediatric and Congenital Cardiovascular Physicians and Surgeons

Vol. 5 / Issue 2
February 2007
International Edition

WWW.CONGENITALCARDIOLOGYTODAY.COM

INSIDE THIS ISSUE

Transcatheter Completion of Fontan in Saudi Arabia

by Mashail Alobaidan, MD;
Jassim Abdulahameed, MD;
Abdulraoof Alasadi, MD; Amina
Hassan, MD and, Hanan
Abuhassan, MD
~Page 1

Inaugural Pediatric Telehealth Colloquium

by Anita J. Moon-Grady, MD;
Kourosh Parsapour, MD and
James P. Marcini, MD
~Page 8

DEPARTMENTS

March Symposium Focus

~Page 10

Medical News, Products and Information

~Page 12

Medical Symposiums and Meetings

~Page 13

CONGENITAL CARDIOLOGY TODAY

9008 Copenhaver Drive, Ste. M
Potomac, MD 20854 USA
Tel: +1.301.279.2005
Fax: +1.240.465.0692

Editorial Offices:
16 Cove Road, Ste. 200
Westerly, RI 02891 USA

www.CongenitalCardiologyToday.com

© 2007 by Congenital Cardiology Today
(ISSN 1554-7787-print; ISSN 1554-0499-
online). Published monthly. All rights
reserved. Congenital Cardiology pro-
vides timely news and information for
pediatric and congenital cardiologists.
Statements or opinions expressed in
Congenital Cardiology Today reflect
the views of the authors and sponsors,
and are not necessarily the views of
Congenital Cardiology Today.

Need to Recruit a Pediatric Cardiologist?

Advertise in Congenital
Cardiology Today, the ONLY
monthly newsletter dedicated
to pediatric and congenital
cardiology. For more
information send email to:
JOBS@CCT.bz

TRANSCATHETER COMPLETION OF FONTAN IN SAUDI ARABIA

By Mashail Alobaidan, MD; Jassim
Abdulahameed, MD; Abdulraoof Alasadi,
MD; Amina Hassan, MD and Hanan
Abuhassan, MD

Case Report

A 6 year old girl, weighing 23 kgs, had complex congenital heart disease consisting of severe tricuspid valve and right ventricular hypoplasia, normal related great arteries, severe pulmonary valve stenosis, as well as infundibular stenosis, had an emergency modified right Blalock-Taussig shunt at 20 months of age (the initial presentation), followed by modified hemi-Fontan at 5 years of age. She was scheduled for completion of Fontan in the catheter laboratory. Clinically, she had mild exercise intolerance with saturation of 84% at rest and 76% with exertion. She was receiving enalapril in addition to warfarin, and she had an INR of 2.2. Her chest X-ray revealed a normal heart silhouette and normal lung fields. Her ECG showed sinus rhythm and her echocardiogram indicated fair to good systolic ventricular function with no left atrioventricular valve (mitral valve) regurgitation, laminar flow across the Glenn anastomosis and a large communication between the IVC baffle and

systemic atrium measuring about 16 mm. There was no thrombus and no pericardial effusion.

On the day before the procedure the patient was clinically assessed, the proce-

“Recently a new strategy came into practice using a combined surgical and interventional approach: surgery is employed for the hemi-Fontan procedure, consisting of a surgical anastomosis of the SVC and the right pulmonary artery plus creation of a large interatrial communication. This was followed by transcatheter completion of the total cavopulmonary anastomosis. The patency of the SVC and IVC was achieved using a stent (covered or uncovered) and the baffle defect was closed using an Amplatzer Septal Occluder or other device.”

Would you like to share your interesting stories or research in congenital cardiology?

Submit a brief summary of your proposed article to Congenital Cardiology Today at

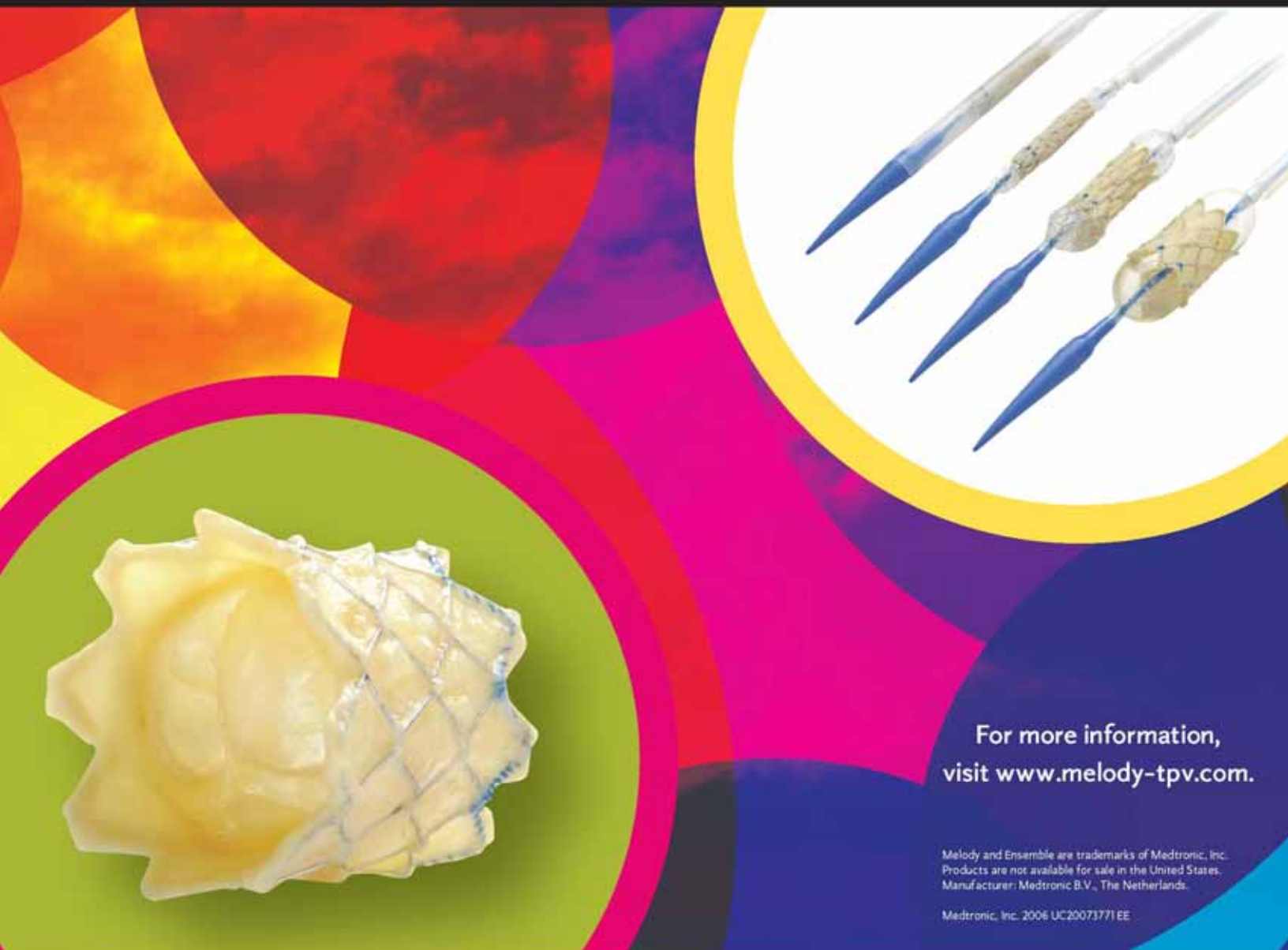Article@CCT.bz

The manuscript may be between 400-3,500 words, contain pictures, graphs, charts and tables.

Medtronic B.V. Announces the World's First Transcatheter Valve To Receive CE Mark Approval

MELODY™
TRANSCATHETER
PULMONARY VALVE

ENSEMBLE™
TRANSCATHETER
DELIVERY SYSTEM



For more information,
visit www.melody-tpv.com.

Melody and Ensemble are trademarks of Medtronic, Inc.
Products are not available for sale in the United States.
Manufacturer: Medtronic B.V., The Netherlands.

Medtronic, Inc. 2006 UC20073771 EE

HEART AND VASCULAR DISEASE • NEUROLOGICAL DISORDERS • PAIN • SPINAL DISORDERS • DIABETES
UROLOGIC DISORDERS • DIGESTIVE SYSTEM DISORDERS • EYE, EAR, NOSE AND THROAT DISORDERS



Medtronic

Alleviating Pain • Restoring Health • Extending Life

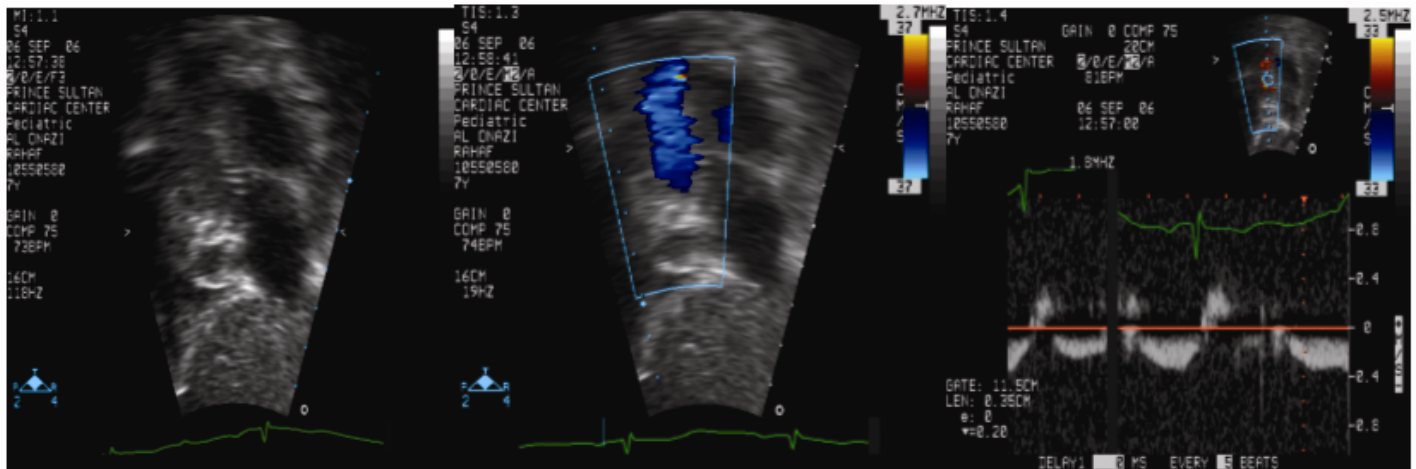


Figure 1. Subcostal views showing stent in RA-SVC junction with laminar flow, normal Doppler velocity, also device was seen closing the communication between lateral tunnel and atrium with no leak.

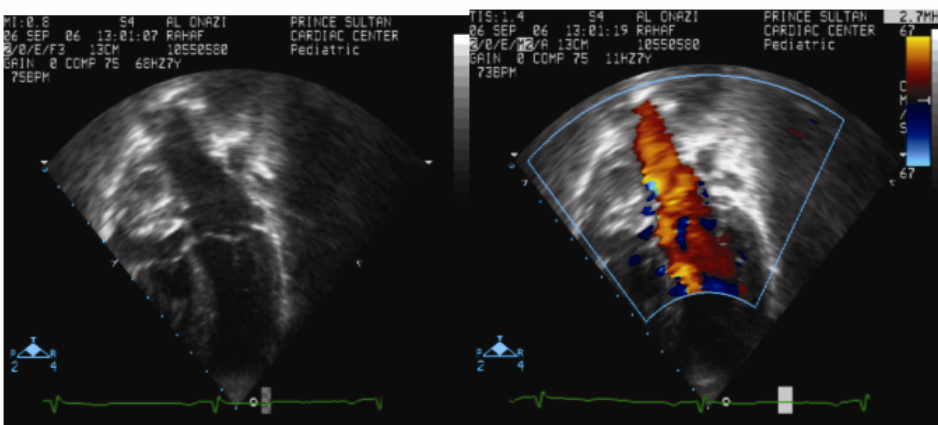


Figure 2. A 4-chamber view showing laminar flow from pulmonary veins to LA to LV through MV, small RV & Device is also seen in situ.

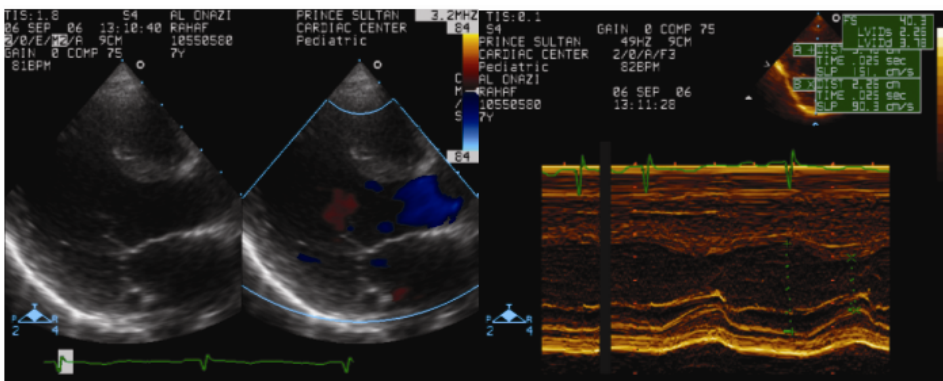


Figure 3. Long axis view showing competent mitral valve and good systolic ventricular function obtained by M-mode.

procedure was explained to the parents and consent was obtained.

The following day, general anesthesia was administered and mechanical ventilation was instituted. Standard hemodynamics were assessed, and bi-plane angiographic views of the main pulmonary artery, superior vena cava, inferior vena cava, left ventricle and aorta (Figure 6) were obtained. Then, the modified Fontan (total cavopulmonary connection) was completed. Hemodynamics were assessed again post procedure. She received heparin 100/kg IU during the procedure, and heparin was continued for 24 hours as an infusion. She was then transferred to the intensive care unit (ICU), and she was extubated the same night with good vital signs and laboratory parameters. She was discharged after 2 days on enalapril and warfarin. Both drugs were to be continued for 4-6 months before being replaced with aspirin.

Echocardiography (Figures 1,2,3), chest X-ray and ECG were repeated before her discharge. The results were positive.



CONTEMPORARY QUESTIONS
IN CONGENITAL HEART DISEASE
THE LEFT HEART

Four Seasons Hotel

June 10-12, 2007; Toronto, Canada

www.sickkids.ca/cardiacsymposium

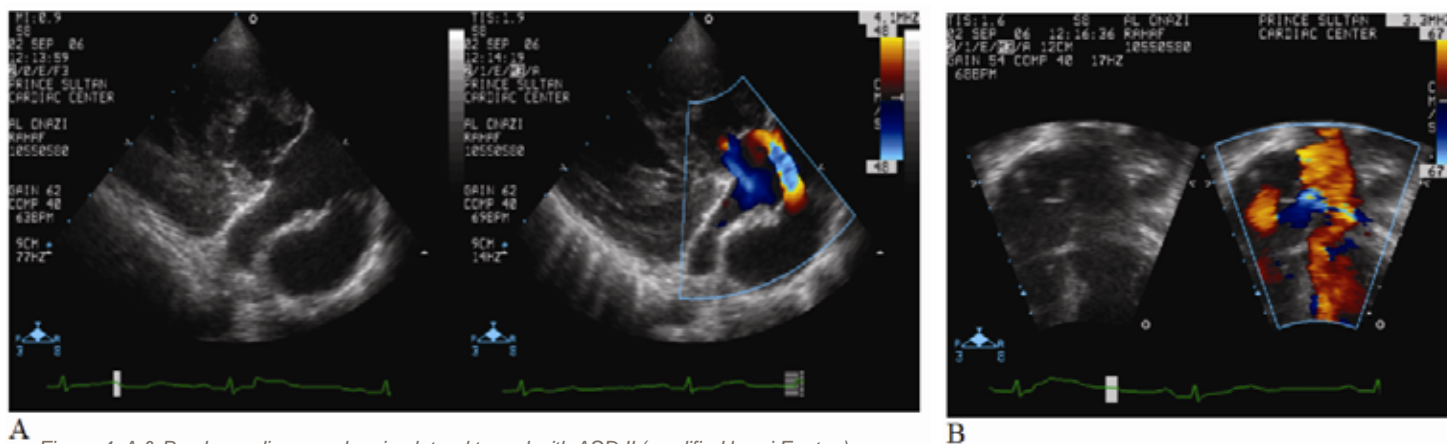


Figure 4. A & B echocardiogram showing lateral tunnel with ASD II (modified hemi Fontan).

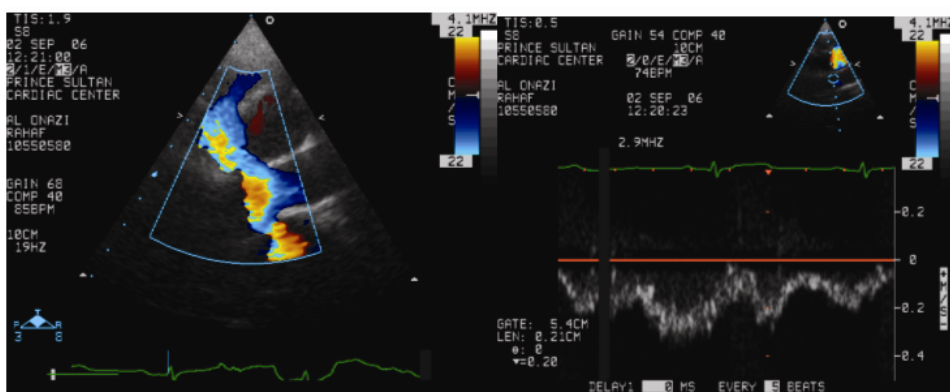


Figure 5. Suprasternal view of the SVC with laminar flow by pulse Doppler.

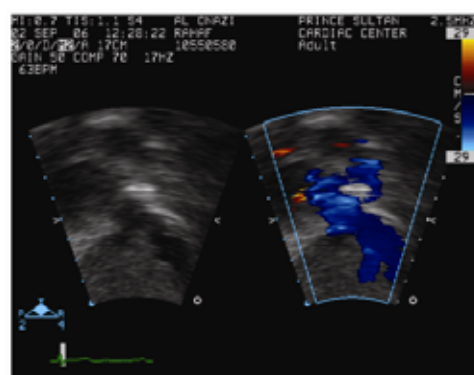


Figure 6. Subcostal view showing IVC laminar flow through the lateral tunnel.

The SVC was closed from the interior of the RA using autologous pericardium. Radio-opaque stitches were used as markers for the planned subsequent transcatheter procedure. A lateral tunnel was made directing the inferior vena cave to the SVC ending with a blind pouch. A 16 mm interatrial communication (ASD II) was created in the tunnel. The RA was closed followed, by de-airing and removal of the aortic cross-clamp and weaning from by-pass. Pacing wires as well as mediastinal and chest drains were placed and the sternum and chest was closed in layers.

Patient Course:

The patients stayed in the surgical ICU for 4 days, and remained on the ventilator for 3 days. She had bleeding which required re-exploration the first night. Milrinone and dopamine were administered for 3 days. She was weaned gradually from the ventilator and extubated. The inotropes were also weaned and oral enalapril and furosemide were initiated. She was transferred to the post operative ward on the 5th day, however, she developed a transudative pleural and pericardial effusion requiring chest drains.

Method

STAGE I:

Surgical Approach (Hemi-Fontan):

Through a median sternotomy, the superior vena cava (SVC) was dissected, transected, and then anastomosed to the right pulmonary artery (RPA), both upper and lower ends, (Figure 7A). Following that, cardiopulmonary by-pass was initiated. Bypass time was 116 minutes; aortic cross-clamp time was 71 minutes. The right atrium (RA) was opened.



PICS 2007 JULY 22-25, 2007
Bellagio, Las Vegas

www.picsymposium.com

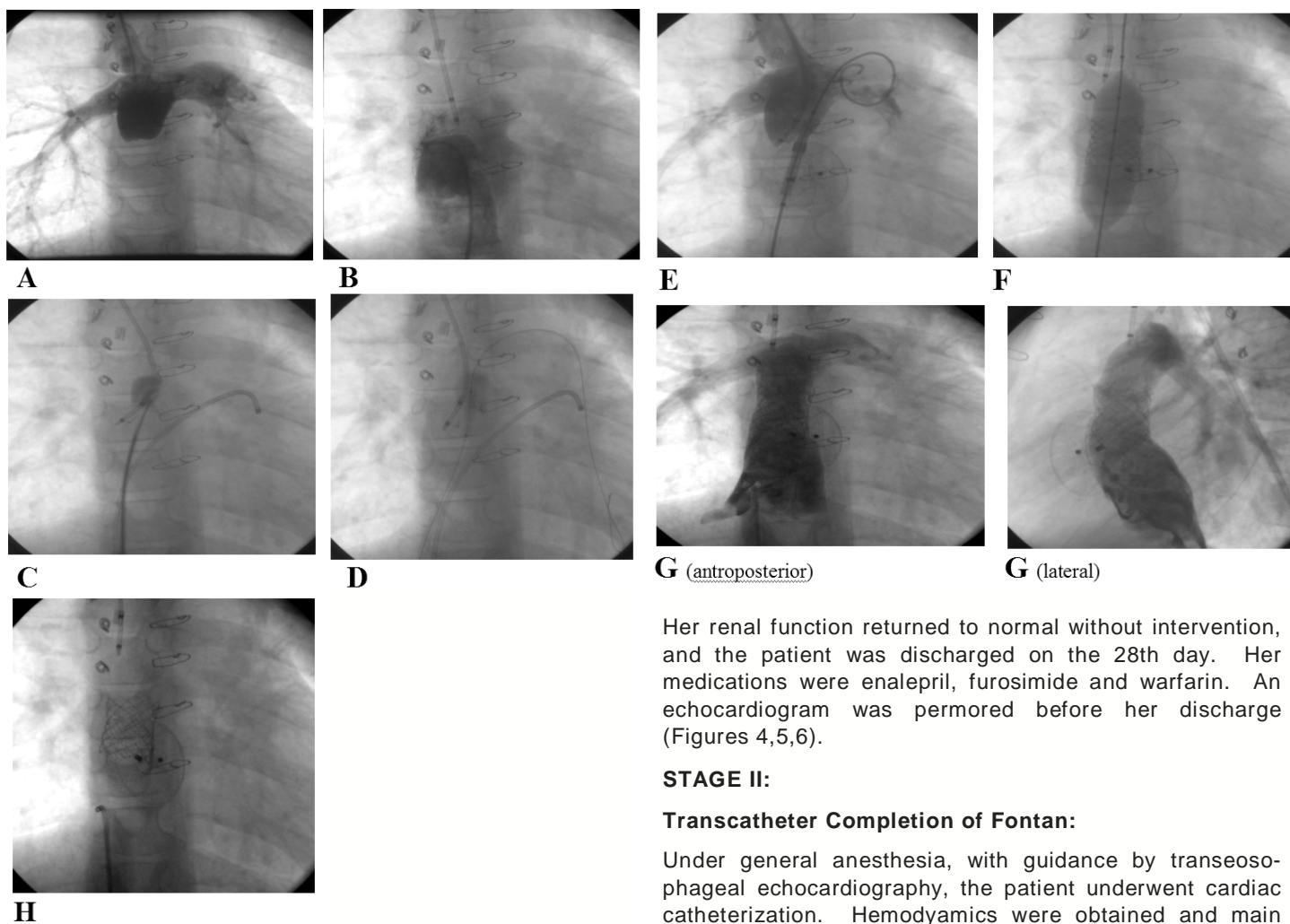


Figure 7. Angiographic illustrations of the transcatheter completion of Fontan procedure: **A:** angiogram in SVC showing RPA anastomosis to SVC in both upper and lower ends; **B:** angiogram in the lateral tunnel with the RA blind pouch; **C:** opening of the pouch using transeptal needle; **D:** balloon dilatation of the hole; **E & F:** stent deployment in SVC-RA communication; **G (AP) & H:** angiogram and plane view showing patency of total cavopulmonary anastomosis after stent and device deployment.

After 25 days the chest drains were removed; she developed signs and symptoms of sepsis and needed broad spectrum antibiotics (amikacin in addition to a 3rd generation cephalosporin). She also had renal impairment thought to be secondary to the use of the aminoglycoside.

Her renal function returned to normal without intervention, and the patient was discharged on the 28th day. Her medications were enalapril, furosimide and warfarin. An echocardiogram was performed before her discharge (Figures 4,5,6).

STAGE II:

Transcatheter Completion of Fontan:

Under general anesthesia, with guidance by transesoophageal echocardiography, the patient underwent cardiac catheterization. Hemodynamics were obtained and main pulmonary artery angiography was performed to delineate the RPA-SVC anastomosis. Simultaneously an angiography was done in the RA where the blind pouch was made, and at the level of the marker stitches. The size of the pericardium pouch (lower end of SVC) was measured to be 16 mm in diameter. The RA-SVC pouch was perforated using a transeptal needle. An uncovered Palmaz stent (P308E) mounted on high pressure Mullins Balloon (size 16x4, PTM420) which was inflated to a pressure of 12 atmospheres. Subsequently, the ASD II was closed using an Amplatzer Septal Occluder (size 17 mm). Hemodynamics measured prior to release of the Amplatzer Device were favorable. She received heparin (100 units/kg) and

Fifteenth Charleston Symposium on Congenital Heart Disease

Embassy Suites Historic District, Charleston South Carolina USA

May 2-4, 2007

Contact: Debbie Bryant (843) 792-3286, bryantd@musc.edu

http://www.musckids.com/heart/conferences/symposium_07.pdf



cefuroxime during the procedure. After the procedure she was transferred to the intensive care unit. (Figure 7).

Hospital Course:

In the intensive care unit, the patient was extubated the first night and required no inotropes. Enalapril and furosemide were administered. Heparin infusion was continued for 24 hrs. Warfarin was started the next day. Three additional doses of cefuroxime were administered. Because she was doing well, she was transferred on the next day to the general ward. She was discharged the following day after repeat chest X-ray, ECG and echocardiography showed good results (Figure 1).

Discussion:

Univentricular repair (Fontan and its modifications) [1,2] is the established surgical option for single ventricle heart lesions. It can be applied as one stage or two stages (Glenn followed by total cavopulmonary anastomosis). The hemi-Fontan, first described in 1991, has undergone many modifications to facilitate completion of Fontan and for preparation of total cavopulmonary connection [3,4,5].

Recently a new strategy came into practice using a combined surgical and interventional approach: surgery is employed for the hemi-Fontan procedure, consisting of a surgical anastomosis of the SVC and the right pulmonary artery plus creation of a large interatrial communication. This was followed by transcatheter completion of the total cavopulmonary anastomosis. The patency of the SVC and IVC was achieved using a stent (covered or uncovered) and the baffle defect was closed using an Amplatzer Septal Occluder or other device. This strat-

“The major advantage of transcatheter completion of the Fontan is that the ‘re-do’ surgery can be avoided including the aortic cross-clamp and related myocardial ischemia.”

egy may offer an improved early post-operative result in the high risk patient. [6].

Hausdorf et. al., in 1996 reported experience in eight patients [6]. In those patients, a bi-directional Glenn anastomosis was constructed and subtotal banding of the communication between SVC and RA was performed using 6-0 prolene suture. A multi-perforated GoreTex baffle was also inserted laterally in the right atrium as part of this first stage. The second stage consisted of balloon dilatation of the band and insertion of a Palmaz iliac stent followed by closure of the perforations using Rashkind PDA occluders or a covered stent.

In 1998, Sidiropoulos et. al. published the German experience of transcatheter completion of Fontan which is similar to the one described by Hausdorf [7].

In 2000, Klima et. al. reported a novel technique for establishing total cavopulmonary connection from surgical preconditioning to interventional completion in 10 sheep with the use of a stent graft (Aneurx Stent) [8].

In 2004, Galantowicz et. al. published the Columbus experience of a new combined surgical/transcatheter approach [9].

Konstantinov et. al., in 2005, published a simple surgical technique for transcatheter completion of total cavopulmonary anastomosis in experimental animals [10] using a covered stent.

In 2006, Konstantinov and Alexi Meskishvili published a review of the use of intracardiac stents for transcatheter completion of total cavopulmonary connection from Canada and Germany [11].

In our center, we have performed this type of staged Fontan successfully in one patient. We are waiting for five additional surgically prepared patients who have had the surgical procedure described earlier. We plan to perform interventional completion of their Fontans.

The early follow-up of our single patient shows a very good result. Thus, we have been encouraged to apply this approach in a large number of selected cases in the future. We believe that there may be a role for use of the Fenestrated Amplatzer Septal Occluder in some of these patients.

The major advantage of transcatheter completion of the Fontan is that the "re-do" surgery can be avoided including the aortic cross-clamp and related myocardial ischemia. The disadvantages are similar to those of the intracardiac Fontan: the main complication being sinus node dysfunction because it is near the cavo-atrial junction where there may be mechanical interference from the stent implantation. To avoid sinus node dysfunction, it may be better to deploy the stent as high as possible in the cavo-atrial junction.

Because of advances in the first stage technique (surgical preconditioning for



11th Vail Symposium on Pediatric Cardiac Diseases

Hosted by The Children's Hospital—Denver

Vail Cascade Resort, Vail, Colorado

March 4-7, 2007

Contact: Dixon.Jeannie@tchden.org or Manzanares.Heidi@tchden.org

transcatheter completion of Fontan), more patients are planned to have this approach, inspite of the lack of favorable long-term outcome data. I believe that we need to have a 10 year review to evaluate non-surgical vs surgical outcomes. Until such a study is performed, because of the marked advantage of non-surgical completion of Fontan, I will advocate using this approach especially in high-risk patients and in others with favorable characteristics for the catheter completion procedure.

References

1. Cardiac Surgery 2nd edition by John W. Kirklin , Brian G. Barratt-Boyes 1996.
2. The Science and Practice of Pediatric Cardiology 2nd edition Garson by Arthur Garson, TR, Bricker, T. Timothy Bricker, David J. Fisher, Steven R. Neish 1996.
3. Knott-Cragi CJ, Fryar-Dragg T, Overholt ED, Razook JD, Waed KE, Elkins RC. Modified hemi-Fontan operation;an alternative palliation for high-risk patient. Ann Thorac Surg 1995 Dec;60(6 Suppl):S554-7.
4. Schmid FX, Wippermann F, Kampmann C, Hilker C, Oelert H, Modified Hemi-Fontan procedure on the beating heart. J Thorac Cardiovas Surg 1990;117:188-190.
5. Harska V. A new approach to hemi-Fontan type of operation. Interactive Cardiovascular and Thoracic Surgery 2003;2:379-381.
6. Hausdorf G, Schneiderc M, Konertz W. Surgical preconditioning and completion of total cavopulmonary connection by conventional cardiac catheterization: a new concept. Heart 1996;75:403-409.

7. Sidiropoulos A, Ritter J, Shnieder M, Konertz W. Fontan modification for subsequent non-surgical Fontan completion. European J. Cardiothoracic Surgery 1998;13:509-513.

8. Klima U, Peters T, Peuster M, Hausdorf G, Haverich A. A novel technique for establishing total cavopulmonary connection; from surgical preconditioning to interventional completion. J Thorac Cardiovasc Surg 2000 Nov ;120 (5):1007-9.

9. Galanowicz M, Cheatham JP. Fontan completion without surgery. Semin Thorac Cardiovasc Surg Pediatr Card Surg Annu 2004;7:48-55.

10. Konstantinov IE, Benson LN, Caldarone CA, Li J, Shimizu M, Coles JE, Van Arsdell GS, Williams WG. A simple surgical technique for interventional transcatheter completion of the total cavopulmonary connection. J Thorac Cardiovasc Surg 2005;129:210-212.

11. Konstantinov IE, Alexi-Meskishvili VV. Intra-cardiac covered stent for transcatheter completion of the total cavopulmonary connection: Anatomical, physiological and technical consideration. Sndiaan Cardiovascular Journal 2006 April; 40(2):71-7.

12. Crystal MA, Yoo SJ, Mikailian HJ, Benson LN. Catheter-Based Completion of the Fontan circuit: A Nonsurgical Approach. Circulation 2006;114 (1):5-6.

~CCT~

Corresponding Author:

Mashail AL-Obaidan, MBBS, MRCP(1), MD, PHD, KFF, ABS, KSF
Consultant Pediatric Cardiology
Prince Sultan Cardiac Center
Division of Pediatric Cardiology
PO BOX 999111
Riyadh 11625
KSA
Fax/Tel: 00 9661473-0049
Tel: 4777714 EXT: 8795
Pager: 4110
Email: mashaila@hotmail.com

Jassim Abdulahameed, MBBS, MRCP, MD
Division of Pediatric Cardiology,
Prince Sultan Cardiac Center
(PSCC), Riyadh, KSA

Abdulraoof Alasadi, MBBS, MD, FRCSC
Division of Pediatric Cardiology,
Prince Sultan Cardiac Center
(PSCC), Riyadh, KSA

Amina Hassan, MBBS, MRCP
Division of Pediatric Cardiology,
Prince Sultan Cardiac Center
(PSCC), Riyadh, KSA

Hanan Abuhassan, MBBS, MD, ABS
Division of Pediatric Cardiology,
Prince Sultan Cardiac Center
(PSCC), Riyadh, KSA

Need to Recruit a Pediatric Cardiologist?

Advertise in Congenital Cardiology Today, the ONLY monthly newsletter dedicated to pediatric and congenital cardiology. For more information send email to:

JOBS@CCT.bz



CONTEMPORARY QUESTIONS
IN CONGENITAL HEART DISEASE
THE LEFT HEART

Four Seasons Hotel

June 10 -12, 2007; Toronto, Canada

www.sickkids.ca/cardiacsymposium

INAUGURAL PEDIATRIC TELEHEALTH COLLOQUIUM

By Anita J. Moon-Grady, MD; Kourosh Parsapour, MD and James P. Marcin, MD

(The Pediatric Telehealth Colloquium held in San Francisco, CA, on October 27-29, 2006 was a 3-day international conference designed to address a variety of medical applications of telemedicine for improving access, quality of care and patient outcomes in pediatrics. Additionally, topics in strategic and administrative planning, equipment and technical support, research and the advancement of telehealth were discussed. This summary highlights the topics that were addressed with the hopes of generating further interest and support for future meetings. The goal is to provide an annual forum where experiences in telehealth can be shared and its development may be enhanced.)

The regionalization of children's hospitals has led to higher quality of care and improved outcomes among pediatric patients. However, children living in non-urban areas have little to no access to pediatric specialty care. Telemedicine has become a novel solution to provide children in rural communities with access to subspecialists. The inaugural Pediatric Telehealth Colloquium was held in San Francisco, California on October 27-29, 2006, providing a forum for national and international experts in pediatric telehealth to share their experiences with each other and with other groups interested in establishing new telemedicine programs.

The Colloquium was held at the Hotel Nikko and was at maximum capacity with nearly one hundred attendees from

the United States as well as international attendees from the Caribbean and Australia. The backgrounds of the attendees ranged from Children's Hospital specialists to rural physicians and



By using telemedicine, Governor Schwarzenegger meets with one of the patients in the PICU at the UC Davis Children's Hospital.

nurses, as well as health care administrators seeking information on implementing and sustaining telemedicine networks. Representatives from eight companies were also available to discuss their products ranging from infrastructure support to telemedicine robotics.

The conference presentations were structured around four themes: inpatient telemedicine, outpatient telemedicine, telehealth administration, and alternative applications of telemedicine. Dr. Tom Nesbitt provided the introduction and overview of telemedicine, with historical and future perspectives and applications. Following Dr. Nesbitt, a general "Telehealth Technology 101" lecture was given by Dan Kurywchak who has spent more than 17 years working with telemedicine technologies and provided the basic definitions and an overview that would be discussed over the three day Colloquium.

The conference keynote speaker was the Governor of the State of California, Arnold Schwarzenegger. Governor Schwarzenegger spoke about the "...life changing benefits of broadband...and the incredibly important work that can be done with these high speed and high performance technologies." In a live demonstration, Governor Schwarzenegger was connected via videoconference and spoke with an 11-year-old girl with leukemia and multiple other medical problems hospitalized in the Pediatric Intensive Care Unit (PICU) at the University of California, Davis Children's Hospital in Sacramento, California (90 miles or 145 km away, Figure 1). Finally, the Governor signed an executive order to help develop broadband networks that would assist government agencies in gaining access to the best available technologies to serve the people of California. He also called for the creation of a task force that would enable government and business experts to work together to improve broadband internet access across California and the rest of the United States.

After the Governor's appearance, the topic of "inpatient telemedicine" was introduced and moderated by Dr. Kourosh Parsapour. Dr. Randall Wetzell provided an overview of the applications of inpatient telemedicine along with a discussion regarding the advancement of the virtual PICU project at the Children's Hospital Los Angeles. The UC Davis experience in providing inpatient consultations by telemedicine was discussed by Dr. James Marcin. Dr. Marcin presented data from ongoing research studies evaluating the impact of telemedicine on patients and families in rural facilities receiving pediatric emergency and critical

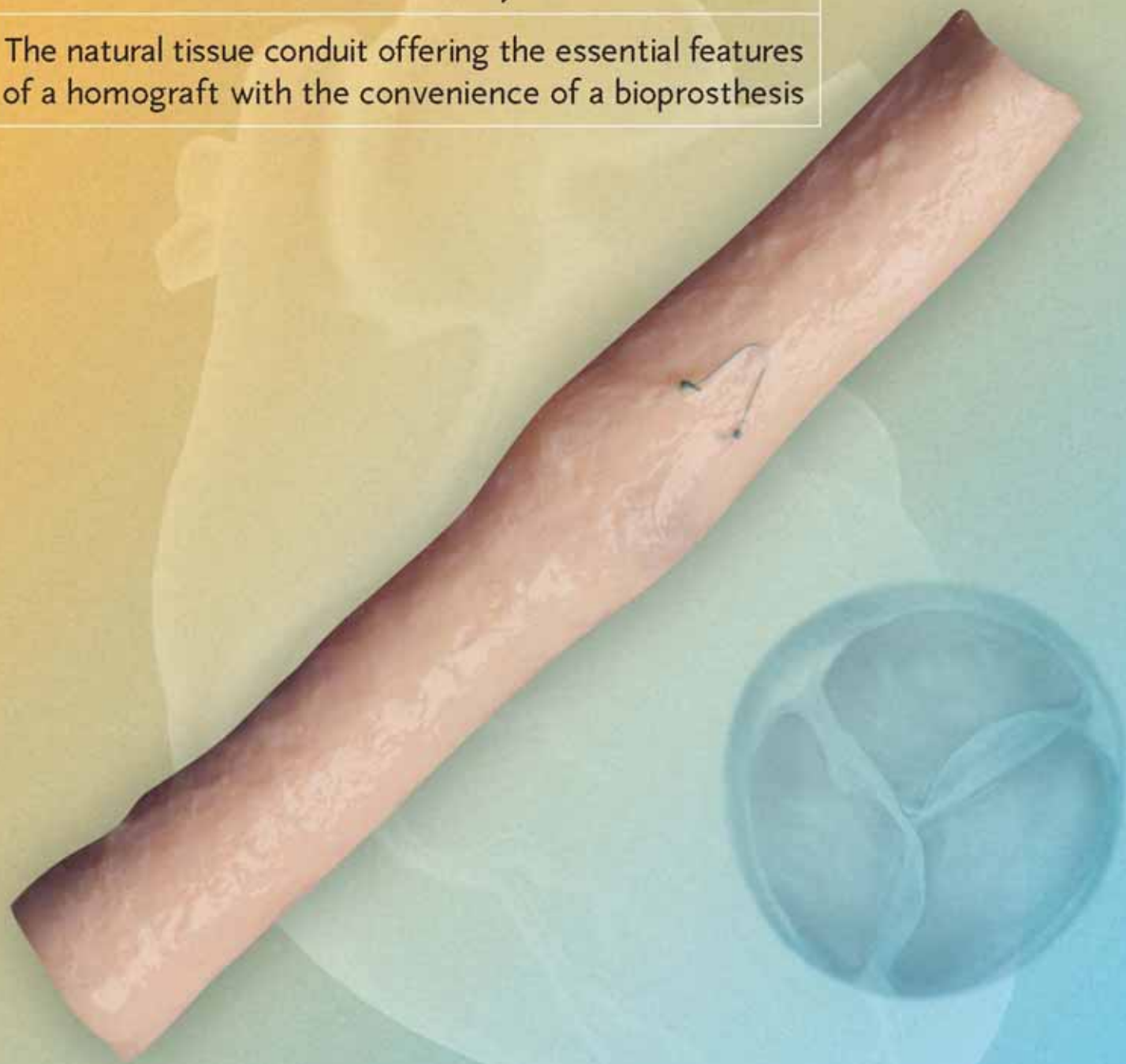


PICS 2007 JULY 22-25, 2007
Bellagio, Las Vegas

www.picsymposium.com

CONTEGRA[®] Pulmonary Valved Conduit

The natural tissue conduit offering the essential features of a homograft with the convenience of a bioprosthesis



This device has been approved as a humanitarian use device in the U.S.

CONTEGRA[®] Pulmonary Valved Conduit

Indications: See "Humanitarian Use Device" section below. **Contraindications:** - Patients 18 years and older. • If, after assessment of the risk to benefit ratio by the physician, superior clinical results are suggested by presently established alternative medical or surgical techniques. **Warnings/Precautions/Side Effects:** Acceptable clinical performance has been established for the Contegra conduit in pediatric patients under the age of 10. Because of the possibility that complications of the device could become apparent only after extended use, a benefit-risk consideration of the long-term use of the Contegra conduit in pediatric patients over 10 years of age is particularly important. General complications reported with valved conduits and biological tissue valves implanted in the heart include: hemorrhage, bleeding diathesis due to use of anticoagulants, residual or increasing transvalvular gradients, progressive neointimal thickening and peeling, progressive stenosis and obstruction, progressive pulmonary hypertension, graft infection, endocarditis, regurgitation, hemolysis, valve malfunction, physical or chemical deterioration, thromboembolism, thrombus, conduit dilatation. For additional information, please refer to the Instructions For Use provided with the product. **CAUTION:** Federal law (USA) restricts this device to sale by or on the order of a physician.

***Humanitarian Use Device:** Authorized by Federal law for use in patients under 18 years of age for correction or reconstruction of the Right Ventricular Outflow Tract (RVOT) in the following congenital heart malformations: Pulmonary Stenosis, Tetralogy of Fallot, Truncus Arteriosus, Transposition with Ventricular Septal Defect (VSD), Pulmonary Atresia. In addition, the Contegra Pulmonary Valved Conduit is indicated for the replacement of previously implanted but dysfunctional pulmonary homografts or valved conduits. The effectiveness of this device for these uses has not been demonstrated.

UC200703776 EN



care consultations. Following this discussion, two primary care practitioners (Drs. Steve Struve and Mark Satterfield) from remote facilities shared with the audience their perspectives and provided lessons learned from their experience in a telemedicine relationship with tertiary centers. Finally, Dr. Karen Rheuban (University of Virginia) concluded the session with a discussion of the expanding use of pediatric telemedicine in the State of Virginia. In particular, she focused on the successful use of live (real-time videoconferencing for echocardiogram examinations) and store-and-forward (digital acquisition of echocardiograms with subsequent transmission of images for review) telemedicine in telecardiology.

"Telehealth administration" was the focus of the latter part of the first day, with a session moderated by Dr. Marcin. Ms. Anna Orłowski, Chief Counsel for the UC Davis Health System provided an in-depth discussion of the legal and regulatory issues that surround many of the current telemedicine programs in the United States. Ms. Kathy Chorba, the Operations and Business Development Manager for the Health Systems Center for Health and Technology at UC Davis, discussed administrative aspects of implementation of a telemedicine program and the requirements for sustaining the program after inception. These topics were very popular with conference attendees who were in the early phases of developing a program, as well as with individuals from institutions with well-established telemedicine networks. The day concluded with an opportunity for conference participants to interact with each other and experience a hands-on opportunity with the various technologies and demonstrations.

The second day of the colloquium focused on telemedicine applications for the delivery of outpatient services to patients in rural and remote areas. Dr. Javeed Siddiqui (Associate Medical Director, Cen-

ter for Health and Technology, UC Davis) began the day with a general synopsis of "outpatient telemedicine" applications in the USA, then elaborated on the various applications of telemedicine at the UC Davis Children's Hospital including use in assisting with evidence collection and appropriate exams for suspected victims of child abuse, allowing for multidisciplinary collaboration for treatment regimens in pediatric oncology, distance assessment of pediatric gastroenterology patients, and management of pediatric obesity. Preliminary favorable results regarding ongoing patient and provider satisfaction studies were presented.

A session on telehealth and alternative applications followed, chaired by Dr. Philip Ozuah (Professor of Pediatrics, Children's Hospital, Montefiore, New York). Dr. Ozuah began with a summary of telemedicine services designed to benefit the underserved populations in the USA and abroad, including the use of videoconferencing for the delivery of health education to immigrant families living in the Bronx as well as a low-cost store-and-forward telemedicine service (supported by the Swinfen Charitable Trust) which provides doctors in developing countries with valuable e-mail based advice regarding specific patient-care queries provided at no cost by volunteer specialists around the world.

Other novel applications for telemedicine in pediatrics discussed during the Colloquium included Dr. Neil Herendeen's (Associate Professor of Pediatrics, Rochester, New York) telemedicine program which provides medical consultation to childcare centers. This service allows children to remain in the childcare center and be "seen" by a physician for complaints ranging from earache to rashes using teleconferencing, thereby reducing the amount of parental leave taken for office-based doctor appointments for minor illnesses and to care for a mildly ill

child at home. Dr. Rifat Latifi, a trauma surgeon from the University of Arizona, described a tele-trauma service which provides remote sites with access to an experienced trauma surgeon during the early critical stages of patient stabilization after critical traumatic injury prior to transport. And finally, Drs. Parsapour and Siddiqui discussed the alternative applications of telemedicine at UC Davis: the FamilyLink program which utilizes a video-phone, TV, and telephone lines to allow hospitalized children to visit with their families and friends during a hospitalization; and a video interpreting service, which allows in-house medical interpreting staff to cover a large hospital and outpatient clinic complex with a limited number of interpreters more efficiently, while assisting the medical team with communicating in a culturally competent manner.

A series of platform presentations were made during the lunch session, featuring Ms. Sarah Rhoads (University of Arkansas) and the ANGEL EYE, a web-based video link for parents to observe their infant during hospitalization in the neonatal intensive care unit. Dr. Kevin Hopkins (Driscoll Children's Hospital) presented his experience with the use of videophones for the postoperative management of children with complex cranio-facial reconstructions. Two excellent presentations from Australian delegates Dr. Anthony Smith and Mr. Nigel Armfield (University of Queensland) highlighted the extensive use for telemedicine in a country with extremely wide expanses which are sparsely populated. They presented the results of an economic evaluation the telepediatric service operated in Queensland by the Centre for Online Health (COH) in conjunction with the Royal Children's Hospital in Brisbane. During its first six years, more than 4,000 consultations have been conducted for children living in regional and remote ar-



Barth Syndrome
Foundation

The Barth Syndrome Foundation

P.O. Box 974, Perry, FL 32348

Tel: 850.223.1128

info@barthsyndrome.org

www.barthsyndrome.org

Symptoms: Cardiomyopathy, Neutropenia, Muscle Weakness, Exercise Intolerance, Growth Retardation

eas for 35 different pediatric subspecialties, with significant savings for the state government mainly due to reductions in government subsidized patient travel expenses. They have also developed a child-friendly mobile and wireless telemedicine system in the shape of a robot, which is now in use in selected regional hospitals in Queensland which lack the services of onsite pediatricians and specialist staff.

The final day of the conference returned to the theme of administration relating to telemedicine services. This session was particularly useful for delegates with limited experience in telemedicine and at the early stages of developing a telemedicine program. This session was chaired by Dr. Sanford Melzer from the Children's Hospital and Regional Medical Center in Seattle, Washington. Dr. Melzer, Ms. Jana Katz (Assistant Dean for Administration at UC Davis) and Dr. Marcin covered issues including program sustainability, financial planning and billing. Ms. Katz reminded delegates to "...take caution to promises that telemedicine equipment will solve all of your problems...ensure that the goals of the telemedicine program are consistent with the mission of the overall organization...and don't underestimate the importance of a good site coordinator."

Finally, Dr. Marcin tackled the economics of telemedicine services offered through the outpatient and inpatient settings. Based on preliminary data gathered through a two-year period in Northern California, and extrapolating these figures over a five-year period, he presented findings demonstrating significant potential financial benefits for the receiving sites of telemedicine services.

The conference also included several abstracts in poster format designed to educate and inform participants regarding studies and other applications for telemedicine technology. Poster topics ranged

from the use of store-and-forward tele-echocardiography for remote Pediatric Cardiology support of a rural level III neonatal ICU lacking a local Cardiologist, to improved outcomes and provider satisfaction with use of telemedicine technology rather than traditional telephone for assisting rural emergency departments during pediatric resuscitations, to the feasibility of a telemedicine-based outreach and behavior modification program for obese adolescent Native Americans living in a rural area of Northern California and a proof-of-concept presentation of the use of a retinal camera for remote ophthalmology examinations in infants at risk for retinopathy of prematurity.

The inaugural Pediatric Telemedicine Colloquium provided an excellent opportunity for attendees to learn about established telepediatric programs and to meet with leaders in the field. The colloquium will continue as an annual event with the next meeting scheduled for Fall 2007 in San Francisco.

~CCT~

Corresponding Author:

Anita J. Moon-Grady, MD, FAAP, FACC

Assistant Professor of Pediatrics
Pediatric Cardiology
UC Davis Children's Hospital
2516 Stockton Blvd.
Sacramento, CA 95817 USA
Fax: (916) 734-0424

anita.moongrady@ucdmc.ucdavis.edu

Kourosh Parsapour, MD
UC Davis Children's Hospital
Sacramento, CA USA

James P. Marcin, MD, MPH
UC Davis Children's Hospital
Sacramento, CA USA

MARCH SYMPOSIUM FOCUS

6th International Workshop on Interventional Pediatric Cardiology

March 28-31, 2007

Crowne Plaza, San Donato Milanese
Milan, Italy

Tel: +39 02 93790014

Fax: +39 02 93572845

<http://www.workshopipc.com/>

Course Director: Mario Carminati

Course Co-Directors: Gianfranco Butera,
Massimo Chessa

San Donato Pediatric Cardiology Team:

Mario Carminati, Gianfranco Butera,
Massimo Chessa, Carmelo Arcidiacono,
Vlasta Fesslova, Angelo Micheletti, Diana
Negura, Luciane Piazza, Luca Rosti

Objective: State of the art and future perspectives on catheter interventional procedures for the treatment of congenital heart disease from fetal life to adulthood.

Workshop Overview: The mission of this Workshop is to provide education through demonstration. All lectures and live transmissions performed by the experts will focus on giving an overview of the latest techniques' state of the art and the status of the management of congenital heart disease. At the end of the Workshop all participants should be able to: (1) know the indications for treatment of endovascular procedures for congenital heart defects, (2) identify the proper device to be used, and (3) discuss the pre- and post-procedural management of patients. The official language will be English; simultaneous translation provided.

CME hours: Currently undergoing evaluation for CME accreditation by the Italian Ministry of Health, EBAC and UEMS.

More than 40 International Faculty including:

Z. Amin -Chicago (USA); R.H. Anderson-London (UK); L. Benson-Toronto (Canada); P. Bonhoeffer-London (UK); G. Butera-San Donato (Italy); J.P. Cheatham-Orlando (USA); W.E. Hellenbrand-New York (USA); A. Ludomirsky-St. Louis (USA); M. Hijazi-Chicago (USA); S.A. Qureshi-London (UK); J.F. Piéchaud-Paris (France); M. Ranucci-San Donato (Italy); H. Sievert-Frankfurt (Germany); M. Tynan-London (UK), to mention a only a few.



11th Vail Symposium on Pediatric Cardiac Diseases

Hosted by The Children's Hospital—Denver

Vail Cascade Resort, Vail, Colorado

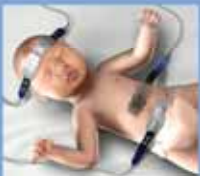March 4-7, 2007

Contact: Dixon.Jeannie@tchden.org or Manzanares.Heidi@tchden.org

SOMANETICS®

**REVEAL TISSUE
PERFUSION**

**WITH SITE-SPECIFIC
SATURATION DATA**

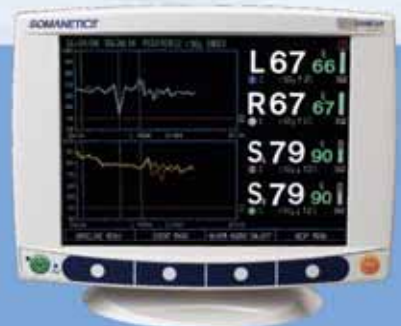

Augment *systemic* data with noninvasive *regional* oxygen saturation (rSO_2) from up to four sites. Only the INVOS® Cerebral/Somatic Oximeter monitors oxygenation data from the brain and body simultaneously and continuously. This site-specific tissue perfusion can enhance your clinical assessment in a meaningful way and help detect ischemic problems earlier than traditional measures. This additional vital sign lets you intervene and put things right — before they escalate.

800-359-7662 www.somanetics.com

REFLECTING THE COLOR OF LIFE™

INVOS CEREBRAL/SOMATIC
OXIMETER



© 2006 Somanetics Corporation. Somanetics and INVOS are registered trademarks of Somanetics Corporation. "Reflecting the color of life" is a trademark of Somanetics Corporation. US federal regulations restrict the sale of this device to, or on the order of, licensed medical practitioners.

MEDICAL NEWS, PRODUCTS AND INFORMATION

**Medtronic Announces
Canadian Market Release of
the First Transcatheter Valve
Replacement System for
Structural Heart Disease**

Medtronic, Inc. has announced that it has received a Medical Device License from Health Canada to sell its Melody™ Transcatheter Pulmonary Valve and Ensemble™ Transcatheter Delivery System. The system is the first of its kind in North America to treat patients with congenital and acquired structural heart disease requiring pulmonary valve replacement.

The Medtronic Melody™ Transcatheter Pulmonary Valve and Ensemble™ Transcatheter Delivery System are designed to benefit patients with congenital heart defects involving the connection between their right ventricle and pulmonary artery. Oftentimes, this type of defect requires open heart surgery early in life to implant a prosthetic valved conduit to establish adequate blood flow from the heart to the lungs. However, the functional life span of these conduits is relatively limited, and as a result most patients with this type of defect are committed to multiple open heart surgeries over their lifetime. The Melody Valve and Ensemble system provide a non-surgical means to restore effective valve function and prolong the functional life of prosthetic conduits, thereby reducing the number of open heart surgeries for these patients throughout their lifetime.

In Canada, congenital heart defects occur in one out of every 100 babies

born each year and more than 20% of defects involve the pulmonary valve.

"Medtronic of Canada is proud to partner with the leading cardiovascular health professionals across Canada to offer the Melody™ Transcatheter Pulmonary Valve to their patients with congenital heart valve disease. Managing such a complex disease requires a cohesive team approach between cardiac surgeons and interventional cardiologists and we are committed to delivering technologies to these Canadian physicians and their patients to achieve compelling outcomes and fulfill our Mission to alleviate pain, restore health, and extend life," said Neil Fraser, President of Medtronic of Canada Ltd.

To date, more than 190 patients worldwide have been implanted with the Melody Transcatheter Pulmonary Valve. In Canada, Dr. Lee Benson, an interventional cardiologist, at the Hospital for Sick Children in Toronto and Dr. Eric Horlick, at the University Health Network, Toronto General Hospital, Toronto were the first in North America to implant Melody Valves under special access permission from Health Canada in October 2005. Dr. Benson reports that the safety and efficacy of the implant is excellent, with excellent functional improvement in the patients.

The University of Alberta Hospital in Edmonton, The Toronto General Hospital, Hôpital Laval in Québec City, and McGill University Health Centre count trained physicians on their staff to perform the procedure.

Transcatheter valve technology represents a less invasive means to treat heart valve disease and is designed to

allow physicians to deliver replacement valves via a catheter through the body's cardiovascular system, thus eliminating the need to open the chest. Traditionally, open heart surgery has been required to correct the problem and it is not unusual for a patient to undergo multiple, open-heart surgeries during their lifetime. Patients with this condition can tire easily, as the heart over-exerts itself trying to get blood from the right heart into the pulmonary circulation. "The application of these transcatheter valve technologies has altered the way we approach management of congenital and structural heart disorders," reports Dr. Benson.

For more information:
www.medtronic.com.

**Google Can Help Doctors Diagnose
Difficult Cases**

Searching with Google may help doctors to diagnose difficult cases, finds a study from Australia published on bmj.com today.

Doctors have been estimated to carry two million facts in their heads to help them diagnose illness, but with medical knowledge expanding rapidly, even this may not be enough. Google is the most popular search engine on the world wide web, giving users quick access to more than three billion medical articles.

So, how good is Google in helping doctors diagnose difficult cases?

Doctors at the Princess Alexandra Hospital in Brisbane identified 26

Fifteenth Charleston Symposium on Congenital Heart Disease

Embassy Suites Historic District, Charleston South Carolina USA

May 2-4, 2007

Contact: Debbie Bryant (843) 792-3286, bryantd@musc.edu

http://www.musckids.com/heart/conferences/symposium_07.pdf



difficult diagnostic cases published in the New England Journal of Medicine in 2005. They included conditions such as Cushing's syndrome and Creutzfeldt-Jakob disease.

They selected three to five search terms from each case and did a Google search while blind to the correct diagnoses.

They then selected and recorded the three diagnoses that were ranked most prominently and seemed to fit the symptoms and signs, and compared the results with the correct diagnoses as published in the journal.

Google searches found the correct diagnosis in 15 (58%) of cases.

The authors suggest that Google is likely to be a useful aid for conditions with unique symptoms and signs that can easily be used as search terms. However, they stress that the efficiency of the search and the usefulness of the retrieved information depend on the searchers' knowledge base.

Doctors and patients are increasingly using the internet to search for health related information, and useful information on even the rarest medical syndromes can now be found and digested within a matter of minutes, say the authors.

To view the paper go to:
<http://press.psprings.co.uk/bmj/november/google.pdf>

Share your interesting stories or research in congenital cardiology

Submit a brief summary of your proposed article to Congenital Cardiology Today at
Article@CCT.bz

Manuscripts may be between 400-3,500 words, contain pictures, graphs and charts. Articles are typically published within 1-3 months of acceptance

MEDICAL SYMPOSIUMS AND MEETINGS

7th Annual International Symposium on Congenital Heart Disease

February 17-20, 2007; St. Petersburg, Florida USA

www.allkids.org/conferences

Cardiology 2007

February 21-25, 2007; Lake Buena Vista, Florida USA

www.chop.edu/cardiology2007/pdf/cardiology_07.pdf

Hands-on Cardiac Morphology

February 26-28, 2007; London, UK
<mailto:Morphology@rbht.nhs.uk>

Cardiology in Neonates and Infants 2007

March 1-2, 2007; London, UK
<mailto:Morphology@rbht.nhs.uk>

11th Vail Symposium on Pediatric Cardiac Diseases

March 4-6, 2007; Vail, CO USA
www.TheChildrensHospital.org

The 6th Interventional Workshop on Interventional Pediatric Cardiology

March 28-31 2007; San Donato, Italy
www.workshopIPC.com

OPBG Cardiovascular International Valvar Heart Disease in Children

April 18-20 2007; Rome, Italy
[Mailto:congressi@opbg.net](mailto:congressi@opbg.net)

SCAI 30th Annual Scientific Sessions

May 9-12 2007; Orlando, FL USA
www.scai.org

5th World Congress on Pediatric Cardiac Care

June 23-28, 2007; Geneva, Switzerland
www.pcc2007.com

ASE- 18th Annual Scientific Sessions (American Society of Echocardiography)

June 3-7, 2007; Seattle, WA USA
www.aescho.org

© 2007 by Congenital Cardiology Today
(ISSN 1554-7787-print; ISSN 1554-0499-online)
Published monthly. All rights reserved

Publishing Management

Tony Carlson, Founder & Editor

TCarlsonmd@gmail.com

Richard Koulbanis, Publisher & Editor-in-Chief

RichardK@CCT.bz

John W. Moore, MD, MPH, Medical Editor/
Editorial Board

JMoore@CHSD.org

Jeffrey Green, Contributing Editor

Editorial Board

Teiji Akagi, MD

Zohair Al Halees, MD

Mazen Alwi, MD

Felix Berger, MD

Fadi Bitar, MD

Jacek Bialkowski, MD

Philipp Bonhoeffer, MD

Anthony C. Chang, MD, MBA

John P. Cheatham, MD

Bharat Dalvi, MD, MBBS, DM

Horacio Faella, MD

Yun-Ching Fu, MD

Felipe Heusser, MD

Ziyad M. Hijazi, MD, MPH

Ralf Holzer, MD

Marshall Jacobs, MD

R. Krishna Kumar, MD, DM, MBBS

Gerald Ross Marx, MD

Tarek S. Momenah, MBBS, DCH

Toshio Nakanishi, MD, PhD

Carlos A. C. Pedra, MD

Daniel Penny, MD

James C. Perry, MD

Shakeel A. Qureshi, MD

Andrew Redington, MD

Carlos E. Ruiz, MD, PhD

Girish S. Shirali, MD

Horst Sievert, MD

Hideshi Tomita, MD

Gil Wernovsky, MD

Zhuoming Xu, MD, PhD

William C. L. Yip, MD

Carlos Zabal, MD

To Contact an Editorial Board Member

Email to: BOARD@CCT.bz. Place the Board Member's name in the Subject line.

FREE Subscription

Congenital Cardiology Today is available free to qualified professionals worldwide in pediatric and congenital cardiology. International editions available in electronic PDF file only; North American edition available in print. Send an email to Subs@CCT.bz. Be sure to include your name, title, organization, address, phone, fax and email.

Contacts and Other Information

For detailed information on author submission, sponsorships, editorial, production and sales contact, current and back issues, see website:
www.CongenitalCardiologyToday.com



In support of infants, children and teens with pediatric cardiomyopathy

CHILDREN'S CARDIOMYOPATHY FOUNDATION

P.O. Box 547, Tenafly, NJ 07670

Tel: 201-227-8852 info@childrenscardiomyopathy.org www.childrenscardiomyopathy.org

"A Cause For Today.... A Cure For Tomorrow"

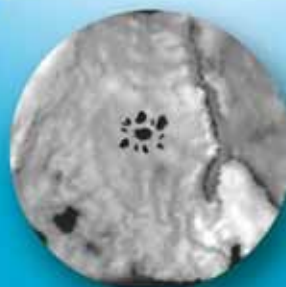

AMPLATZER®

"Cribriform" Septal Occluder

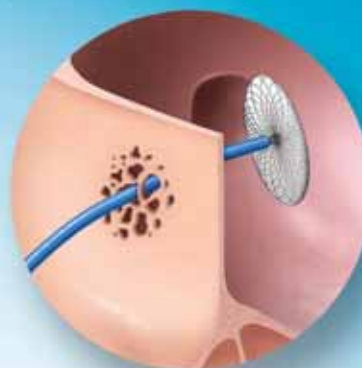
A Single Solution for Multi-Fenestrated Atrial Septal Defects

- **Narrow waist for atraumatic placement**
- **Broad contact surface to occlude multiple fenestrations with one device**
- **Can be recaptured and repositioned prior to release**

The AMPLATZER® Cribriform Septal Occluder complements AGA Medical Corporation's line of ASD Occlusion Systems, the most comprehensive line of transcatheter closure solutions available for treating atrial septal defects.



Multi-fenestrated atrial septal defect.



The AMPLATZER Cribriform Occluder enables closure of multiple fenestrations with a single device.

For More Information:
Call: 888-546-4407 (toll-free, US)
Visit: www.amplatzer.com



**AGA Medical
CORPORATION**

© AGA Medical Corporation 2007. Amplatzer is a registered trademark of AGA Medical Corporation. Not in any way connected with medical gas or equipment sold under the "AGA" brand by AGA AB or its successors.