

CONGENITAL CARDIOLOGY TODAY

Timely News and Information for BC/BE Congenital/Structural Cardiologists and Surgeons

September 2017; Volume 15; Issue 9
International Edition

IN THIS ISSUE

Right Aortic Arch with Coarctation and Large Diverticulum of Kommerell

By Erin Sukhu, MD; Casey Sams, MD;
Jennifer KE Whitham, MD, MSCR
~Page 1

Medical Meetings

~Page 5

e-Book Review: Perinatal Cardiology: A Multidisciplinary Approach

By John W. Moore, MD
~Page 6

Frontiers in Fontain Failure 2017

By Camden Hebson, MD; Fred Rodriguez, MD; Michael E. McConnell, MD
~Page 7

Medical News, Products & Information

~Page 11

Right Aortic Arch with Coarctation and Large Diverticulum of Kommerell

By Erin Sukhu, MD; Casey Sams, MD;
Jennifer KE Whitham, MD, MSCR

Key Words: Coarctation of the aorta, right aortic arch, hypoplastic aortic arch, aberrant left subclavian artery, atretic aortic arch, vascular ring, double aortic arch

Case Report

The patient is a 2-year-old ex-term male with normal growth, development, activity, and appetite, initially presenting to the Cardiac Clinic for evaluation of a murmur. The murmur was noted at his 9-month well child check and had persisted. He had intermittent stridor and difficulties swallowing certain textures, but there were no other medical concerns or problems according to the family. In clinic, a Grade II-III/VI systolic ejection murmur was noted at the apex and the left sternal border, along with diminished lower extremity pulses and a blood pressure exceeding the 99th percentile for age, sex, and height. There were no other abnormalities on exam, and no difference between upper and lower extremity blood pressures.

A 12-lead electrocardiogram revealed normal sinus rhythm. A transthoracic 2D echocardiogram revealed a moderate discrete coarctation of the aorta, with retrograde diastolic flow in the descending aorta and a peak systolic, descending, aorta gradient of 66 mmHg. Aortic arch sidedness was unable to be determined.

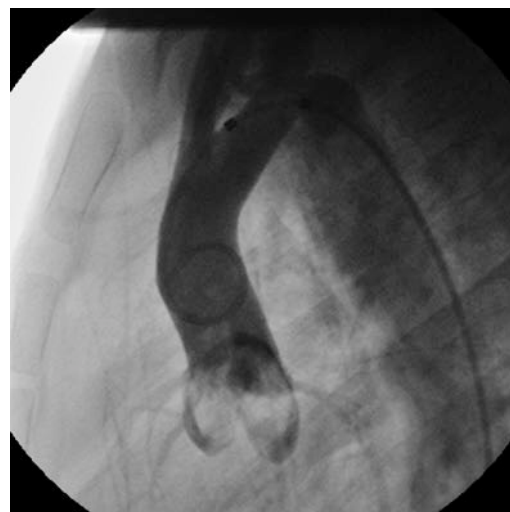

Figure 1. Aortic root angiogram outlining the aorta in a lateral projection, as well as the hypoplastic segment of the transverse aortic arch with coarctation of the aorta.

The patient subsequently underwent a chest MRA (MR angiography) to further evaluate the extent of the coarctation of the aorta and vascular anatomy. Imaging was performed on a 1.5 Tesla Siemens MR Scanner (Avanto Jr, Germany) using 4ml of Dotarem IV contrast. Image post-processing was performed using CVI 42 software. This study revealed a dominant, right aortic arch with a severely hypoplastic, transverse aortic arch segment between the origins of the right carotid and right subclavian artery, measuring 5.7mm. The first vessel off the right aortic arch was the left common carotid. There was a large diverticulum of Kommerell from which an aberrant left

CONGENITAL CARDIOLOGY TODAY

CALL FOR CASES AND OTHER ORIGINAL ARTICLES

Do you have interesting research results, observations, human interest stories, reports of meetings, etc. to share? Submit your manuscript to: RichardK@CCT.bz

CONGENITAL CARDIOLOGY TODAY

Editorial and Subscription Offices
16 Cove Rd, Ste. 200
Westerly, RI 02891 USA
www.CongenitalCardiologyToday.com

Follow on Twitter @CCardiology

KINGSTON

FREELANCE CONSULTING

WE OFFER...

- Business Development
- Clinical Planning & Research
- Clinical Study Development
- Concept Development
- Coordination of Testing
- Design & Development
- Design Requirements
- Expert Assistance
- FDA Liaison
- Feasibility Evaluation
- Functional & Performance Studies
- Internal Compliance Audits
- Manage All Activities Related to Regulatory Approval & Compliance.
- Market Assessment (Global)
- Pre-Submission Meetings
- Post-Market Surveillance
- Project Management
- Risk Analysis & Management
- Risk-Benefit Analysis
- Report Writing
- Strategic Project Planning
- Supplier Audits

ARE YOU:

- + **LEADING AN EARLY STAGE PRIVATELY HELD HEALTHCARE ORGANIZATION?**
- + **A LARGE MULTINATIONAL ORGANIZATION?**

If you answered "Yes," then you need a partner who understands your needs, and can effectively navigate and manage the challenges and risks associated with leading the priorities of managing your device through regulatory requirements, clinical trial conduction, downstream and upstream marketing activities to get your product launched on the market within your timeline and representing your vision.



❖ AMBER KINGSTON ❖
2305 WOODMONT CIRCLE
STE. K
MACUNGIE, PA 18062
TEL: 610.463.4964

AKKINGSTON@ICLOUD.COM

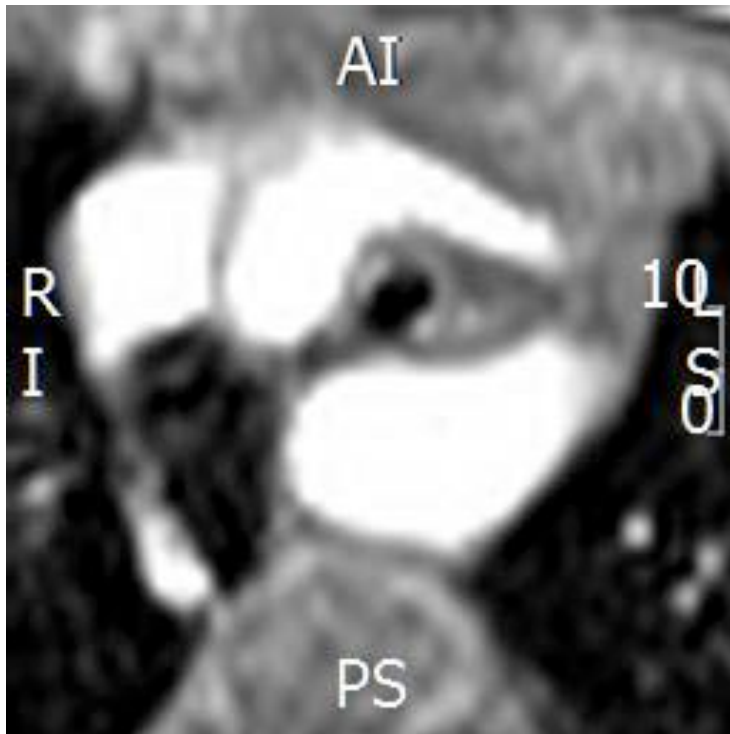


Figure 2. CMR Bright blood axial image showing the right aortic arch with a large diverticulum of Kommerell and the take-off of the aberrant left subclavian artery. Also noted is the posterior narrowing of the distal trachea.

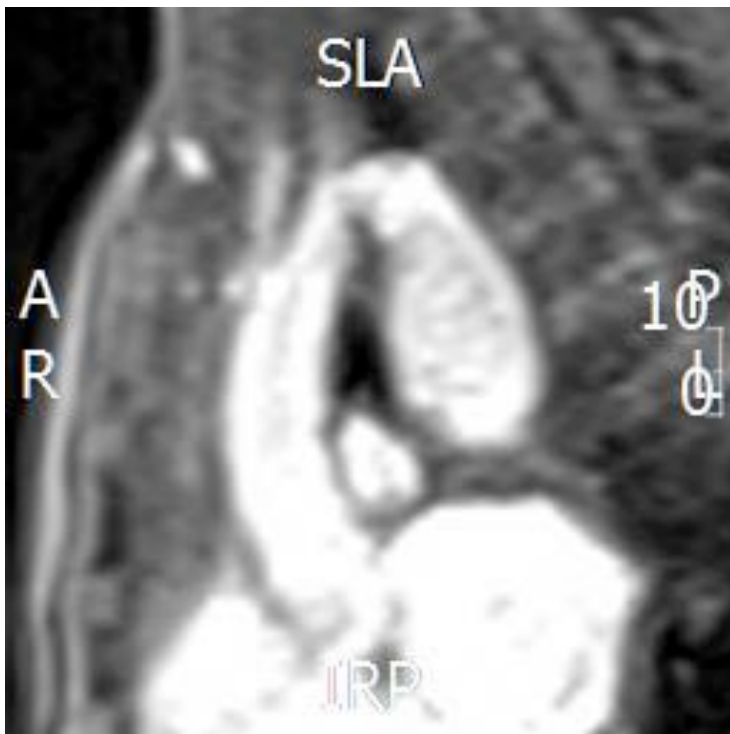


Figure 3. CMR Bright blood sagittal image showing a severe coarctation of the aorta with a large dilated Diverticulum of Kommerell.

subclavian artery arose; there was also a likely atretic left arch creating a vascular ring, leading to narrowing of the airway and

trachea and mild proximal dilatation of the esophagus. The descending thoracic aorta was tortuous to the right side of the spine and moderately dilated until the level of the diaphragm, when it became more normal in caliber. The trachea was severely narrowed, measuring 5mm, at the level of the large diverticulum of Kommerell and presumed ligamentum arteriosum stretching from the left subclavian artery to the left pulmonary artery. There was mild proximal dilatation of the esophagus.

The patient subsequently underwent cardiac catheterization to further define and confirm his aortic arch anatomy prior to surgical correction. The angiograms showed a right aortic arch with an aberrant left subclavian artery and large diverticulum of Kommerell. There was a moderate degree of narrowing, measuring 5mm, at the apex of the right arch. The gradient across the right aortic arch was 25mmHg. The patient then underwent surgical repair of vascular ring and patch aortoplasty of the right aortic arch.

Discussion

The development of the aorta begins in the 3rd week of gestation and proceeds through the formation of six pairs of primitive aortic arches between the ventral and dorsal primitive aortae.¹ The primitive arches are not all present at the same time, but appear and regress one after another, so that the mature system is formed when some of these primitive arches regress and others persist.² The development process is complex and depends upon the appropriate development and regression of the aforementioned structures, leaving ample opportunity for errors in development and for aortic arch anomalies to form.

There are numerous aortic arch anomalies that have been described, related to the position or branching of the aortic arch, or whether the arch is narrowed, hypoplastic, or atretic.¹ The most common type of aortic arch anomaly is a left-sided arch with aberrant right subclavian, followed by a right-sided arch with aberrant left subclavian, a right-sided arch with mirror image branching, and finally, by a double aortic arch anomaly.¹ Aortic arch anomalies can have a wide range of causes and associations, including: Congenital Heart Disease (50%), chromosomal abnormalities (24%), and vascular rings.^{1,2,3} Aortic arch anomalies occur in 1%-2% of the general population, so it is important to identify them, characterize their anatomy appropriately, and to be able to properly treat them.¹ As seen in our case, a right aortic arch with aberrant left subclavian artery is the most common type of vascular ring with a right aortic arch. The most common associated congenital heart defect associated with this arch anatomy is a Ventricular Septal Defect (VSD) However, it is unusual to have a right aortic arch with a coarctation of the aorta.⁴

Historically, though post-natal echocardiogram was the preferred method of diagnosis of aortic arch abnormalities, increasingly these anomalies are picked-up on fetal echocardiogram.^{3,5} The major problem with echocardiography, however, whether it be pre- or post-natal, is its limited ability to image the atretic aortic arch and/or ligamentum arteriosum.⁶ Computerized tomography and Magnetic Resonance Imaging (MRI) modalities are now leading the way for more precisely-defined cardiac and aortic anatomy, as well as being able to provide the arterial branching pattern and locations of any airway and/or esophageal obstructions.⁶ These non-invasive imaging techniques can therefore, accurately diagnose and characterize vascular rings as well, largely eliminating the need for catheter angiography and barium esophagrams.² In this case in particular, the magnetic resonance angiography was critical in anatomic mapping for appropriate surgical planning when echocardiogram failed to yield clear details.

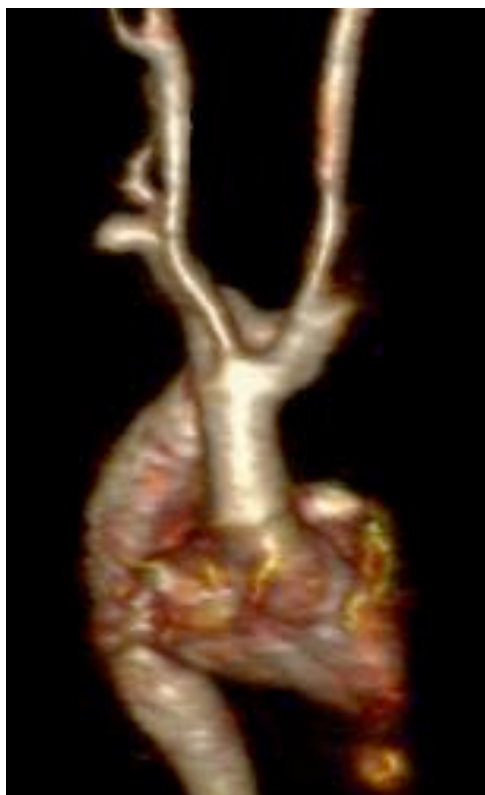

Figure 4. 3D reconstructed image showing the LV, Ascending Aorta, and outlining very tortuous path of the aorta as it traverses rightward and then swings over to the left.

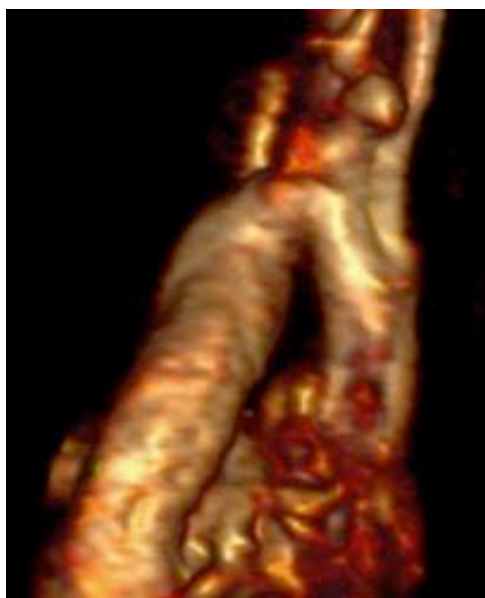


Figure 5. 3D reconstructed image showing the hypoplasia of the ascending and proximal transverse aorta with the severe coarctation of the aorta and dilated diverticulum of Kommerell (viewing from right side of patient to left side).

In a study from 2006, the Children's Hospital of Philadelphia presented a case

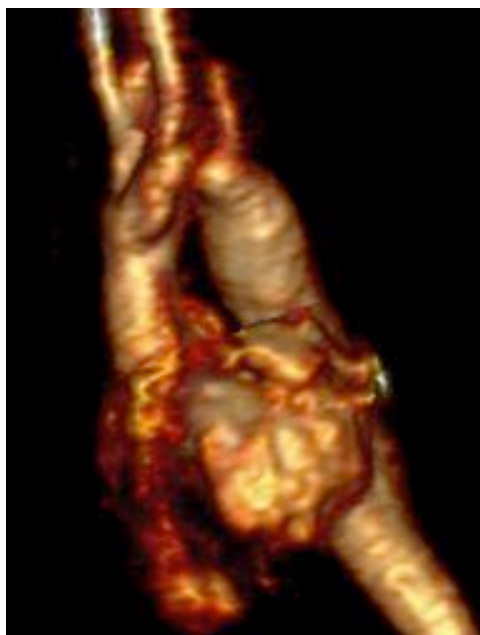

Figure 6. 3D reconstructed image showing the take-off of the left common carotid artery and the aberrant left subclavian artery from the large diverticulum of Kommerell.

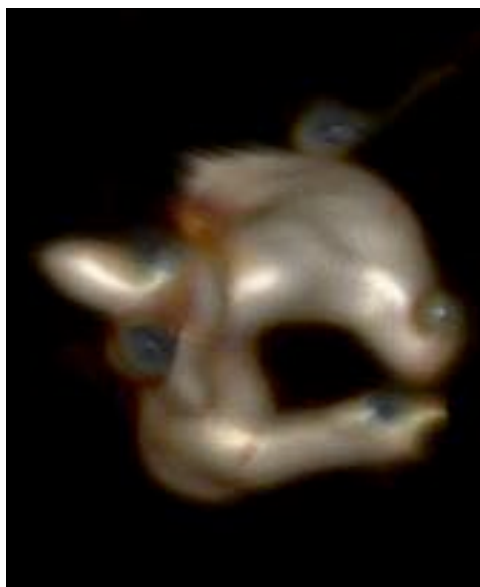


Figure 7. Axial view of 3D reconstructed image showing the right aortic arch with the aberrant left subclavian artery coming in close proximity to the take off of the left carotid artery.

review from 1988 to 2001, where 4.1% of its patients diagnosed with a right aortic arch also had a coarctation of the aorta.⁴ Ninety percent of these patients had long segment hypoplasia and 60% had an aberrant left subclavian artery with a retroesophageal diverticulum.⁴ No patients had a bicuspid aortic valve, and almost half of the patients also had some type of genetic syndrome.⁴ This is the largest

study to-date of right aortic arches with coarctation of the aorta. There have been other rare isolated case reports described since the 1960s.

A symptomatic vascular ring can cause wheeze, tachypnea, feeding difficulties, emesis, choking, or dysphagia, related to vascular compression of the airway and esophagus.^{2,5} Earlier repair has a more favorable long-term prognosis, so prompt and accurate detection, characterization, and intervention are necessary to prevent long-term morbidity and residual symptoms.³ As the study from 2006 suggests, our case report highlights the superior imaging quality provided by magnetic resonance imaging compared to echocardiography or angiography. With the addition of 3D reconstruction, the specific anatomical detail and resolution specifies the exact location of vascular obstruction and airway compression, necessary for effective surgical repair.

“With the addition of 3D reconstruction, the specific anatomical detail and resolution specifies the exact location of vascular obstruction and airway compression, necessary for effective surgical repair.”

References

1. Bravo, Coral et al. “Fetal Aortic Arch Anomalies”. J Ultrasound Med 35 (2016): 237-251. Print.
2. Hanneman, Kate, Beverley Newman, and Frandics Chan. “Congenital Variants and Anomalies of the Aortic Arch”. RadioGraphics 37(2017):32-51. Print.
3. Hunter, L et al. “Prenatal Echocardiographic Diagnosis of Double Aortic Arch”. Ultrasound Obstet Gynecol 45 (2015): 483-485. Print.
4. Ismat, Fraz A, et al. “Right Aortic Arch and Coarctation: A Rare Association.” Congenit Heart Dis 2006 Sep; 1(5): 217-223. Print.
5. Evans, William et al. “Vascular Ring Diagnosis and Management: Notable Trends Over 25 Years”. World Journal for Pediatrics and Congenital Heart Surgery 7.6 (2016): 717-720. Print.
6. Liang, Yiwu, Qiwen Zhou, and Ziyang Chen. “Double Aortic Arch With Ascending Aortic Aneurysm and Aortic Valve

Brief Biographical Sketch of Principal Author:

Dr. Sukhu is originally from Loudoun County, Virginia. She earned a B.Sc. in Chemistry with distinction from the University of Virginia, then after a year of serving as a substitute teacher, returned to the University of Virginia where she earned her MD. She went on to complete her pediatrics training at the University of North Carolina in 2017. She is now transitioning into outpatient general pediatrics and will be working at Raleigh Pediatrics in Garner, North Carolina.

Corresponding Author



Erin Sukhu, MD
Department of Pediatrics
University of North Carolina School of Medicine

erinebaugh@gmail.com

Mailing address:

Dr. Erin Sukhu
1111 Queensbury Circle
Durham, NC 27713 USA

Casey Sams, MD
Department of Diagnostic Imaging
Warren Alpert Medical School of Brown University
Providence, RI USA

Jennifer KE Whitham, MD, MSCR
Department of Pediatrics
University of North Carolina School of Medicine
Durham, NC USA

CONGENITAL CARDIOLOGY TODAY

CALL FOR CASES AND OTHER ORIGINAL ARTICLES

Do you have interesting research results, observations, human interest stories, reports of meetings, etc. to share?

Submit your manuscript to:
RichardK@CCT.bz

- Title page should contain a brief title and full names of all authors, their professional degrees, and their institutional affiliations. The principal author should be identified as the first author. Contact information for the principal author including phone number, fax number, email address, and mailing address should be included.
- Optionally, a picture of the author(s) may be submitted.
- No abstract should be submitted.
- The main text of the article should be written in informal style using correct English. The final manuscript may be between 400-4,000 words, and contain pictures, graphs, charts and tables. Accepted manuscripts will be published within 1-3 months of receipt. Abbreviations which are commonplace in pediatric cardiology or in the lay literature may be used.
- Comprehensive references are not required. We recommend that you provide only the most important and relevant references using the standard format.
- Figures should be submitted separately as individual separate electronic files. Numbered figure captions should be included in the main Word file after the references. Captions should be brief.
- Only articles that have not been published previously will be considered for publication.
- Published articles become the property of the Congenital Cardiology Today and may not be published, copied or reproduced elsewhere without permission from Congenital Cardiology Today.
- Please be sure any patient information such as name is removed from all figures

MEDICAL MEETINGS

27th International ACHD Advanced Symposium, 2017

Sep. 14-16, 2017; Cincinnati, OH USA
cincinnatichildrens.org/service/a/
congenital-heart/achd-annual-symposium

50th Anniversary Southeast Pediatric Cardiovascular Society Conference

Sep. 28-30, 2017; Atlanta, GA USA
choa.org/medical-professionals/
professional-events/50th-anniversary-southeast-pediatric-cardiovascular-society-meeting

11th IPC Workshop

Sep. 28-30, 2017; Milan, Italy
www.workshopipc.com/main.php

Frontiers in Fontan Failure: Innovation and Improving Outcomes

Oct. 1, 2017; Atlanta, GA USA
https://choa.org/medical-professionals/
professional-events/frontiers-in-fontan-failure-innovation-and-improving-outcomes

33rd Annual Echocardiography in Pediatric and Adult Congenital Heart Disease Symposium

Oct. 8-11, 2017; Rochester, MN USA
cveducation.mayo.edu/marketing/
echocardiography-in-pediatric-and-adult-congenital-heart-disease-case-studies--2#overview

LAA - How to close the Left Atrial Appendage

Nov. 17-18, 2017; Frankfurt, Germany
www.csi-congress.org/laa-workshop.php?go=0

CSI Africa

Dec. 1-2, 2017; Nairobi, Kenya
www.csi-congress.org/csi-africa.php?go=0

Device Therapies for Heart Failure

Dec. 15-16, 2017; Berlin, Germany
www.csi-congress.org/dhf.php?go=0



International Workshop
on Interventional Pediatric
and Adult Congenital Cardiology

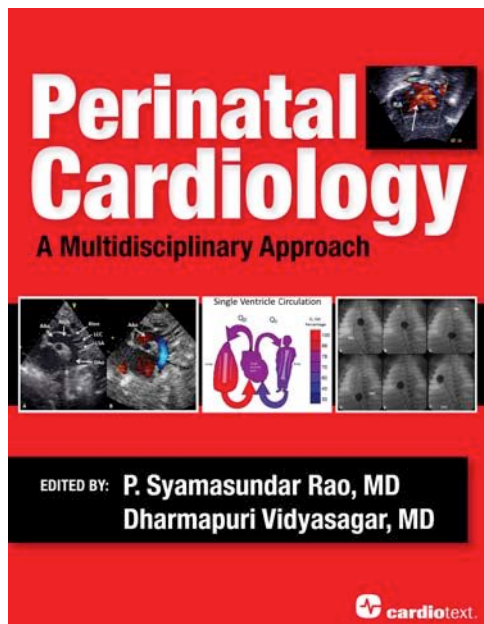
September
28th-30th 2017

Crowne Plaza Linate



e-Book Review: Perinatal Cardiology: A Multidisciplinary Approach

By John W. Moore, MD, MPH



"Perinatal Cardiology: A Multidisciplinary Approach," Edited by: P. Syamasundar Rao, MD, DCH, FAAP, FACC, FSCAI; University of Texas Medical School at Houston, Children's Memorial Hermann Hospital, Houston, Texas and Dharmapuri Vidyasagar, MD, MSc, FAAP, FCCM, PhD (Hon), University of Illinois at Chicago, Chicago, Illinois.

In the current era, paper textbooks have literally been placed on the "back shelf." Doctors Rao and Vidyasagar clearly understand this. They have edited an e-book, which is available to purchase and download from Cardiotext Publishing in Minneapolis, Minnesota (<https://cardiotextpublishing.com/perinatal-cardiology>). You can also get additional detail on the chapters and the authors.

In present day practice, Perinatal Cardiology has itself become a distinct medical discipline. Nearly all infants born with Complex Congenital Heart Disease in the United States have been identified as fetuses. Their parents have been counseled, and plans for comprehensive care starting at the time of fetal diagnosis, through delivery and the neonatal period have been made. Often plans include neonatal cardiac surgery and/or cardiac intervention. The success of these cardiac treatments often depend on optimal care of the fetus, timely and controlled delivery and resuscitation of the infant, and optimal stabilization and critical care of the infant prior to cardiac treatments.

Doctors Rao and Vidyasagar have edited and authored a comprehensive and detailed text on all aspects of perinatal cardiology.

In the Forward, Rao and Vidyasagar identify three objectives of this e-book: First, to provide readers with an overview of advances in the disciplines of perinatology, neonatology, cardiology, and cardiac surgery with regard to early diagnosis and timely treatment options. In addition, readers will find discussions of the multidisciplinary approaches commonly employed today in managing infants with congenital cardiac lesions. Lastly, this book provides current evidence-based therapeutic approaches for treatment of the fetus and the newborn with congenital cardiac lesions.

The objectives are achieved in forty-four chapters, written by a variety of authors. However, it's fair to say that Doctor Rao himself has written or contributed to the majority of these chapters. That said, the chapters are wide ranging, covering such diverse topics as MRI and CT imaging and anesthesia, as well as common topics such as oximetry screening, and treatment of premature lung disease and the PDA. In addition, there are detailed chapters on each of the individual congenital cardiac lesions (e.g. Truncus Arteriosus), as well as acquired problems such as cardiomyopathy.

My favorite chapter is on cardiac embryology. Always a complicated subject, Rao et. al. have succeeded in making this material understandable through clear and concise text and simple but complete diagrams.

I highly recommend this book. It is really all you need to be up-to-date on Perinatal Cardiology, and to manage your practice. Whether you are a pediatric cardiologist, a perinatologist, a neonatologist, or you are in training to be one of these specialists; this is a terrific reference and guide for you. If you are a cardiac or pediatric surgeon, this book will also be of interest to you because it covers the comprehensive care and management of your surgical patients.

Furthermore, the Editors and Staff of *Congenital Cardiology Today* and *Neonatology Today* are particularly pleased that Rao and Vidyasagar have selected many diagrams and figures from their previous publications in our newsletters to appear in the e-Book.

CCT

"I highly recommend this book. It is really all you need to be up-to-date on Perinatal Cardiology, and to manage your practice. Whether you are a pediatric cardiologist, a perinatologist, a neonatologist or you are in training to be one of these specialists; this is a terrific reference and guide for you. If you are a cardiac or pediatric surgeon, this book will also be of interest to you because it covers the comprehensive care and management of your surgical patients."

Corresponding Author



John W. Moore, MD, MPH
Medical Editor
Congenital Cardiology Today and
Neonatology Today

Professor of Pediatrics and Director
Division of Pediatric Cardiology
UC San Diego School of Medicine
3020 Children's Way, 1st Floor
Rose Pavilion
San Diego, CA 92123 USA

Tel: 858-966-5855
Fax: 858-571-7903

jmoore@rchsd.org

Frontiers in Fontan Failure 2017

By Camden Hebson, MD; Fred Rodriguez III, MD; Michael E. McConnell, MD

In 1992, Doctors Fontan and Kirklin published an article entitled "Outcome of the Perfect Fontan." The article ended with Dr. Fontan stating that the Fontan physiology "imposed a gradually declining functional capacity and premature late death after an initial period of often excellent palliation."¹ It is from this starting point, that *Frontiers in Fontan Failure 2017* will try to improve the outcome for patients who have Fontan palliation.

The proceedings of our first *Fontan Failure* meeting in 2015 were recently published.² This meeting covered numerous topics related to Fontan failure and patient management. While many different surgical options exist for patients with single ventricle physiology, the long-term outcome appears to be related to the physiology, more than to the specific surgical pathway. Twenty-year freedom from death exceeds 80%, but only 35% of Fontan survivors have event-free survival at 20 years. Embolization of the nearly ubiquitous venovenous collaterals seems to carry a higher mortality rate.

The topic of circulatory failure in the Fontan patient was discussed at length, and a system for dividing circulatory failure in Fontan patients into four categories was proposed. The first category was the patient with decreased systolic heart function, which results in both hepatic and pulmonary congestion. The systemic vascular resistance is typically high in these patients. This type of Fontan failure might be treated with conventional heart failure medications. The second type of failing Fontan patient has preserved systolic function, but a high ventricular-end diastolic pressure, also resulting in hepatic and pulmonary congestion. This category is caused by diastolic dysfunction. These patients may also have an elevated systemic vascular resistance, and may respond to afterload reduction, salt restriction, and diuretics. The third category involves patients with preserved systolic function, and a normal end-diastolic pressure, but still exhibit ascites and cirrhosis. These patients usually have preserved cardiac output, and a low systemic vascular resistance. Traditional heart failure medications such as ACE inhibitors can result in renal failure in patients with this physiology. The fourth category includes patients with protein losing enteropathy, and plastic bronchitis, and is termed lymphatic failure.

Medical therapy for treatment of Fontan failure has not been proven effective in published studies. Anticoagulation is indicated, but there is no clear-cut benefit of warfarin over aspirin. Beta blockers may have some usefulness in younger patients. Nonpharmacologic measures, including compression stockings, and exercise, may have long-term benefits.


Liver disease is ubiquitous in patients with single ventricle disease, and actually starts prior to Fontan palliation. Long-term complications including cirrhosis and hepatocellular carcinoma limit surgical options including heart transplantation. Immunization against hepatitis A and B, and treating hepatitis C are all important aspects of management. Limiting hepatotoxic medications and alcohol is important. Liver transplantation alone is not performed, due to of the cardiac physiology of the Fontan palliation. Heart transplantation may be considered in patients with Fontan associated liver disease, specifically in younger patients with advanced hepatic fibrosis, but who do not have signs of severe portal hypertension. Because of the complexity, heart-liver transplantation is infrequently performed at this time. For this reason, heart-liver transplantation as a solution for Fontan failure seems to be of limited value to the majority of patients. It can be life saving for the rare patient who is fortunate enough to qualify and survive the initial operation

"Medical therapy for treatment of Fontan failure has not been proven effective in published studies. Anticoagulation is indicated, but there is no clear-cut benefit of warfarin over aspirin. Beta blockers may have some usefulness in younger patients. Nonpharmacologic measures, including compression stockings, and exercise, may have long-term benefit."

Based on the recognition that some single ventricle patients can live into their eighth decade without surgical intervention, attempts to replicate this physiology in failing Fontan patients were discussed. At Emory, patients have undergone takedown of their Fontan to a Glenn shunt and an aortopulmonary source of blood flow. The results were mixed, with one patient developing heart failure because of excessive pulmonary blood flow from the aortopulmonary shunt, and subsequently having a Fontan procedure, and takedown of the aortopulmonary shunt. The second patient had shunt thrombosis secondary to mediastinitis, but is working full-time, in spite of severe desaturations. He has no evidence of progression of his liver disease. There have been two additional patients in whom replication of Kawashima physiology was performed, and both patients have chronic cyanosis, but no evidence of progression of their Fontan-associated Liver Disease. This type of approach was recently advocated in an article by Kutty, et al,³ where the authors stated, "if exposure of the liver to the more-adverse Fontan physiology could be delayed, perhaps this would slow the progression of liver disease. When functional status is satisfactory, the best approach may be to remain with a bi-caval pulmonary connection indefinitely, rather than to perform the Fontan operation simply because the patient has reached an age and size at which technical success is likely. An appropriate investigation would be to evaluate the feasibility of hepatic-exclusion Fontan techniques, which might channel the infrahepatic inferior vena cava blood to the lungs, while retaining the liver's venous drainage to the heart. If needed to prevent pulmonary arteriovenous fistula formation, hepatic factor could be supplied to the lungs with a small systemic-to-pulmonary-artery shunt, or even by creating an upper-extremity arteriovenous fistula."

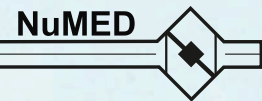Quality-of-life in patients with Fontan palliation is of great concern. As many as one third of these patients suffer anxiety or depression. The importance of end-of-life discussions was highlighted. Less than 10% of adult congenital physicians actually engage their Fontan patients in end-of-life management discussions prior to the patient's final admission to hospital. This is in contrast with the desire of over 80% of the patients to have such a discussion. The quality of life in cyanotic versus Fontan palliated patients was put into perspective by a physician and colleague who had a Fontan palliation at 8-years of age. He described at length how much better he felt after the Fontan palliation, and his improved exercise tolerance, and lack of shortness of breath. He also suggested that this improved status of his health might be worth losing some years of life at the end. However, he also admitted that were he to become a father, then

MAKING A DIFFERENCE



CP STENT™ UNMOUNTED OR PRE-MOUNTED ON A BIB® CATHETER
FOR TREATMENT OF COARCTATION OF THE AORTA

NIT-OCCLUD® PDA COIL SYSTEM
FOR TREATMENT OF PATENT DUCTUS ARTERIOSUS



INDICATIONS FOR USE:
The CP Stent® is indicated for use in the treatment of native and/or recurrent coarctation of the aorta involving a compliant aortic isthmus or first segment of the descending aorta where there is adequate size and Patency of at least one Femoral Artery and the balloon angioplasty is contraindicated or predicted to be ineffective. **WARNINGS / PRECAUTIONS:** Coarctation of the aorta involving the aortic isthmus or first segment of the descending aorta should be confirmed by diagnostic imaging. The CP stent has not been evaluated in patients weighing less than 20kg. As with any type of implant, infection secondary to contamination of the stent may lead to aortitis, or abscess. Over-stretching of the artery may result in rupture or aneurysm formation. Crimping the stent on a balloon catheter smaller than 12mm may cause damage to the stent. This device is intended for single use only. Do not resterilize and/or reuse it, as this can potentially result in compromised device performance and increased risk of cross-contamination. **CONTRAINDICATIONS:** Patients too small to allow safe delivery of the stent without compromise to the systemic artery used for delivery. Unfavorable aortic anatomy that does not dilate with high pressure balloon angioplasty. Curved vasculature. Occlusion or obstruction of systemic artery precluding delivery of the stent. Clinical or biological signs of infection. Active endocarditis. Known allergy to aspirin, other antiplatelet agents, or heparin. Pregnancy.

INDICATIONS FOR USE:
The Covered CP Stent® is indicated for use in the treatment of native and/or recurrent coarctation of the aorta involving the aortic isthmus or first segment of the descending aorta where there is adequate size and patency of at least one femoral artery associated with one or more of the following: Acute or chronic wall injury; Nearly atretic descending aorta of 3 mm or less in diameter; A non-compliant stenotic aortic segment found on pre-stent balloon dilation; A genetic or congenital syndrome associated with aortic wall weakening or ascending aortic aneurysm. **WARNINGS / PRECAUTIONS:** Coarctation of the aorta involving the aortic isthmus or first segment of the descending aorta should be confirmed by diagnostic imaging. The CP stent has not been evaluated in patients weighing less than 20kg. As with any type of implant, infection secondary to contamination of the stent may lead to aortitis, or abscess. Over-stretching of the artery may result in rupture or aneurysm formation. Crimping the stent on a balloon catheter smaller than 12mm may cause damage to the stent. Excessive handling and manipulation of the covering while crimping the stent may cause the covering to tear off of the stent. This device is intended for single use only. Do not resterilize and/or reuse it, as this can potentially result in compromised device performance and increased risk of cross-contamination. **CONTRAINDICATIONS:** Patients too small to allow safe delivery of the stent without compromise to the systemic artery used for delivery. Unfavorable aortic anatomy that does not dilate with high pressure balloon angioplasty. Curved vasculature. Occlusion or obstruction of systemic artery precluding delivery of the stent. Clinical or biological signs of infection. Active endocarditis. Known allergy to aspirin, other antiplatelet agents, or heparin. Pregnancy.

INDICATIONS FOR USE:
The Nit-Occlud® PDA coil is a permanently implanted prosthesis indicated for percutaneous, transcatheter closure of small to moderate size patent ductus arteriosus with a minimum angiographic diameter less than 4mm. Nit-Occlud Brief Statement: Do not implant the Nit-Occlud PDA into patients who have endocarditis, endarteritis, active infection, pulmonary hypertension (calculated PVR greater than 5 Wood Units), thrombus in a blood vessel through which access to the PDA must be obtained, thrombus in the vicinity of the implantation site at the time of the implantation or patients with a body weight < 11 lbs (5 kg). An angiogram must be performed prior to implantation for measuring length and diameter of the PDA. Only the pfm medical implantation delivery catheter should be used to implant the device. Administration of 50 units of heparin per kg body weight should be injected after femoral sheaths are placed. Antibiotics should be given before (1 dose) and after implantation (2 doses) in order to prevent infection during the implant procedure. Do not implant the Nit-Occlud PDA in an MR environment. Do not pull the Nit-Occlud coil through heart valves or ventricular chambers. Contrast media should not be injected through the implantation catheter. The catheter must not be connected to high pressure injectors. Patients may have an allergic response to this device due to small amounts of nickel that has been shown to be released from the device in very small amounts. If the patient experiences allergic symptoms, such as difficulty in breathing or swelling of the face or throat, he/she should be instructed to seek medical assistance immediately. Antibiotic prophylaxis should be performed to prevent infective endocarditis during first 6 months after coil implantation. Potential Adverse Events: Air embolism, Allergic reaction to drug/contrast, Apnea, Arrhythmia requiring medical treatment or pacing, Arteriovenous fistula, Bacterial endocarditis, Blood loss requiring transfusion, Chest pain, Damage to the tricuspid or pulmonary valves, Death, Embolization of the occluder, requiring percutaneous or surgical intervention, Endarteritis, False aneurysm of the femoral artery, Fever, Headache/migraine, Heart failure, Hemolysis after implantation of the occluder, Hypertension, Hypotension or shock, Infection, Myocardial infarction, Occluder fracture or damage, Perforation of the heart or blood vessels, Stenosis of the left pulmonary artery or descending thoracic aorta, Stroke/TIA, Thromboembolism (cerebral or pulmonary), Valvular Regurgitation, Vessel damage at the site of groin puncture (loss of pulse hematoma, etc.).

Refer to the Instructions for Use for complete indications, relevant warnings, precautions, complications, and contraindications.

CP Stent is a trademark of NuMED, Inc. BIB is a registered trademark of NuMED, Inc. Nit-Occlud is a registered trademark of pfm medical, Inc.

Rx only CV9058 - 9/16 ©2016 B. Braun Interventional Systems Inc.



Distributed by:

B. Braun Interventional Systems Inc. | 824 Twelfth Avenue | Bethlehem, PA 18018 USA
Tel 877 836 2228 | Fax 610 849 1334 | www.bisusa.org

perhaps doing anything to lengthen the number of years he could be with his family might outweigh the improved feeling after the Fontan operation. With this in mind, it is possible that a management strategy that involves a Glenn shunt, followed by a Fontan procedure when the patient's cyanosis was significantly debilitating, followed by some type of Fontan takedown prior to end-stage cirrhosis might be a strategy for both preserving the quality and quantity-of-life.

As single ventricle patients palliated with a Fontan operation continue to increase in number, issues discussed above will become more and more prevalent. It is imperative for the medical community to improve the long-term outlook for these patients. We must recognize the problems that our patients will have, and discover solutions to address these problems. It is with these goals in mind that our conference will begin on October 1, 2017 in Atlanta. We hope you will join us. For meeting information go to: <https://choa.org/medical-professionals/professional-events/frontiers-in-fontan-failure-innovation-and-improving-outcomes>.

References

1. Fontan F, Kirklin JW, Fernandez G et al. Outcome after a "Perfect" Fontan Operation. *Circulation* 1990 81. 1520-1536.
2. Hebson C, Book W, Elder RW, et al. Frontiers in Fontan failure: A summary of conference proceedings. *Congenit Heart Dis* 2007; 12(1):6-16.
3. Kutty SS, Zhang M, Danford D, et al. Hepatic Stiffness in the Bi-directional Cavopulmonary Circulation: The Liver Adult-Pediatric-Congenital-Heart-Disease Dysfunction Study Group. *JTCVS* 2016;151. 678-684.

CCT

Corresponding Author

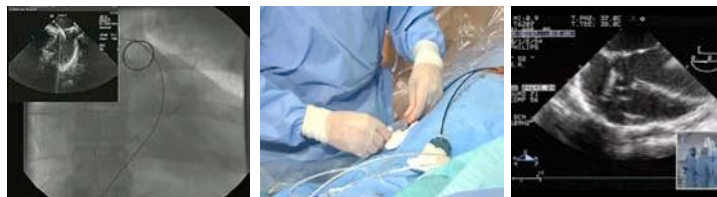Camden Hebson, MD
Assistant Professor of Pediatrics & Medicine
Divisions of Pediatric Cardiology and Cardiology
Emory University School of Medicine
1365 Clifton Rd NE, Bldg A
Atlanta, GA 30322 USA
Tel: 404-256-2593; Fax: 800-542-2233
hebsonc@kidsheart.com

Fred H. Rodriguez III, MD.
Assistant Professor of Pediatrics & Medicine
Divisions of Pediatric Cardiology and Cardiology
Emory University School of Medicine
Sibley Heart Center Cardiology
Atlanta, GA 30322 USA

Michael E. McConnell, MD
Associate Professor of Pediatrics & Medicine
Divisions of Pediatric Cardiology and Medicine
Emory University School of Medicine
Sibley Heart Center
Atlanta, GA 30322 USA

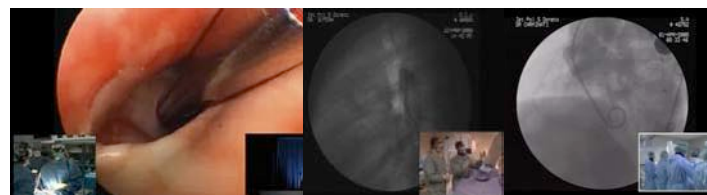
Watch over 300 Live Case Videos, Presentations and Workshops Online from Leading Congenital and Structural Medical Meetings from Around the World

www.CHDLiveCases.com



- Transseptal Access Workshop from Cook Medical
- Workshop: Past Present and Future of Pediatric Interventions Cardiology - St. Jude & AGA Medical
- Symposium on Prevention of Stroke Clinical Trials at the Heart of the Matter - WL Gore Medical
- Imaging in Congenital & Structural Cardiovascular Interventional Therapies
- Morphology of The Atrial Septum
- Morphology of The Ventricular Septum
- Pre-Selection of Patients of Pulmonic Valve Implantation and Post-Procedural Follow-up
- Echo Paravalvular Leakage (PVL)
- ICE vs TEE ASD Closure in Children - PRO & CON ICE
- 3D Rotational Angiography - Why Every Cath Lab Should Have This Modality
- PICS Doorway to the Past - Gateway to the Future
- Follow-up From PICS Live Cases 2010 Presentation
- Intended Intervention - Transcatheter TV Implantation - *Live Case*
- Intended Intervention - LAA Closure Using Amplatzer Cardiac Plug Under GA & Real Time 3D
- Provided Intervention - LPA Stenting / Implantation of a Sapien Valve
- Intended Intervention - PV Implantation
- Intended Intervention - COA Stent Using Atrium Advanta V12 Covered Stent - *Live Case*
- Intended Intervention - ASD Closure - *Live Case*
- Intended Intervention - Transcatheter VSD Device Closure - *Live Case*
- Intended Intervention - COA Stenting Using Premounted Advanta V12 Covered Sten - *Live Case*
- Stunning Revelation - The Medical System is Changing - What Can You Do To Show Patients That Your Practice Does It Right? Patient Perspective
- Percutaneous Paravalvular Leak Closure Outcomes
- Intensive Management of Critically Ill Infants Undergoing Catheterization
- and many more....

Presented by **CONGENITAL CARDIOLOGY TODAY**



Archiving Working Group
International Society for Nomenclature of
Paediatric and Congenital Heart Disease
ipccc-awg.net

Medical News, Products & Information

Compiled and Reviewed by Tony Carlson, Senior Editor

Abbott Leads Way in First Clinical Trial of Minimally Invasive Clip-Based Repair System for Leaky Tricuspid Heart Valves

In early August, Abbott announced that the first patient has been enrolled in a clinical study to evaluate a minimally invasive clip-based repair system for treating people with moderate or severe tricuspid regurgitation (TR), a common condition affecting the right side of the heart. The first patient was enrolled at Abbott Northwestern Hospital by Dr. Paul Sorajja, MD, cardiologist at Minneapolis Heart Institute and Abbott Northwestern Hospital.

The transcatheter tricuspid valve repair (TTVR) system builds upon more than a decade of development of Abbott's proven MitraClip System, which has shown to predictably and effectively treat mitral regurgitation, a similar disease impacting the left side of the heart.

Tricuspid regurgitation is a condition in which the valve between the heart's two chambers on the right side does not close properly, resulting in a backward flow of blood into the right atrium. The consequences of leaving it untreated can be substantial – people often develop other conditions such as: atrial fibrillation, heart failure and, ultimately, death. Currently, there are no approved minimally invasive treatments for people with moderate or severe tricuspid regurgitation.

"Current pharmacological and surgical treatment options are not meeting the needs of people living with tricuspid regurgitation," said Georg Nickenig, MD, PhD, Professor & Chief, Department of Cardiology, University Hospital, Bonn, Germany, and lead investigator of the study. "Abbott's MitraClip has shown positive results for mitral regurgitation, and we hope this study shows that a similar clip-based technology may effectively treat people with tricuspid regurgitation."

The trial is expected to support Abbott's application for CE Mark in Europe for a clip-based transcatheter tricuspid valve repair system.

"As a leader in structural heart therapies, Abbott is exploring new ways to treat people with heart valve diseases," said Charles Simonton, MD, Chief Medical Officer and Divisional Vice President, Global Medical Affairs, for Abbott's Vascular and Structural Heart Businesses. "The investigational medical device that will be used in this study builds on years of learnings and knowledge using our clip-based device for treating mitral regurgitation. We look forward to the results of the trial to determine if this new minimally invasive technology has the potential to benefit people living with tricuspid regurgitation just as predictably."

The study, called TRILUMINATE, is a prospective, single-arm, multi-center study designed to evaluate the performance of clip-based technology in approximately 75 symptomatic patients at 25 sites across the U.S. and Europe. The primary endpoints are an echocardiographic tricuspid regurgitation reduction of ≥ 1 grade at 30 days post-procedure, and the assessment of major adverse events at six months.

For important safety information on MitraClip, please visit: <https://mitraclip.com/isi>.

For more than 125 years, Abbott has brought new products and technologies to the world – in nutrition, diagnostics, medical devices and branded generic pharmaceuticals – that create more possibilities for more people at all stages of life. Connect with Abbott at www.abbott.com, on Facebook at www.facebook.com/Abbott and on Twitter @AbbottNews and @AbbottGlobal.

Large Scale Study: Outcomes for Long QT Syndrome Patients Treated at Specialty Center are Better

Newswise — ROCHESTER, Minn. — Sudden cardiac death, and episodes of fainting and seizures from Long QT Syndrome, are significantly lower than previously thought when patients are diagnosed and treated at a specialty center dedicated to the treatment of genetic heart rhythm diseases, according to Mayo Clinic research published in the *Journal of the American College of Cardiology*. This is one of the largest studies of Long QT Syndrome patients – people who have an inherited heart rhythm condition that can potentially cause fast and chaotic heartbeats – evaluated and treated at a single center to analyze these outcomes.

Results come from a retrospective study of 606 patients with long QT Syndrome evaluated at Mayo Clinic's Genetic Heart Rhythm Clinic from January 1999 to December 2015, and followed for an average of seven years. Patients' health records were analyzed to note how many experienced symptoms or died despite receiving treatment.

Researchers report that, despite a comparatively lower use of implantable defibrillators and a philosophy of shared decision-making that enables patients to remain active, only 50 patients experienced breakthrough cardiac events. These events are fainting or seizures, aborted cardiac arrest, appropriate implantable cardioverter defibrillator shocks, and sudden cardiac death. Of the 50 patients, two patients experienced sudden cardiac death, and three required a heart transplant. Overall, 92% of patients did not experience symptoms after they were treated for Long QT Syndrome, and results show the overall chance of sudden cardiac death was low.

"Although Long QT Syndrome is a potentially lethal syndrome, when it is recognized and treated, sudden death should almost never happen," says senior author Michael Ackerman, MD, PhD, Director of Mayo Clinic's Long QT Syndrome/Genetic Heart Rhythm Clinic. "The expectation needs to shift from merely preventing sudden death to enabling these patients and their families to live and thrive despite the diagnosis. Hopefully, the results of this study should be reassuring and encouraging to these families who live with Long QT Syndrome."

Though estimates suggest that Long QT Syndrome occurs in only one of every 2,000 people, it is one of the common causes of sudden cardiac death. "Because the disease is rare, it is challenging to study its outcomes," says Ram Rohatgi, MD, first author and Mayo Clinic Pediatric Cardiology Fellow. "Therefore, most of the previous studies had to combine data from multiple



PICS-AICS
Pediatric and Adult Interventional Cardiac Symposium

VEGAS
MGM GRAND LAS VEGAS
SEPTEMBER 5-8, 2018

www.picsymposium.com

institutions, and there could be variations in how patients were evaluated and treated at each center."

In addition, researchers found that the patients studied, compared to previous studies, had fewer symptoms before diagnosis. Researchers believe this may reflect the changing landscape for patients with Long QT Syndrome, potentially signaling that more patients may be diagnosed earlier due to availability of genetic testing and familial screening. "We think this early recognition of the diagnosis could be leading to earlier treatment and improved outcomes," Dr. Rohatgi says.

Co-authors — all from Mayo Clinic — are: Alan Sugrue, MB, BCh.; Johan Bos, MD, PhD; Bryan Cannon, MD; Samuel Asirvatham, MD; Christopher Moir, MD; Heidi Owen; Katy Bos; and Teresa Kruisselbrink.

Mayo Clinic is a nonprofit organization committed to clinical practice, education and research, providing expert, whole-person care to everyone who needs healing. For more information, visit newsnetwork.mayoclinic.org.

3-D Printed Models Could Improve Patient Outcomes in Heart Valve Replacements

Newswise — Heart valve models created with advanced 3-D printers could soon assist cardiologists in preparing to perform life-saving heart valve replacements.

Researchers at Georgia Institute of Technology and the Piedmont Heart Institute are using standard medical imaging and new 3-D printing technologies to create patient-specific heart valve models that mimic the physiological qualities of the real valves. Their aim is to improve the success rate of Transcatheter Aortic Valve Replacements (TAVR) by picking the right prosthetic and avoiding a common complication known as paravalvular leakage.

"Paravalvular leakage is an extremely important indicator in how well the patient will do long-term with their new valve," said Zhen Qian, Chief of Cardiovascular Imaging Research at Piedmont Heart Institute, which is part of Piedmont Healthcare. "The idea was, now that we can make a patient-specific model with this tissue-mimicking 3-D printing technology, we can test how the prosthetic valves interact with the 3-D printed models to learn whether we can predict leakage."

The researchers, whose study was published July 3rd in the journal *JACC: Cardiovascular Imaging*, found that the models, created from CT scans of the patients' hearts, behaved so similarly to the real ones that they could reliably predict the leakage.

"These 3-D printed valves have the potential to make a huge impact on patient care going forward," said Chuck Zhang, a professor in the Stewart School of Industrial and Systems Engineering at Georgia Tech.

Tens of thousands of patients each year are diagnosed with heart valve disease, and TAVR is often considered for patients who are at high-risk for complications with an open-heart surgery to replace the valve.

CONGENITAL CARDIOLOGY TODAY

We Can Help You

Recruit:*

- Pediatric Cardiologists
- Pediatric Interventional Cardiologist
- Adult Cardiologist focused on CHD
- Congenital/Structural Heart Surgeons
- Echocardiographers
- EPs
- Pediatric Transplant Cardiologist

*Reach over 6,000 BC/BE Cardiologists focused on CHD worldwide

Your Recruitment Advertising Includes:

- Full color Recruitment ad in the issue(s)
- Your recruitment listing in the email blast for the issue(s) with a hot link
- 3-Step Special Recruitment Opportunity Website Section in three (3) areas of the website
- *We can create your recruitment ad at no extra charge!*

For more Information Contact:

Tony Carlson

+1.301.279.2005 or

tcarlsonmd@gmail.com

CHIP NETWORK
CONGENITAL HEART INTERNATIONAL PROFESSIONALS

The congenital heart professionals network exists to facilitate communications between congenital heart professionals locally, regionally, and globally.

JOIN TODAY

www.chipnetwork.org

 Cincinnati
Children's
Heart Institute

Funded by Cincinnati Children's Heart Institute

The prosthetic valves are made in a variety of sizes from multiple manufacturers. Leakage occurs when the new valve doesn't achieve a precise fit and blood flows around the prosthetic, rather than through it as intended. Reducing the chances for leakage is key to patient outcome for the procedure.

"In preparing to conduct a valve replacement, interventional cardiologists already weigh a variety of clinical risk predictors, but our 3-D printed model gives us a quantitative method to evaluate how well a prosthetic valve fits the patient," Qian said.

The models are created with a special metamaterial design and then made by a multi-material 3-D printer, which gives the researchers control over such design parameters as diameter and curving wavelength of the metamaterial used for printing, to more closely mimic physiological properties of the tissue.

For example, the models can recreate conditions such as calcium deposition -- a common underlying factor of aortic stenosis -- as well as arterial wall stiffness and other unique aspects of a patient's heart.

"Previous methods of using 3-D printers and a single material to create human organ models were limited to the physiological properties of the material used," Zhang said. "Our method of creating these models using metamaterial design and multi-material 3-D printing takes into account the mechanical behavior of the heart valves, mimicking the natural strain-stiffening behavior of soft tissues that comes from the interaction between elastin and collagen, two proteins found in heart valves."

That interaction was simulated by embedding wavy, stiff microstructures into the softer material during the 3-D printing process.

The researchers created heart valve models from medical imaging of 18 patients who had undergone a valve replacement surgery. The models were outfitted with dozens of radiopaque beads to help measure the displacement of the tissue-mimicking material.

The researchers then paired those models with the same type and size prosthetic valves that interventional cardiologists had used during each patient's valve replacement procedure. Inside a warm-water testing environment controlled to maintain human body temperature, the researchers implanted the prosthetics inside the models, being careful to place the new valves in the exact location that was used during the clinical procedure for each case.

Software was used to analyze medical imaging showing the location of the radiopaque beads taken before and after the experiment to determine how the prosthetics interacted with the 3-D printed models, looking for inconsistencies representing areas where the prosthetic wasn't sealed well against the wall of the valve.

Those inconsistencies were assigned values that formed a "bulge index," and the researchers found that a higher bulge index was associated with patients who had experienced a higher degree of leakage after valve placement. In addition to predicting the occurrence of the leakage, the 3-D printed models were also able



Credit: Rob Felt

New 3-D printing technologies allow researchers to create patient-specific heart valve models that mimic the physiological qualities of the real valves. This image shows the inside where calcium deposits are recreated to create real patient conditions.

to replicate the location and severity of the complication during the experiments.

"The results of this study are quite encouraging," Qian said. "Even though this valve replacement procedure is quite mature, there are still cases where picking a different size prosthetic or different manufacturer could improve the outcome, and 3-D printing will be very helpful to determine which one."

While the researchers found that another variable - how much calcium had accumulated on the patient's natural valve -- could also predict with high accuracy whether there would be a higher degree of leakage, the new method using 3-D printed valves was a better predictor in certain cases where balloons are used during the procedure to expand the prosthetic valve for a better fit.

The researchers plan to continue to optimize the metamaterial design and 3-D printing process and evaluate the use of the 3-D printed valves as a pre-surgery planning tool, testing a larger number of patient-specific models and looking for ways to further refine their analytic tools.

"Eventually, once a patient has a CT scan, we could create a model, try different kinds of valves in there, and tell the physician which one might work best," Qian said. "We could even predict that a patient would probably have moderate paravalvular leakage, but a balloon dilatation will solve it."

CITATION: Zhen Qian, Kan Wang, Shizhen Liu, Xiao Zhou, Vivek Rajagopal, Christopher Meduri, James R. Kauten, Yung-Hang Chang, Changsheng Wu, Chuck Zhang, Ben Wang, Mani A.



27th International Symposium on Adult Congenital Heart Disease

Sep. 14-16, 2017 | Cincinnati, Ohio USA



www.cincinnatichildrens.org/ACHDsymposium

Vannan, "Quantitative Prediction of Paravalvular Leak in Transcatheter Aortic Valve Replacement Based on Tissue-Mimicking 3D Printing," JACC: Cardiovascular Imaging, (July 2017). doi:10.1016/j.jcmg.2017.04.005.

East Coast Pediatric Practice Enhances Digisonics System for Interoperability with 3rd Party Systems

In June, Pediatric Cardiology Associates in Syracuse, NY, streamlined their Digisonics Cardiovascular Information System by adding HL7 interfaces directly to their Allscripts EMR. Additionally, they added DICOM Modality Worklist to autopopulate the facility's imaging devices with a list of scheduled studies for workflow automation and improved accuracy by eliminating manual entry of patient data.

"We have used Digisonics for Pediatric Cardiology for more than 15 years. We have a busy lab as we read more than 7,000 studies per year and Digisonics has always provided great support for our team. Digisonics has been an excellent partner in helping us achieve the best patient care possible," said Matthew Egan, MD, FAAP, FACC.

Digisonics provides top-rated clinical image management and structured reporting systems for Cardiology (CVIS), Radiology, and Obstetrics & Gynecology. Digisonics structured reporting solutions combine high performance image review workstations, a powerful PACS image archive, an integrated clinical database, comprehensive analysis capabilities and highly configurable reporting for multiple modalities. Key applications are complemented with interfaces to information systems and third party vendors, providing facilities with a seamless, efficient clinical workflow.

For further information, please contact: www.digisonics.com.

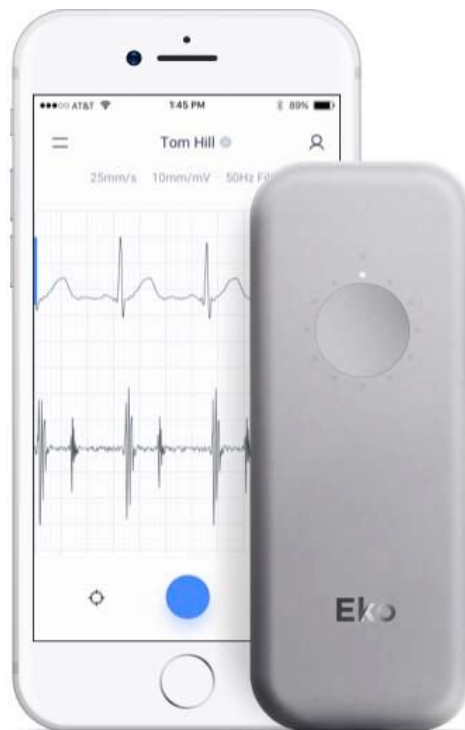New FDA-Cleared Smart Heart Monitor Keeps the Cardiologist a Heartbeat Away

Eko DUO is the first cardiac monitor to combine digital stethoscope and ECG technology for in-clinic and at-home monitoring, offering 28 million Heart Disease patients the ability to seamlessly send cardiac data to their physicians

In June, Eko Devices ("Eko"), the leader in mobile acoustic cardiac monitoring tools, has received FDA clearance to market its latest innovation, DUO, a combined digital stethoscope and electrocardiogram (ECG). The portable cardiac device was inspired by cardiologists' demand for more effective monitoring tools for heart disease the leading cause of death in the United States.

The marriage of ECG and digital stethoscope technology into a compact, handheld device offers unprecedented insight into cardiac function. Clinicians will use DUO as a cutting-edge screening tool or prescribe it to Heart Disease outpatients as the centerpiece of at-home health kits. The device wirelessly pairs with Ekos secure, HIPAA-compliant app, enabling remote monitoring and diagnosis by a clinician or specialist.

Eko DUOs consumer-friendly design can help transform how clinicians monitor heart health in-person or virtually, said Dr.



Credit: Eko Devices
DUO a combined digital stethoscope and electrocardiogram (ECG).

John Chorba, a Cardiologist and Assistant Professor at UC San Francisco. We need powerful tools that heart failure patients can use to improve self-care and communicate troubling findings with an expert.

DUO represents a shift in the fight against Heart Disease, empowering patients to use familiar smart tools under the remote supervision of their physician to navigate complex medical conditions and, ultimately, reduce unnecessary hospital readmissions. Studies reveal that 25% of heart failure patients are readmitted to the hospital within 30

days, and 50% are readmitted within six months. Heart failure costs the nation \$30.7 billion annually.

"Cardiology programs are looking for ways to deliver hospital-quality healthcare at home," said Dr. Ami Bhatt, Director of Outpatient Cardiology and the Adult Congenital Heart Disease Program at Massachusetts General Hospital. "The ability to capture digital heart sounds and an ECG expands our portfolio of mechanisms to remotely monitor the heart, and brings diagnosis and opportunities for early intervention even further upstream. Robust toolkits for caring for patients in the community will hopefully lead to more appropriate healthcare utilization through continuous rather than episodic outpatient care."

Following its vision to improve cardiovascular care, Eko is also developing machine-learning algorithms that can be combined with DUO to automatically alert patients and their care teams of suspected decline in cardiac function.

"Our mission is to make cardiac monitoring more accessible for patients and physicians, to ultimately reduce unnecessary readmissions, and reduce the excessive healthcare burden of Heart Disease," said Connor Landgraf, Co-Founder and CEO of Eko. "The launch of DUO and the upcoming decision-support algorithms are giant steps forward in patient empowerment and telemedicine. It's important to get this in the hands of the millions of heart disease patients who deserve better at-home monitoring tools."

CONGENITAL CARDIOLOGY TODAY

CALL FOR CASES AND OTHER ORIGINAL ARTICLES

Do you have interesting research results, observations, human interest stories, reports of meetings, etc. to share? Submit your manuscript to: RichardK@CCT.bz

Eko is building a platform of non-invasive auscultation and cardiac screening devices, care coordination software, and point-of-care machine learning algorithms that enables more effective screening and management of cardiovascular diseases. Founded in 2013, the company is paving the way for an era of non-invasive, mobile, and intelligent cardiac care.

The company's first device, Eko CORE, is a smart stethoscope and accompanying platform now used by clinicians at over 700 hospitals and health systems around the globe, and was recognized as a "Best Invention of the Year" by *TIME Magazine*. Eko's physician advisors include industry-leading cardiologists from: Massachusetts General Hospital, UCSF, and the Mayo Clinic, and venture capital investors include the founders of Shazam, the founder of Splunk, Stanford University's StartX Fund, and DreamIT Ventures.

Lab Led by Zhe Han, PhD, Receives \$1.75 Million from NIH to Continue Pioneering Research

The National Institutes of Health has awarded \$1.75 million to a research lab led by Zhe Han, PhD, Principal Investigator and Associate Professor in the Center for Genetic Medicine Research, in order to build models of Congenital Heart Disease (CHD) that are tailored to the unique genetic sequences of individual patients.

Han was the first researcher to create a *Drosophila melanogaster* model to efficiently study genes involved in CHD, the number one birth defect experienced by newborns, based on sequencing data from patients with the heart condition. While surgery can fix more than 90% of such heart defects, an ongoing challenge is how to contend with the remaining cases since mutations of a vast array of genes could trigger any individual CHD case.

In a landmark paper published in 2013 in the journal *Nature*, five different institutions sequenced the genomes of more than 300 patients with CHD and their families, identifying 200 mutated genes of interest.

"Even though mutations of these genes were identified from patients with CHD, these genes cannot be called 'CHD

genes', since we had no in vivo evidence to demonstrate these genes are involved in heart development," Han says. "A key question to be answered: How do we efficiently test a large number of candidate disease genes in an experimental model system?"

In early 2017, Han published a paper in *Elife* providing the answer to that lingering question. By silencing genes in a fly model of human CHD, the research team confirmed which genes play important roles in development. The largest group of genes that were validated in Han's study were histone-modifying genes. (DNA winds around the histone protein, like thread wrapped around a spool, to become packed into a higher-level structure.)

The new four-year NIH grant will enable Han to carry out the next stage of the detective work to determine precisely how histone-modifying genes regulate heart development. In order to do so, his group will silence the function of histone-modifying genes one-by-one, to study their function in the fly heart development, and to identify the key histone-modifying genes for heart development. And because patients with CHD can have more than one mutated gene, he will silence multiple genes simultaneously to determine how those genes work in partnership to cause heart development to go awry.

By the end of the four-year research project, Han hopes to be able to identify all of the histone-modified genes that play pivotal roles in development of the heart in order to use those genes to tailor make personalized fly models corresponding to individual patient's genetic makeup.

Parents with mutations linked to CHD are likely to pass heart disease risk to the next generation. One day, those parents could have an opportunity to sequence their genes to learn the degree of CHD risk their offspring face.

"Funding this type of basic research enables us to understand which genes are important for heart development and how. With this knowledge, in the near future we could predict the chances of a baby being born with CHD, and cure it by using gene-editing approaches to prevent passing disease to the next generation," Han says.

CONGENITAL CARDIOLOGY TODAY

© 2017 by Congenital Cardiology Today (ISSN 1554-7787-print; ISSN 1554-0499-online). Published monthly. All rights reserved.

www.CongenitalCardiologyToday.com

Publication Company Address:

11502 Elk Horn Dr. Ste. 201
Clarksburg, MD 20871 USA
Tel: +1.301.279.2005

Publishing Management:

- Tony Carlson, Founder, President & Sr. Editor - TCarlsonmd@gmail.com
- Richard Koulbanis, Group Publisher & Editor-in-Chief - RichardK@CCT.bz
- John W. Moore, MD, MPH, Group Medical Editor - JMoore@RCHSD.org
- Allan Berthe, Contributing Editor-Special Projects

Editorial Board:

Teiji Akagi, MD; Zohair Al Halees, MD; Mazeni Alwi, MD; Felix Berger, MD; Fadi Bitar, MD; Jacek Bialkowski, MD; Mario Carminati, MD; Anthony C. Chang, MD, MBA; John P. Cheatham, MD; Bharat Dalvi, MD, MBBS, DM; Horacio Faella, MD; Yun-Ching Fu, MD; Felipe Heusser, MD; Ziyad M. Hijazi, MD, MPH; Ralf Holzer, MD; Marshall Jacobs, MD; R. Krishna Kumar, MD, DM, MBBS; John Lamberti, MD; Gerald Ross Marx, MD; Tarek S. Momenah, MBBS, DCH; Toshio Nakanishi, MD, PhD; Carlos A. C. Pedra, MD; Daniel Penny, MD, PhD; James C. Perry, MD; P. Syamasundar Rao, MD; Shakeel A. Qureshi, MD; Andrew Redington, MD; Carlos E. Ruiz, MD, PhD; Girish S. Shirali, MD; Horst Sievert, MD; Hideshi Tomita, MD; Gil Wernovsky, MD; Zhuoming Xu, MD, PhD; William C. L. Yip, MD; Carlos Zabal, MD

Free Subscription to Qualified

Professionals: Send your name, title(s), hospital or practice name, work address and url, phone, fax and email to: sub@cct.bz.

Official publication of the CHiP Network

Statements or opinions expressed in Congenital Cardiology Today reflect the views of the authors and sponsors, and are not necessarily the views of Congenital Cardiology Today.

Master Class in Congenital Cardiac Morphology

With world renowned cardiac pathologist Professor Robert Anderson, MD, FRCPath

Oct. 11 to 13, 2017 • Children's Hospital of Pittsburgh of UPMC • Pittsburgh, PA

This activity has been approved for AMA PRA Category 1 Credit™ • The University of Pittsburgh is an affirmative action, equal opportunity institution.

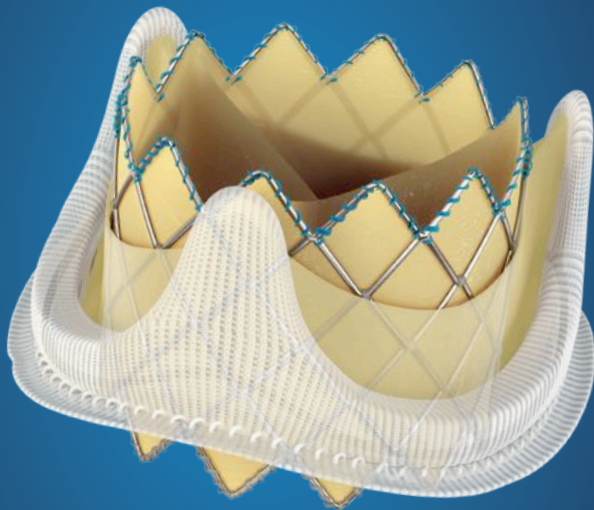
Learn more at www.chp.edu/MasterClassCCM



Children's
Hospital of Pittsburgh
of UPMC

CE MARK RECEIVED

FOR USE IN FAILED SURGICAL BIOPROSTHETIC PULMONARY VALVES



Melody™

Transcatheter Pulmonary
Valve (TPV) Therapy

**Reaching even
more patients
with Melody™ TPV**

- The first commercially available TPV
- A breakthrough non-surgical option to treat failing pulmonary valve conduits
- Has treated more than 11,000 patients globally over the last 10 years

Melody-TPV.com

Medtronic
Further, Together