

# CONGENITAL CARDIOLOGY TODAY

News and Information for Pediatric and Congenital Cardiovascular Physicians and Surgeons

Vol. 5 / Issue 2  
February 2007  
North American Edition

[WWW.CONGENITALCARDIOLOGYTODAY.COM](http://WWW.CONGENITALCARDIOLOGYTODAY.COM)

## INSIDE THIS ISSUE

### Transcatheter Completion of Fontan in Saudi Arabia

by Mashail Alobaidan, MD;  
Jassim Abdulahameed, MD;  
Abdulraoof Alasadi, MD; Amina  
Hassan, MD and, Hanan  
Abuhassan, MD  
~Page 1

### Inaugural Pediatric Telehealth Colloquium

by Anita J. Moon-Grady, MD;  
Kourosh Parsapour, MD and  
James P. Marcini, MD  
~Page 9

## DEPARTMENTS

### Medical News, Products and Information

~Page 13

**CONGENITAL CARDIOLOGY TODAY**  
9008 Copenhaver Drive, Ste. M  
Potomac, MD 20854 USA  
Tel: +1.301.279.2005  
Fax: +1.240.465.0692

Editorial Offices:  
16 Cove Road, Ste. 200  
Westerly, RI 02891 USA

[www.CongenitalCardiologyToday.com](http://www.CongenitalCardiologyToday.com)

© 2007 by Congenital Cardiology Today  
(ISSN 1554-7787-print; ISSN 1554-0499-  
online). Published monthly. All rights  
reserved. Congenital Cardiology pro-  
vides timely news and information for  
pediatric and congenital cardiologists.  
Statements or opinions expressed in  
Congenital Cardiology Today reflect  
the views of the authors and sponsors,  
and are not necessarily the views of  
Congenital Cardiology Today.

## See Recruitment Ads

See pages 6, 7, 8, 10,  
11, 13, 14 and 15

## TRANSCATHETER COMPLETION OF FONTAN IN SAUDI ARABIA

By Mashail Alobaidan, MD; Jassim  
Abdulahameed, MD; Abdulraoof Alasadi,  
MD; Amina Hassan, MD and Hanan  
Abuhassan, MD

### Case Report

A 6 year old girl, weighing 23 kgs, had complex congenital heart disease consisting of severe tricuspid valve and right ventricular hypoplasia, normal related great arteries, severe pulmonary valve stenosis, as well as infundibular stenosis, had an emergency modified right Blalock-Taussig shunt at 20 months of age (the initial presentation), followed by modified hemi-Fontan at 5 years of age. She was scheduled for completion of Fontan in the catheter laboratory. Clinically, she had mild exercise intolerance with saturation of 84% at rest and 76% with exertion. She was receiving enalapril in addition to warfarin, and she had an INR of 2.2. Her chest X-ray revealed a normal heart silhouette and normal lung fields. Her ECG showed sinus rhythm and her echocardiogram indicated fair to good systolic ventricular function with no left atrioventricular valve (mitral valve) regurgitation, laminar flow across the Glenn anastomosis and a large communication between the IVC baffle and

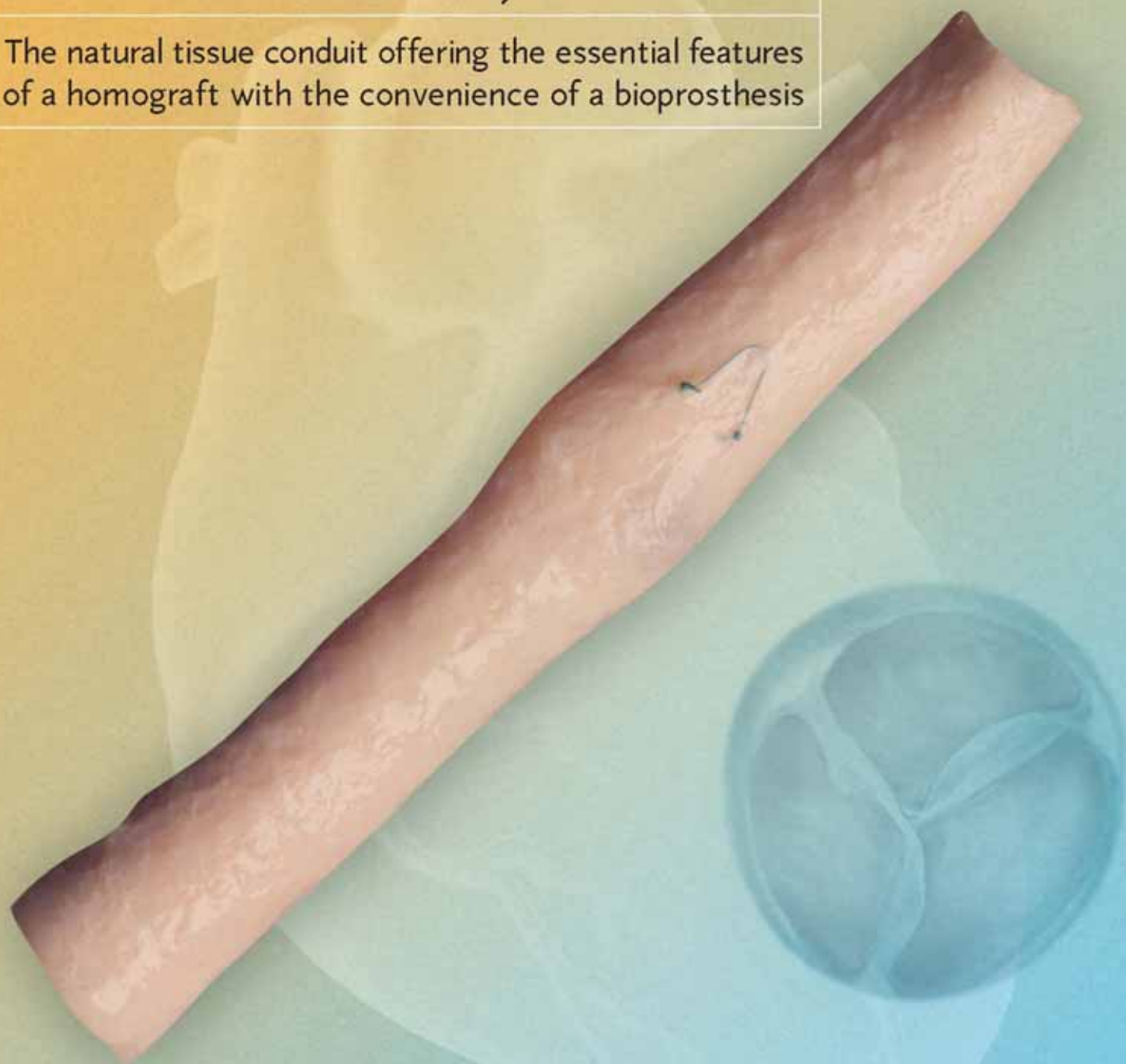
systemic atrium measuring about 16 mm. There was no thrombus and no pericardial effusion.

On the day before the procedure the patient was clinically assessed, the proce-

***“Recently a new strategy came into practice using a combined surgical and interventional approach: surgery is employed for the hemi-Fontan procedure, consisting of a surgical anastomosis of the SVC and the right pulmonary artery plus creation of a large interatrial communication. This was followed by transcatheter completion of the total cavopulmonary anastomosis. The patency of the SVC and IVC was achieved using a stent (covered or uncovered) and the baffle defect was closed using an Amplatzer Septal Occluder or other device.”***

# CONTEGRA® Pulmonary Valved Conduit

The natural tissue conduit offering the essential features of a homograft with the convenience of a bioprosthesis



This device has been approved as a humanitarian use device in the U.S.

#### CONTEGRA® Pulmonary Valved Conduit

**Indications:** See "Humanitarian Use Device" section below. **Contraindications:** - Patients 18 years and older. • If, after assessment of the risk to benefit ratio by the physician, superior clinical results are suggested by presently established alternative medical or surgical techniques. **Warnings/Precautions/Side Effects:** Acceptable clinical performance has been established for the Contegra conduit in pediatric patients under the age of 10. Because of the possibility that complications of the device could become apparent only after extended use, a benefit-risk consideration of the long-term use of the Contegra conduit in pediatric patients over 10 years of age is particularly important. General complications reported with valved conduits and biological tissue valves implanted in the heart include: hemorrhage, bleeding diathesis due to use of anticoagulants, residual or increasing transvalvular gradients, progressive neointimal thickening and peeling, progressive stenosis and obstruction, progressive pulmonary hypertension, graft infection, endocarditis, regurgitation, hemolysis, valve malfunction, physical or chemical deterioration, thromboembolism, thrombus, conduit dilatation. For additional information, please refer to the Instructions For Use provided with the product. **CAUTION:** Federal law (USA) restricts this device to sale by or on the order of a physician.

**\*Humanitarian Use Device:** Authorized by Federal law for use in patients under 18 years of age for correction or reconstruction of the Right Ventricular Outflow Tract (RVOT) in the following congenital heart malformations: Pulmonary Stenosis, Tetralogy of Fallot, Truncus Arteriosus, Transposition with Ventricular Septal Defect (VSD), Pulmonary Atresia. In addition, the Contegra Pulmonary Valved Conduit is indicated for the replacement of previously implanted but dysfunctional pulmonary homografts or valved conduits. The effectiveness of this device for these uses has not been demonstrated.

UC200703776 EN



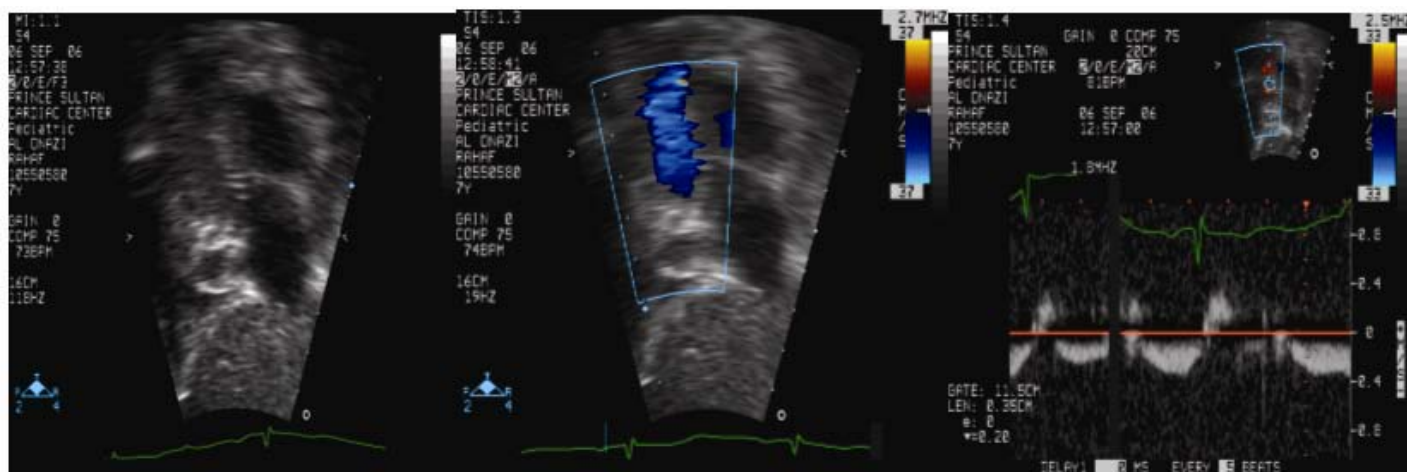


Figure 1. Subcostal views showing stent in RA-SVC junction with laminar flow, normal Doppler velocity, also device was seen closing the communication between lateral tunnel and atrium with no leak.

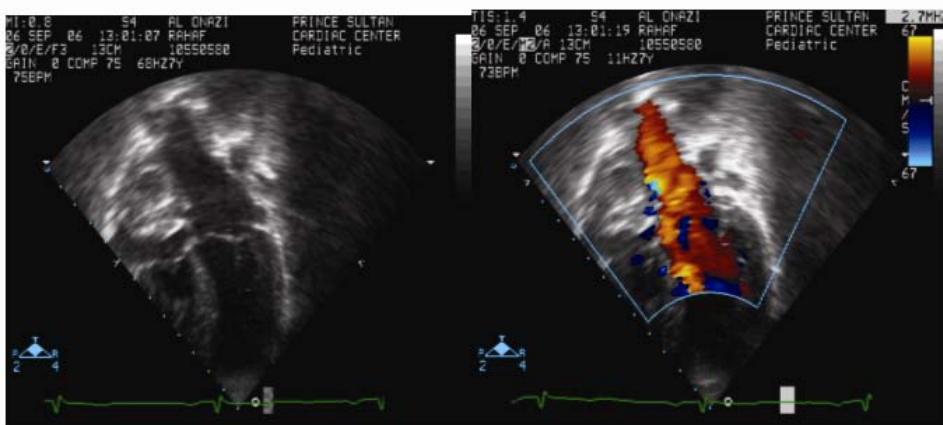


Figure 2. A 4-chamber view showing laminar flow from pulmonary veins to LA to LV through MV, small RV & Device is also seen in situ.

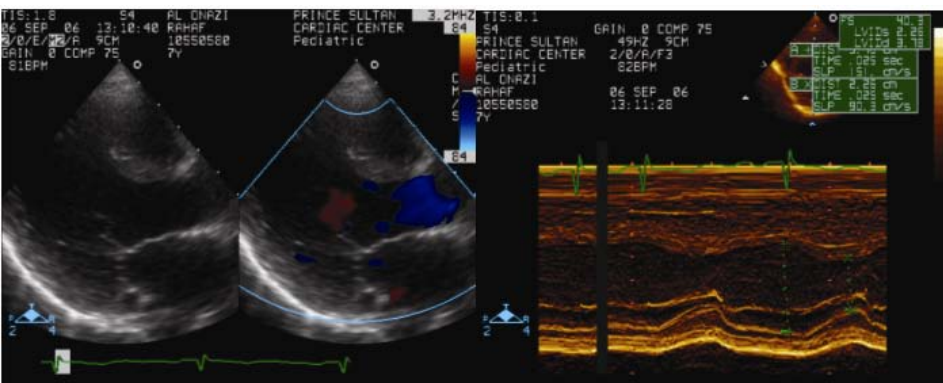


Figure 3. Long axis view showing competent mitral valve and good systolic ventricular function obtained by M-mode.

procedure was explained to the parents and consent was obtained.

The following day, general anesthesia was administered and mechanical ventilation was instituted. Standard hemodynamics were assessed, and bi-plane angiographic views of the main pulmonary artery, superior vena cava, inferior vena cava, left ventricle and aorta (Figure 6) were obtained. Then, the modified Fontan (total cavopulmonary connection) was completed. Hemodynamics were assessed again post procedure. She received heparin 100/kg IU during the procedure, and heparin was continued for 24 hours as an infusion. She was then transferred to the intensive care unit (ICU), and she was extubated the same night with good vital signs and laboratory parameters. She was discharged after 2 days on enalapril and warfarin. Both drugs were to be continued for 4-6 months before being replaced with aspirin.

Echocardiography (Figures 1,2,3), chest X-ray and ECG were repeated before her discharge. The results were positive.

# B | BRAUN

For information, please call 1-800-BRAUN2 (227-2862)

[www.bbraunusa.com](http://www.bbraunusa.com)



Working Together to Develop a Better Tomorrow



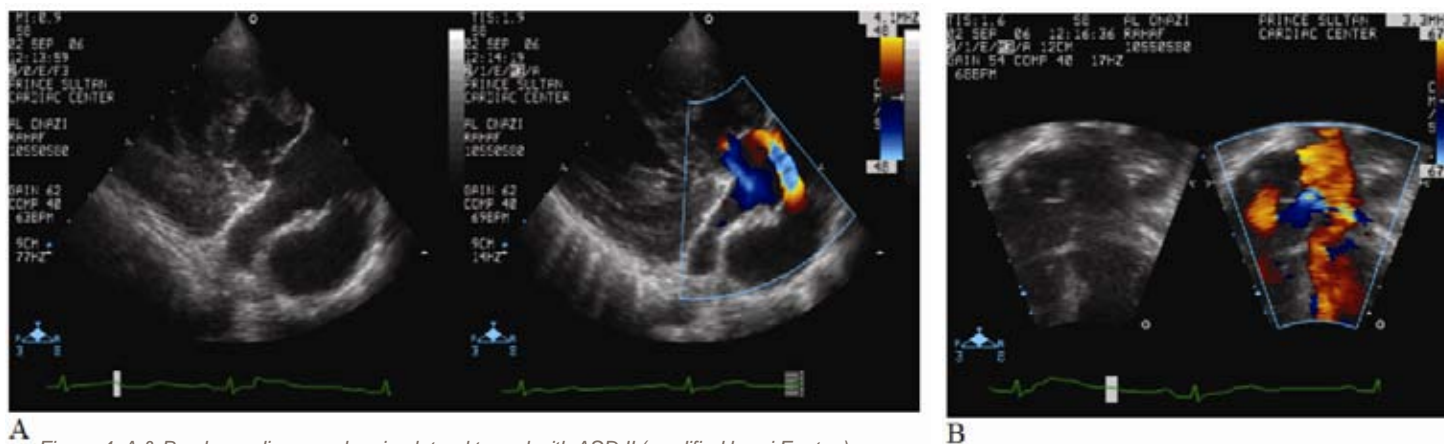

Figure 4. A & B echocardiogram showing lateral tunnel with ASD II (modified hemi Fontan).

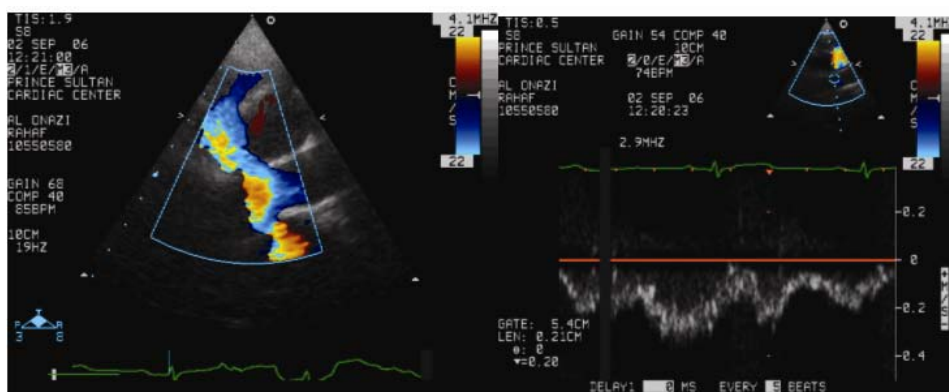


Figure 5. Suprasternal view of the SVC with laminar flow by pulse Doppler.

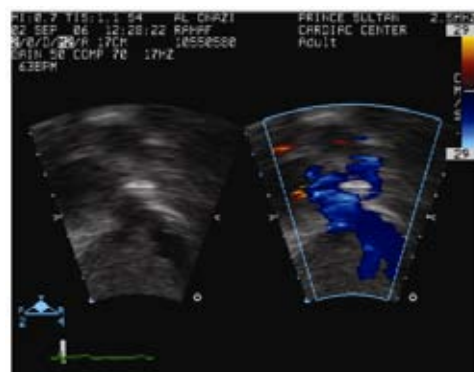


Figure 6. Subcostal view showing IVC laminar flow through the lateral tunnel.

## Method

### STAGE I:

#### Surgical Approach (Hemi-Fontan):

Through a median sternotomy, the superior vena cava (SVC) was dissected, transected, and then anastomosed to the right pulmonary artery (RPA), both upper and lower ends, (Figure 7A). Following that, cardiopulmonary by-pass was initiated. Bypass time was 116 minutes; aortic cross-clamp time was 71 minutes. The right atrium (RA) was opened.

The SVC was closed from the interior of the RA using autologous pericardium. Radio-opaque stitches were used as markers for the planned subsequent transcatheter procedure. A lateral tunnel was made directing the inferior vena cave to the SVC ending with a blind pouch. A 16 mm interatrial communication (ASD II) was created in the tunnel. The RA was closed followed, by de-airing and removal of the aortic cross-clamp and weaning from by-pass. Pacing wires as well as mediastinal and chest drains were placed and the sternum and chest was closed in layers.

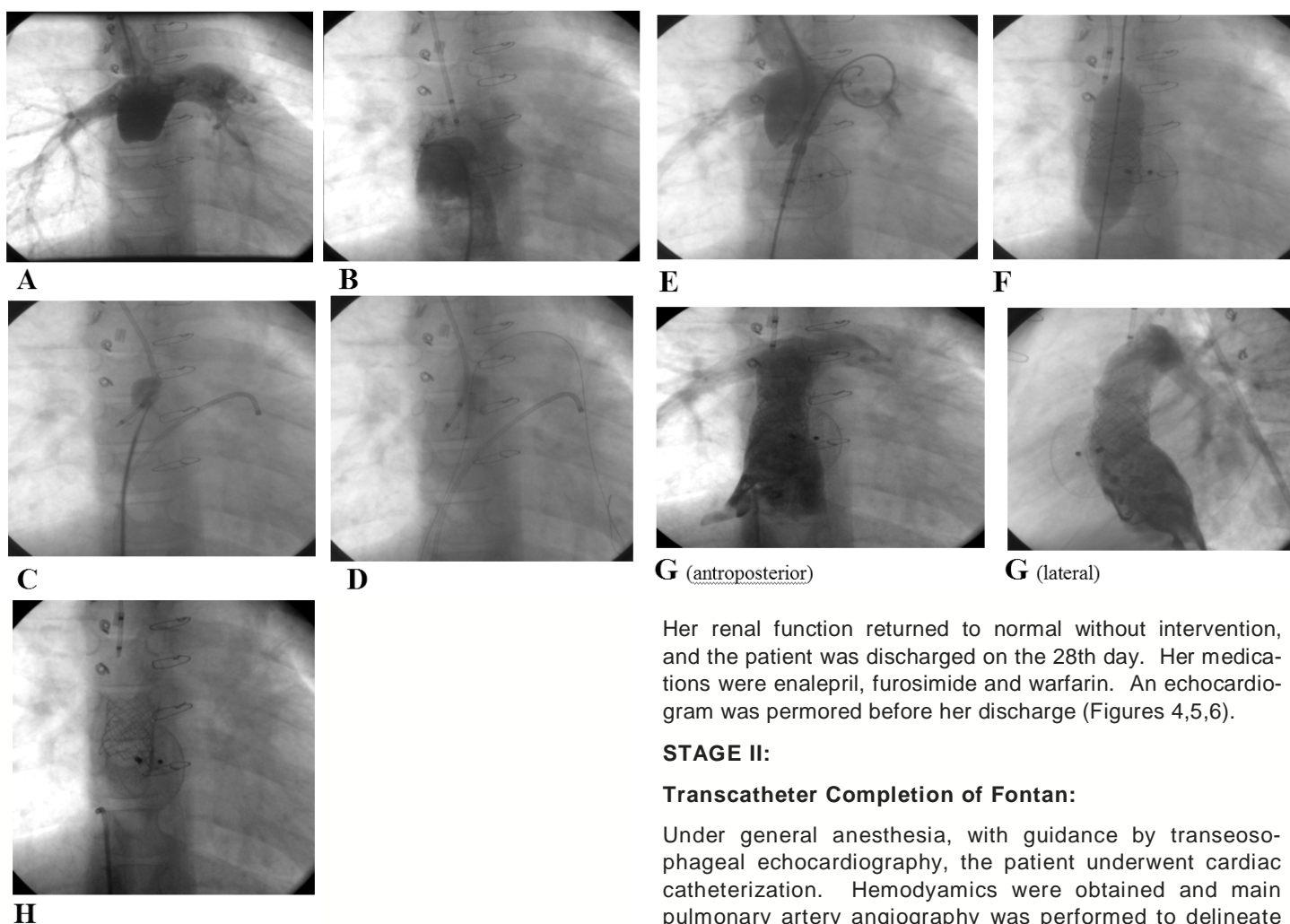
### Patient Course:

The patients stayed in the surgical ICU for 4 days, and remained on the ventilator for 3 days. She had bleeding which required re-exploration the first night. Milrinone and dopamine were administered for 3 days. She was weaned gradually from the ventilator and extubated. The inotropes were also weaned and oral enalapril and furosemide were initiated. She was transferred to the post operative ward on the 5th day, however, she developed a transudative pleural and pericardial effusion requiring chest drains.



**PICS 2007** JULY 22-25, 2007  
Bellagio, Las Vegas

[www.picsymposium.com](http://www.picsymposium.com)



**Figure 7.** Angiographic illustrations of the transcatheter completion of Fontan procedure: **A:** angiogram in SVC showing RPA anastomosis to SVC in both upper and lower ends; **B:** angiogram in the lateral tunnel with the RA blind pouch; **C:** opening of the pouch using transeptal needle; **D:** balloon dilatation of the hole; **E & F:** stent deployment in SVC-RA communication; **G (AP) & H:** angiogram and plane view showing patency of total cavopulmonary anastomosis after stent and device deployment.

After 25 days the chest drains were removed; she developed signs and symptoms of sepsis and needed broad spectrum antibiotics (amikacin in addition to a 3rd generation cephalosporin). She also had renal impairment thought to be secondary to the use of the aminoglycoside.

Her renal function returned to normal without intervention, and the patient was discharged on the 28th day. Her medications were enalapril, furosimide and warfarin. An echocardiogram was performed before her discharge (Figures 4,5,6).

#### STAGE II:

##### Transcatheter Completion of Fontan:

Under general anesthesia, with guidance by transeosophageal echocardiography, the patient underwent cardiac catheterization. Hemodynamics were obtained and main pulmonary artery angiography was performed to delineate the RPA-SVC anastomosis. Simultaneously an angiography was done in the RA where the blind pouch was made, and at the level of the marker stitches. The size of the pericardium pouch (lower end of SVC) was measured to be 16 mm in diameter. The RA-SVC pouch was perforated using a transeptal needle. An uncovered Palmaz stent (P308E) mounted on high pressure Mullins Balloon (size 16x4, PTM420) which was inflated to a pressure of 12 atmospheres. Subsequently, the ASD II was closed using an Amplatzer Septal Occluder (size 17 mm). Hemodynamics measured prior to release of the Amplatzer Device were favorable. She received heparin (100 units/kg) and cefuroxime during the procedure. After the procedure she

## Fifteenth Charleston Symposium on Congenital Heart Disease

Embassy Suites Historic District, Charleston South Carolina USA

May 2-4, 2007

Contact: Debbie Bryant (843) 792-3286, bryantd@musc.edu

[http://www.musckids.com/heart/conferences/symposium\\_07.pdf](http://www.musckids.com/heart/conferences/symposium_07.pdf)



was transferred to the intensive care unit. (Figure 7).

#### Hospital Course:

In the intensive care unit, the patient was extubated the first night and required no inotropes. Enalapril and furosemide were administered. Heparin infusion was continued for 24 hrs. Warfarin was started the next day. Three additional doses of cefuroxime were administered. Because she was doing well, she was transferred on the next day to the general ward. She was discharged the following day after repeat chest X-ray, ECG and echocardiography showed good results (Figure 1).

#### Discussion:

Univentricular repair (Fontan and its modifications) [1,2] is the established surgical option for single ventricle heart lesions. It can be applied as one stage or two stages (Glenn followed by total cavopulmonary anastomosis). The hemi-Fontan, first described in 1991, has undergone many modifications to facilitate completion of Fontan and for preparation of total cavopulmonary connection [3,4,5].

Recently a new strategy came into practice using a combined surgical and interventional approach: surgery is employed for the hemi-Fontan procedure, consisting of a surgical anastomosis of the SVC and the

right pulmonary artery plus creation of a large interatrial communication. This was followed by transcatheter completion of the total cavopulmonary anastomosis. The patency of the SVC and IVC was achieved using a stent (covered or uncovered) and the baffle defect was closed using an Amplatzer Septal Occluder or other device. This strategy may offer an improved early post-operative result in the high risk patient. [6].

Hausdorf et. al., in 1996 reported experience in eight patients [6]. In those patients, a bi-directional Glenn anastomosis was constructed and subtotal banding of the communication between SVC and RA was



### Arkansas Children's Hospital, Little Rock, AR PEDIATRIC TRANSPLANT CARDIOLOGIST



The Department of Pediatrics, Section of Cardiology, of the University of Arkansas for Medical Sciences College of Medicine located at Arkansas Children's Hospital in Little Rock, Arkansas, seeks candidates for an Assistant Professor (tenure track) position in the clinical-scientist pathway. M.D. degree and board eligibility/board certification in Cardiology is required. The position is available immediately, starting date is negotiable.

Cardiology offers state-of-the-art procedures and comprehensive post operative care to patients from Arkansas and the region. The Cardiac Catheterization team performs a variety of procedures including atrial septal defect closure, angioplasty with stent implantation, and blade and balloon atrial septostomy. Inpatient Cardiology and Intensive Care provides attending coverage of the cardiac intensive care service including post-operative care. The Cardiac Transplant program is recognized at one of the leading cardiac transplant programs in the United States. Cardiology Clinics and Outreach conduct monthly patient clinics in Fayetteville, Fort Smith, Texarkana, and Jonesboro.

The UAMS Department of Pediatrics employs over 195 faculty members and 75 residents. Arkansas Children's Hospital is among the largest children's hospitals in the United States. Located in the foothills of the Ozark Mountains, Little Rock offers Midwestern family values combined with the friendliness of the South, affordable housing, quality school options, a mild climate, excellent cultural and artistic venues, professional minor league sports, world class hunting, fishing and other outdoor recreational opportunities plus extraordinary natural beauty. With a population in excess of 500,000, Greater Little Rock offers the most desirable features of large cities without sacrificing ease of access and convenience. For more information, please see our website: [www.uams.edu/pediatrics](http://www.uams.edu/pediatrics).

#### Interested individuals should contact:

**W. Robert Morrow, MD**  
Professor of Pediatrics  
David and Stephanie Clark Chair in Pediatric Cardiology  
UAMS College of Medicine  
Arkansas Children's Hospital  
800 Marshall, Slot 512-3  
Little Rock, AR 72202-3591  
Phone: (501) 364-1479; Fax: (501) 364-3667  
[morrowwilliamr@uams.edu](mailto:morrowwilliamr@uams.edu)

*The State of Arkansas has a Conrad 30 program and the University of Arkansas for Medical Sciences is an equal opportunity employer.*



performed using 6-0 prolene suture. A multi-perforated Gore-Tex baffle was also inserted laterally in the right atrium as part of this first stage. The second stage consisted of balloon dilatation of the band and insertion of a Palmaz iliac stent followed by closure of the perforations using Rashkind PDA occluders or a covered stent.

In 1998, Sidiropoulos et. al. published the German experience of transcatheter completion of Fontan which is similar to the one described by Hausdorf [7].

In 2000, Klima et. al. reported a novel technique for establishing total cavopulmonary connection from surgical preconditioning to interventional completion in 10 sheep with the use of a stent graft (Aneurx Stent) [8].

In 2004, Galantowicz et. al. published the Columbus experience of a new combined surgical/transcatheter approach [9].

Konstantinov et. al., in 2005, published a simple surgical technique for transcatheter completion of total cavopulmonary anastomosis in experimental animals [10] using a covered stent.

In 2006, Konstantinov and Alexi-Meskishvili published a review of the use of intracardiac stents for transcatheter completion of total cavopulmonary connection from Canada and Germany [11].

In our center, we have performed this type of staged Fontan successfully in one patient. We are waiting for five additional surgically prepared patients who have had the surgical procedure described earlier. We plan to perform interventional completion of their Fontans.

The early follow-up of our single patient shows a very good result. Thus, we have been encouraged to apply this approach in a large number of selected cases in the future. We believe that there may be a role for use of the Fenestrated Amplatzer Septal Occluder in some of these patients.

The major advantage of transcatheter completion of the Fontan is that the "re-do" surgery can be avoided including the aortic cross-clamp and related myocardial ischemia. The disadvantages are similar to those of the intracardiac Fontan: the main complication being sinus node dysfunction because it is near the cavo-atrial junction where there may be mechanical interference from the stent implantation. To avoid sinus node dysfunction, it may be better to deploy the stent as high as possible in the cavo-atrial junction.

Because of advances in the first stage technique (surgical preconditioning for transcatheter completion of Fontan), more patients are planned to have this approach, in spite of the lack of favorable long-term outcome data. I believe that we need to have a 10 year review to evaluate non-surgical vs surgical outcomes. Until such a study is performed, because of the marked advantage of non-surgical completion of Fontan, I will advocate using this approach especially in high-risk patients and in others with favorable characteristics for the catheter completion procedure.

## References

1. Cardiac Surgery 2nd edition by John W. Kirklin, Brian G. Barratt-Boyes 1996.
2. The Science and Practice of Pediatric Cardiology 2nd edition Garson by Arthur Garson, TR, Bricker, T. Timothy Bricker, David J. Fisher, Steven R. Neish 1996.



## PEDIATRIC CARDIOLOGIST Tacoma, Washington

NorthWest Children's Heart Care, an affiliate of PEDIATRIX Medical Group, Inc., seeks a 4th BC/BE pediatric cardiologist for its rapidly growing practice in Puget Sound with an extensive outreach clinic network throughout southwest Washington. Candidates should be fellowship-trained in electrophysiology, or interested in practicing general cardiology with skills in non-invasive imaging. This full-service practice provides both invasive and noninvasive cardiology services in inpatient and outpatient settings, including post-operative care in the children's hospital in cooperation with pediatric and neonatal intensivists. Our outpatient clinics include a comprehensive Fetal Heart Program, a Preventive Cardiology Clinic, and a Cardiopulmonary Exercise Lab.

PEDIATRIX offers physicians competitive salaries and excellent benefits, including professional liability insurance, CME allowance, comprehensive health/life benefits, stock purchase plan and 401(k).

**For more information, please contact  
Lori Abolafia, Physician Relations Specialist,  
lori\_abolafia@pediatrix.com**


**PEDIATRIX Medical Group  
1301 Concord Terrace, Sunrise, FL 33323**

**800.243.3839 ext. 5209  
www.pediatrix.com**

*NorthWest Children's Heart Care, an  
affiliate of PEDIATRIX Medical Group, Inc.*

**Please visit us at Booth # 16 at the CHOP Meeting**

**DIVISION OF PEDIATRIC CARDIOLOGY**




**Doernbecher Children's Hospital**

The Division of Pediatric Cardiology at OHSU Doernbecher Children's Hospital has a faculty position available at the assistant or associate professor level as a General Pediatric Cardiologist. Subspecialty interest or training in heart failure, pulmonary hypertension or the care of cardiac transplant patients (currently performed elsewhere) is preferred. The candidate needs to be BE/BC in pediatric cardiology. In addition, the candidate should have excellent clinical judgment, a good work ethic, and the ability to collaborate with staff. This position will include ample opportunities for teaching and time to perform clinically focused research.

OHSU is located in Portland, Oregon, and is the state's only medical school. Doernbecher Children's Hospital is part of OHSU and includes 12 (soon to be 16) intensive care beds, 48 general pediatric beds, 12 (soon to be 24) oncology beds, and 48 neonatal intensive care beds. A well-established pediatric residency and pediatric cardiology fellowship program also exist. Portland is the largest city in Oregon and provides wonderful access to the Pacific Northwest.

**Please send CV's to Mark Reller, M.D.**  
 Division Head, Pediatric Cardiology • [reller@ohsu.edu](mailto:reller@ohsu.edu)  
 OHSU, Mail code CDRCF  
 707 S.W. Gaines Road  
 Portland, OR 97239



**OREGON HEALTH & SCIENCE UNIVERSITY**

OHSU is an equal opportunity, affirmative action institution.

3. Knott-Cragi CJ, Fryar-Dragg T, Overholt ED, Razook JD, Waed KE, Elkins RC. Modified hemi-Fontan operation; an alternative palliation for high-risk patient. *Ann Thorac Surg* 1995 Dec;60(6 Suppl):S554-7.

4. Schmid FX, Wippermann F, Kampmann C, Hilker C, Oelert H. Modified Hemi-Fontan procedure on the beating heart. *J Thorac Cardiovas Surg* 1990;117:188-190.

5. Harska V. A new approach to hemi-Fontan type of operation. *Interactive Cardiovascular and Thoracic Surgery* 2003;2:379-381.

6. Hausdorf G, Schneider M, Konertz W. Surgical preconditioning and completion of total cavopulmonary connection by conventional cardiac catheterization: a new concept. *Heart* 1996;75:403-409.

7. Sidiropoulos A, Ritter J, Shnieder M, Konertz W. Fontan modification for subsequent non-surgical Fontan completion. *European J. Cardiothoracic Surgery* 1998;13:509-513.

8. Klima U, Peters T, Peuster M, Hausdorf G, Haverich A. A novel technique for establishing total cavopulmonary connection; from surgical preconditioning to interventional completion. *J Thorac Cardiovasc Surg* 2000 Nov ;120(5):1007-9.

9. Galanowicz M, Cheatham JP. Fontan completion without surgery. *Semin Thorac Cardiovasc Surg Pediatr Card Surg Annu* 2004;7:48-55.

10. Konstantinov IE, Benson LN, Caldarone CA, Li J, Shimizu M, Coles JE, Van Arsdel GS, Williams WG. A simple surgical technique for interventional transcatheter completion of the total cavopulmonary connection. *J Thorac Cardiovasc Surg* 2005;129:210-212.

11. Konstantinov IE, Alexi-Meskishvili VV. Intra-cardiac covered stent for transcatheter completion of the total cavopulmonary connection: Anatomical, physiological and tech-

nical consideration. *Sndian Cardiovascular Journal* 2006 April; 40(2):71-7.

12. Crystal MA, Yoo SJ, Mikailian HJ, Benson LN. Catheter-Based Completion of the Fontan circuit: A Nonsurgical Approach. *Circulation* 2006;114 (1):5-6.

~CCT~

#### Corresponding Author:

*Mashail AL-Obaidan, MBBS, MRCP(1), MD, PHD, KFF, ABS, KSF Consultant Pediatric Cardiology Prince Sultan Cardiac Center Division of Pediatric Cardiology PO BOX 999111*

*Riyadh 11625 KSA*

*Fax/Tel: 00 9661473-0049*

*Tel: 4777714 EXT: 8795*

*Pager: 4110*

*Email: mashaila@hotmail.com*

*Jassim Abdulhameed, MBBS, MRCP, MD Division of Pediatric Cardiology, Prince Sultan Cardiac Center (PSCC), Riyadh, KSA*

*Abdulraoof Alasadi, MBBS, MD, FRCSC Division of Pediatric Cardiology, Prince Sultan Cardiac Center (PSCC), Riyadh, KSA*

*Amina Hassan, MBBBS, MRCP Division of Pediatric Cardiology, Prince Sultan Cardiac Center (PSCC), Riyadh, KSA*

*Hanan Abuhassan, MBBS, MD, ABS Division of Pediatric Cardiology, Prince Sultan Cardiac Center (PSCC), Riyadh, KSA*

**B | BRAUN**

For information, please call 1-800-BRAUN2 (227-2862)

[www.bbraunusa.com](http://www.bbraunusa.com)



Working Together to Develop a Better Tomorrow



## INAUGURAL PEDIATRIC TELEHEALTH COLLOQUIUM

By Anita J. Moon-Grady, MD; Kourosh Parsapour, MD and James P. Marcin, MD

*(The Pediatric Telehealth Colloquium held in San Francisco, CA, on October 27-29, 2006 was a 3-day international conference designed to address a variety of medical applications of telemedicine for improving access, quality of care and patient outcomes in pediatrics. Additionally, topics in strategic and administrative planning, equipment and technical support, research and the advancement of telehealth were discussed. This summary highlights the topics that were addressed with the hopes of generating further interest and support for future meetings. The goal is to provide an annual forum where experiences in telehealth can be shared and its development may be enhanced.)*

The regionalization of children's hospitals has led to higher quality of care and improved outcomes among pediatric patients. However, children living in non-urban areas have little to no access to pediatric specialty care. Telemedicine has become a novel solution to provide children in rural communities with access to subspecialists. The inaugural Pediatric Telehealth Colloquium was held in San Francisco, California on October 27-29, 2006, providing a forum for national and international experts in pediatric telehealth to share their experiences with each other and with other groups interested in establishing new telemedicine programs.

The Colloquium was held at the Hotel Nikko and was at maximum capacity with nearly one hundred attendees from the United States as well as international attendees from the Caribbean and Australia. The backgrounds of the attendees ranged from Children's Hospital specialists to rural physicians and nurses, as well as health care administrators seeking information on implementing and sustaining telemedicine networks. Representatives from eight

companies were also available to discuss their products ranging from infrastructure support to telemedicine robotics.



*By using telemedicine, Governor Schwarzenegger meets with one of the patients in the PICU at the UC Davis Children's Hospital.*

The conference presentations were structured around four themes: inpatient telemedicine, outpatient telemedicine, telehealth administration, and alternative applications of telemedicine. Dr. Tom Nesbitt provided the introduction and overview of telemedicine, with historical and future perspectives and applications. Following Dr. Nesbitt, a general "Telehealth Technology 101" lecture was given by Dan Kurywchak who has spent more than 17 years working with telemedicine technologies and provided the basic definitions and an overview that would be discussed over the three day Colloquium.

The conference keynote speaker was the Governor of the State of California, Arnold Schwarzenegger. Governor Schwarzenegger spoke about the "...life changing benefits of broadband...and the incredibly important work that can be done with these high speed and high performance technologies." In a live demonstration, Governor Schwarzenegger was connected via videoconference and spoke with an 11-year-old girl with leukemia and multiple other medical problems hospitalized in the Pediatric Intensive Care Unit (PICU) at the University of California, Davis Children's Hospital in Sacramento, California (90 miles or

145 km away, Figure 1). Finally, the Governor signed an executive order to help develop broadband networks that would assist government agencies in gaining access to the best available technologies to serve the people of California. He also called for the creation of a task force that would enable government and business experts to work together to improve broadband internet access across California and the rest of the United States.

After the Governor's appearance, the topic of "inpatient telemedicine" was introduced and moderated by Dr. Kourosh Parsapour. Dr. Randall Wetzell provided an overview of the applications of inpatient telemedicine along with a discussion regarding the advancement of the virtual PICU project at the Children's Hospital Los Angeles. The UC Davis experience in providing inpatient consultations by telemedicine was discussed by Dr. James Marcin. Dr. Marcin presented data from ongoing research studies evaluating the impact of telemedicine on patients and families in rural facilities receiving pediatric emergency and critical care consultations. Following this discussion, two primary care practitioners (Drs. Steve Struve and Mark Satterfield) from remote facilities shared with the audience their perspectives and provided lessons learned from their experience in a telemedicine relationship with tertiary centers. Finally, Dr. Karen Rheuban (University of Virginia) concluded the session with a discussion of the expanding use of pediatric telemedicine in the State of Virginia. In particular, she focused on the successful use of live (real-time videoconferencing for echocardiogram examinations) and store-and-forward (digital acquisition of echocardiograms with subsequent transmission of images for review) telemedicine in telecardiology.

"Telehealth administration" was the focus of the latter part of the first day, with a session moderated by Dr. Marcin. Ms. Anna Orłowski, Chief

Counsel for the UC Davis Health System provided an in-depth discussion of the legal and regulatory issues that surround many of the current telemedicine programs in the United States. Ms. Kathy Chorba, the Operations and Business Development Manager for the Health Systems Center for Health and Technology at

UC Davis, discussed administrative aspects of implementation of a telemedicine program and the requirements for sustaining the program after inception. These topics were very popular with conference attendees who were in the early phases of developing a program, as well as with individuals from institutions with well-established telemedicine networks. The day concluded with an opportunity for conference participants to interact with each other and experience a hands-on opportunity with the various technologies and demonstrations.

The second day of the colloquium focused on telemedicine applications for the delivery of outpatient services to patients in rural and remote areas. Dr. Javeed Siddiqui (Associate Medical Director, Center for Health and Technology, UC Davis) began the day with a general synopsis of "outpatient telemedicine" applications in the USA, then elaborated on the various applications of telemedicine at the UC Davis Children's Hospital including use in assisting with evidence collection and appropriate exams for suspected victims of child abuse, allowing for multidisciplinary collaboration for treatment regimens in pediatric oncology, distance assessment of pediatric gastroenterology patients, and management of pediatric obesity. Preliminary favorable results regarding ongoing patient and provider satisfaction studies were presented.

A session on telehealth and alternative applications followed, chaired by Dr. Philip Ozuah (Professor of Pediatrics, Children's Hospital, Montefiore, New York). Dr. Ozuah began with a summary of telemedicine services designed to benefit the underserved populations in the USA and abroad, including the use of videoconferencing for the delivery of health education to immigrant families living in the Bronx as well as a low-cost store-and-forward telemedicine service (supported by the Swinfen Charitable Trust) which provides doctors in developing countries with valuable e-mail based advice regarding specific patient-care queries provided at no cost by volunteer specialists around the world.

Other novel applications for telemedicine in pediatrics discussed during the Colloquium included Dr. Neil Herendeen's (Associate Professor of Pediatrics, Roch-

ester, New York) telemedicine program which provides medical consultation to childcare centers. This service allows children to remain in the childcare center and be "seen" by a physician for complaints ranging from earache to rashes using teleconferencing, thereby reducing the amount of parental leave taken for office-based doctor appointments for minor illnesses and to care for a mildly ill child at home. Dr. Rifat Latifi, a trauma surgeon from the University of Arizona, described a tele-trauma service which provides remote sites with access to an experienced trauma surgeon during the early critical stages of patient stabilization after critical traumatic injury prior to transport. And finally, Drs. Parsapour and Siddiqui discussed the alternative applications of telemedicine at UC Davis: the FamilyLink program which utilizes a video-phone, TV, and telephone lines to allow hospitalized children to visit with their families and friends during a hospitalization; and a video interpreting service, which allows in-house medical interpreting staff to cover a large hospital and outpatient clinic complex with a limited number of interpreters more efficiently, while assisting the medical team with communicating in a culturally competent manner.

A series of platform presentations were made during the lunch session, featuring Ms. Sarah Rhoads (University of Arkansas) and the ANGEL EYE, a web-based video link for parents to observe their infant during hospitalization in the neonatal intensive care unit. Dr. Kevin Hopkins (Driscoll Children's Hospital) presented his experience with the use of videophones for the postoperative management of children with complex cranio-facial reconstructions. Two excellent presentations from Australian delegates Dr. Anthony Smith and Mr. Nigel Armfield (University of Queensland) highlighted the extensive use for telemedicine in a country with extremely wide expanses which are sparsely populated. They presented the results of an economic evaluation the telepediatric service operated in Queensland by the Centre for Online Health (COH) in conjunction with the Royal Children's Hospital in Brisbane. During its first six years, more than 4,000 consultations have been conducted for children living in regional and remote ar-

## Pediatric Cardiology

We are looking for a non-invasive Pediatric Cardiologist for the Orlando Florida area. Established in 1994, we serve the Central Florida area with outpatient clinics, inpatient consults, fetal echo's and cardiac catheterizations.

Competitive salary and benefits, including paid health, disability, malpractice insurance and CME allowances.

Come enjoy Florida with its beautiful beaches, lakes, great outdoor activities, and many cultural and sporting events. The Orlando area boasts 'A' schools and a prominent local University.

For a glimpse into our practice visit our website at:

[www.carson-appleton.com](http://www.carson-appleton.com)

Please contact: Thomas Carson, M.D. for more details on this great opportunity via email at: [reddevet@aol.com](mailto:reddevet@aol.com) or our office at 407-902-2866.

Submit your CV via fax to 407-902-2585.



eas for 35 different pediatric subspecialties, with significant savings for the state government mainly due to reductions in government subsidized patient travel expenses. They have also developed a child-friendly mobile and wireless telemedicine system in the shape of a robot, which is now in use in selected regional hospitals in Queensland which lack the services of onsite pediatricians and specialist staff.

The final day of the conference returned to the theme of administration relating to telemedicine services. This session was particularly useful for delegates with limited experience in telemedicine and at the early stages of developing a telemedicine program. This session was chaired by Dr. Sanford Melzer from the Children's Hospital and Regional Medical Center in Seattle, Washington. Dr. Melzer, Ms. Jana Katz (Assistant Dean for Administration at UC Davis) and Dr. Marcin covered issues including program sustainability, financial planning and billing. Ms. Katz reminded delegates to "...take caution to promises that telemedicine equipment will solve all of your problems...ensure that the goals of the telemedicine program are consistent with the mission of the overall organization...and don't underestimate the importance of a good site coordinator."

Finally, Dr. Marcin tackled the economics of telemedicine services offered through the outpatient and inpatient settings. Based on preliminary data gathered through a two-year period in Northern California, and extrapolating these figures over a five-year period, he presented findings demonstrating significant potential financial benefits for the receiving sites of telemedicine services.

The conference also included several abstracts in poster format designed to educate and inform participants regarding studies and other applications for telemedicine technology. Poster topics

ranged from the use of store-and-forward tele-echocardiography for remote Pediatric Cardiology support of a rural level III neonatal ICU lacking a local Cardiologist, to improved outcomes and provider satisfaction with use of telemedicine technology rather than traditional telephone for assisting rural emergency departments during pediatric resuscitations, to the feasibility of a telemedicine-based outreach and behavior modification program for obese adolescent Native Americans living in a rural area of Northern California and a proof-of-concept presentation of the use of a retinal camera for remote ophthalmology examinations in infants at risk for retinopathy of prematurity.

The inaugural Pediatric Telemedicine Colloquium provided an excellent opportunity for attendees to learn about established telepediatric programs and to meet with leaders in the field. The colloquium will continue as an annual event with the next meeting scheduled for Fall 2007 in San Francisco.

~CCT~

#### Corresponding Author:

Anita J. Moon-Grady, MD, FAAP,  
FACC

Assistant Professor of Pediatrics  
Pediatric Cardiology  
UC Davis Children's Hospital  
2516 Stockton Blvd.  
Sacramento, CA 95817 USA  
Fax: (916) 734-0424

[anita.moongrady@ucdmc.ucdavis.edu](mailto:anita.moongrady@ucdmc.ucdavis.edu)

Kourosh Parsapour, MD  
UC Davis Children's Hospital  
Sacramento, CA USA

James P. Marcin, MD, MPH  
UC Davis Children's Hospital  
Sacramento, CA USA

### Director of Non-invasive Imaging

The Congenital Heart Center at the University of Florida has a faculty position opening at the level of Associate Professor/Professor in a non-tenure or tenure-accruing position. The position of Director of Non-invasive Imaging has been established to bring together the modalities of echocardiography, MRI and CT angiography into a cohesive unit for advancing research and clinical care in congenital heart disease imaging. The position will assist with coordination of all aspects of pediatric non-invasive imaging and participate in the provision of general pediatric cardiology services. This role includes teaching of residents, fellows, medical students and other health care professionals. Opportunities exist for participation in a strong clinical research program in addition to an excellent clinical practice.

This position is for a Board Certified Pediatric Cardiologist.

Applicants should send a letter of application, a C.V., and three letters of reference referencing LP# 00023002 to:

Barry J. Byrne, M.D., Ph.D.,  
Medical Director of the Congenital  
Heart Center  
University of Florida College of  
Medicine  
P.O. Box 100296  
Gainesville, FL 32610-0296

**UF** UNIVERSITY of  
**FLORIDA**  
The Foundation for The Gator Nation



## 11th Vail Symposium on Pediatric Cardiac Diseases

Hosted by The Children's Hospital—Denver

Vail Cascade Resort, Vail, Colorado

March 4-7, 2007

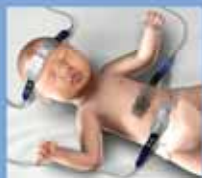Contact: [Dixon.Jeannie@tchden.org](mailto:Dixon.Jeannie@tchden.org) or [Manzanares.Heidi@tchden.org](mailto:Manzanares.Heidi@tchden.org)



SOMANETICS®

**REVEAL TISSUE  
PERFUSION**

**WITH SITE-SPECIFIC  
SATURATION DATA**

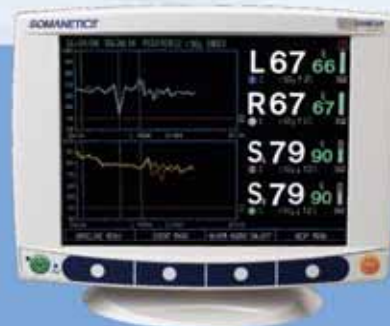

Augment *systemic* data with noninvasive *regional* oxygen saturation ( $rSO_2$ ) from up to four sites. Only the INVOS® Cerebral/Somatic Oximeter monitors oxygenation data from the brain and body simultaneously and continuously. This site-specific tissue perfusion can enhance your clinical assessment in a meaningful way and help detect ischemic problems earlier than traditional measures. This additional vital sign lets you intervene and put things right — before they escalate.

800-359-7662 [www.somanetics.com](http://www.somanetics.com)

**REFLECTING THE COLOR OF LIFE™**

**INVOS** CEREBRAL/SOMATIC  
OXIMETER



© 2006 Somanetics Corporation. Somanetics and INVOS are registered trademarks of Somanetics Corporation. "Reflecting the color of life" is a trademark of Somanetics Corporation. US federal regulations restrict the sale of this device to, or on the order of, licensed medical practitioners.

## MEDICAL NEWS, PRODUCTS AND INFORMATION

**Medtronic Announces Canadian Market release of the First Transcatheter Valve Replacement System for Structural Heart Disease**

Medtronic, Inc. has announced that it has received a Medical Device License from Health Canada to sell its Melody™ Transcatheter Pulmonary Valve and Ensemble™ Transcatheter Delivery System. The system is the first of its kind in North America to treat patients with congenital and acquired structural heart disease requiring pulmonary valve replacement.

The Medtronic Melody™ Transcatheter Pulmonary Valve and Ensemble™ Transcatheter Delivery System are designed to benefit patients with congenital heart defects involving the connection between their right ventricle and pulmonary artery. Oftentimes, this type of defect requires open heart surgery early in life to implant a prosthetic valved conduit to establish adequate blood flow from the heart to the lungs. However, the functional life span of these conduits is relatively limited, and as a result most patients with this type of defect are committed to multiple open heart surgeries over their lifetime. The Melody Valve and Ensemble system provide a non-surgical means to restore effective valve function and prolong the functional life of prosthetic conduits, thereby reducing the number of open heart surgeries for these patients throughout their lifetime.

"Medtronic of Canada is proud to partner with the leading cardiovascular health professionals across Canada to offer the Melody™ Transcatheter Pulmonary Valve to their patients with congenital heart valve disease. Managing such a complex disease requires a cohesive team approach between cardiac surgeons and interventional cardiologists and we are committed to delivering technologies to these Canadian physicians and their patients to achieve compelling outcomes and fulfill our Mission to alleviate pain, restore health, and extend life," said Neil Fraser, President of Medtronic of Canada Ltd.

To date, more than 190 patients worldwide have been implanted with the Melody Transcatheter Pulmonary Valve. In Canada, Dr. Lee Benson, an interventional cardiologist, at the Hospital for Sick Children in Toronto and Dr. Eric Horlick, at the University Health Network, Toronto General Hospital, Toronto were the first in North America to implant Melody Valves under special access permission from Health Canada in October 2005. Dr. Benson reports that the safety and efficacy of the implant is excellent, with excellent functional improvement in the patients.

The University of Alberta Hospital in Edmonton, The Toronto General Hospital, Hôpital Laval in Québec City, and McGill University Health Centre count trained physicians on their staff to perform the procedure.

**PEDIATRIC CARDIOLOGIST**  
Phoenix, Arizona

Arizona Pediatric Cardiology Consultants, an affiliate of Obstetrix Medical Group, Inc. seeks two BE/BC pediatric cardiologists for our 15-member group practice. The first position is for a non-invasive cardiologist with a focus in echocardiography. Shared responsibilities with our five echocardiographers include interpreting more than 14,000 echocardiograms, 700 plus fetal echocardiograms, and 750 transesophageal echocardiograms annually. We are also recruiting a generalist to provide outpatient services in one of our community-based offices. The practice is recognized as the primary pediatric cardiology group at Phoenix Children's Hospital, providing all inpatient cardiology care, including transthoracic and transesophageal echocardiography, catheter interventions, electrophysiology/RFA, and MRI procedures.

Benefits include competitive salaries and excellent benefits, including professional liability insurance, CME allowance, comprehensive health/life benefits, stock purchase plan and 401(k).

For more information, please contact  
Lori Abolafia, Physician Relations Specialist,  
[lori\\_abolafia@pediatrix.com](mailto:lori_abolafia@pediatrix.com)

Pediatrix Medical Group  
1301 Concord Terrace, Sunrise, FL 33323

800.243.3839 ext. 5209  
[www.pediatrix.com](http://www.pediatrix.com)

Arizona Pediatric Cardiology Consultants, an  
affiliate of Obstetrix Medical Group, Inc.

Please visit us at Booth # 16 at the CHOP Meeting



In support of infants, children and teens with pediatric cardiomyopathy

**CHILDREN'S CARDIOMYOPATHY FOUNDATION**

P.O. Box 547, Tenaflly, NJ 07670

Tel: 201-227-8852 [info@childrenscardiomyopathy.org](mailto:info@childrenscardiomyopathy.org) [www.childrenscardiomyopathy.org](http://www.childrenscardiomyopathy.org)

"A Cause For Today.... A Cure For Tomorrow"



### Opportunities for Pediatric Cardiologists in Southern California

Loma Linda University Faculty Practice Plan is seeking two pediatric cardiologists to join a rapidly expanding practice in southern California. The group currently consists of five full-time board-certified pediatric cardiologists and works in close association with the Loma Linda International Heart Institute and the three pediatric cardiovascular surgeons on staff. Located 60 miles east of Los Angeles, Loma Linda University Medical Center and Children's Hospital is one of the busiest hospitals within an area of California with very rapid population growth. LLUCH includes an 84-bed NICU, a 25-bed PICU, and a 12-bed pediatric cardiac ICU.

Candidates trained in the following areas are desired:

1. Non-invasive pediatric cardiology. The position requires expertise in non-invasive pediatric cardiology, with special skills in transthoracic, transesophageal, and fetal echocardiography. The echo lab performs more than 6,500 echoes annually and is accredited by ICAEL.

2. General pediatric cardiology. Responsibilities will include participation in echocardiography and diagnostic catheterizations.

Positions will include responsibilities in outpatient clinics and the teaching of medical students and residents. Candidates should be BC/BE in pediatric cardiology.

#### Interested candidates may contact:

Ranae L. Larsen, MD  
Chief, Division of Pediatric Cardiology  
Loma Linda University Faculty Practice Plan  
(909) 558-4711 phone  
rlarsen@ahs.llumc.edu email  
www.socaldocs.com



Transcatheter valve technology represents a less invasive means to treat heart valve disease and is designed to allow physicians to deliver replacement valves via a catheter through the body's cardiovascular system, thus eliminating the need to open the chest. Traditionally, open heart surgery has been required to correct the problem and it is not unusual for a patient to undergo multiple, open-heart surgeries during their lifetime. Patients with this condition can tire easily, as the heart over-exerts itself trying to get blood from the right heart into the pulmonary circulation. "The application of these transcatheter valve technologies has altered the way we approach management of congenital and structural heart disorders," reports Dr. Benson. For more information: [www.medtronic.com](http://www.medtronic.com).

### Google Can Help Doctors Diagnose Difficult Cases

A study from Australia published on [bmj.com](http://bmj.com) finds searching with Google may help doctors to diagnose difficult cases.

Doctors have been estimated to carry two million facts in their heads to help them diagnose illness, but with medical knowledge expanding rapidly, even this may not be enough. Google a popular search engine on the world wide web, gives users quick access to more than three billion medical articles.

So, how good is Google in helping doctors diagnose difficult cases?

Doctors at the Princess Alexandra Hospital in Brisbane identified 26 difficult diagnostic cases published in the New England Journal of Medicine in 2005. They included conditions such as Cushing's syndrome and Creutzfeldt-Jakob disease.

They selected three to five search terms from each case and did a Google search while blind to the correct diagnoses. They then selected and recorded the three diagnoses that were ranked most prominently and seemed to fit the symptoms and signs, and compared the results with the correct diagnoses as published in the journal. Google searches found the correct diagnosis in 15 (58%) of cases.

Although doctors and patients are increasingly using the internet to search for health related information, the authors suggest that Google is likely to be a useful aid for conditions with unique symptoms and signs that can easily be used as search terms. However, they stress that the efficiency of the search and the usefulness of the retrieved information depend on the searchers' knowledge base.

To view the paper go to:

<http://press.psprings.co.uk/bmj/november/google.pdf>



Barth Syndrome  
Foundation

## The Barth Syndrome Foundation

P.O. Box 974, Perry, FL 32348

Tel: 850.223.1128

[info@barthsyndrome.org](mailto:info@barthsyndrome.org)

[www.barthsyndrome.org](http://www.barthsyndrome.org)

**Symptoms:** Cardiomyopathy, Neutropenia, Muscle Weakness, Exercise Intolerance, Growth Retardation



## Pediatric Cardiac Anesthesiologist

The Congenital Heart Center at the University of Florida has a faculty position opening at the level of Clinical Assistant/Associate Professor in a non-tenure accruing position. This position will coordinate all aspects of pediatric cardiac anesthesia services, including those for the cardiac operating rooms, cardiac catheterization, cardiac MRI, and other related areas for children. This role includes teaching of residents, fellows, medical students and other health care professionals. This position will bring clinical research funding and expertise or develop a clinical research program. This position is for a Board Certified/Board Eligible Anesthesiologist

Applicants should send a letter of application, a C.V., and three letters of reference to:

Mark Bleiweis, M.D, Director  
Congenital Heart Center  
University of Florida College of Medicine  
P.O. Box 100296  
Gainesville, FL 32610-0296

*Anticipated hiring date is on or before July 1, 2007.*



## Clinical Assistant/ Associate Professor

The Congenital Heart Center at the University of Florida has a faculty position opening at the level of Clinical Assistant/Associate Professor in a non-tenure-accruing position. This position will assist with coordination of all aspects of pediatric interventional cardiac catheterization services and also provide general pediatric cardiology care.

Fourth year interventional catheterization training is required. This role includes teaching of residents, fellows, medical students and other health care professionals.

The position is for a Board Certified or Board Eligible Pediatric Cardiologist.

Applicants should send a letter of application, a C.V., and three letters of reference referencing LP# 00023006 to:

Randal M. Bryant, M.D, Search Committee Chair  
Congenital Heart Center  
University of Florida College of Medicine  
P.O. Box 100296  
Gainesville, FL 32610-0296



© 2007 by Congenital Cardiology Today  
(ISSN 1554-7787-print; ISSN 1554-0499-online)  
Published monthly. All rights reserved

### Publishing Management

Tony Carlson, Founder & Editor  
[TCarlsonmd@gmail.com](mailto:TCarlsonmd@gmail.com)  
Richard Koulbanis, Publisher & Editor-in-Chief  
[RichardK@CCT.bz](mailto:RichardK@CCT.bz)

John W. Moore, MD, MPH, Medical Editor/  
Editorial Board

[JMoore@CHSD.org](mailto:JMoore@CHSD.org)

Jeffrey Green, Contributing Editor

### Editorial Board

Teiji Akagi, MD  
Zohair Al Halees, MD  
Mazeni Alwi, MD  
Felix Berger, MD  
Fadi Bitar, MD  
Jacek Bialkowski, MD  
Philipp Bonhoeffer, MD  
Anthony C. Chang, MD, MBA  
John P. Cheatham, MD  
Bharat Dalvi, MD, MBBS, DM  
Horacio Faella, MD  
Yun-Ching Fu, MD  
Felipe Heusser, MD  
Ziyad M. Hijazi, MD, MPH  
Ralf Holzer, MD  
Marshall Jacobs, MD  
R. Krishna Kumar, MD, DM, MBBS  
Gerald Ross Marx, MD  
Tarek S. Momenah, MBBS, DCH  
Toshio Nakanishi, MD, PhD  
Carlos A. C. Pedra, MD  
Daniel Penny, MD  
James C. Perry, MD  
Shakeel A. Qureshi, MD  
Andrew Redington, MD  
Carlos E. Ruiz, MD, PhD  
Girish S. Shirali, MD  
Horst Sievert, MD  
Hideshi Tomita, MD  
Gil Wernovsky, MD  
Zhuoming Xu, MD, PhD  
William C. L. Yip, MD  
Carlos Zabal, MD

### To Contact an Editorial Board Member

Email to: [BOARD@CCT.bz](mailto:BOARD@CCT.bz). Place the Board Member's name in the Subject line.

### FREE Subscription

Congenital Cardiology Today is available free to qualified professionals worldwide in pediatric and congenital cardiology. International editions available in electronic PDF file only; North American edition available in print. Send an email to [Subs@CCT.bz](mailto:Subs@CCT.bz). Be sure to include your name, title, organization, address, phone, fax and email.

### Contacts and Other Information

For detailed information on author submission, sponsorships, editorial, production and sales contact, current and back issues, see website: [www.CongenitalCardiologyToday.com](http://www.CongenitalCardiologyToday.com)



CONTEMPORARY QUESTIONS  
IN CONGENITAL HEART DISEASE  
**THE LEFT HEART**

**Four Seasons Hotel**

June 10-12, 2007; Toronto, Canada

[www.sickkids.ca/cardiacsymposium](http://www.sickkids.ca/cardiacsymposium)

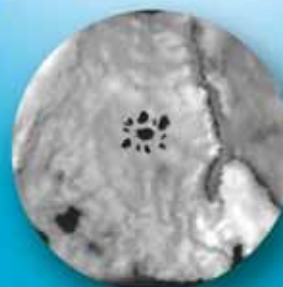

# AMPLATZER®

## "Cribriform" Septal Occluder

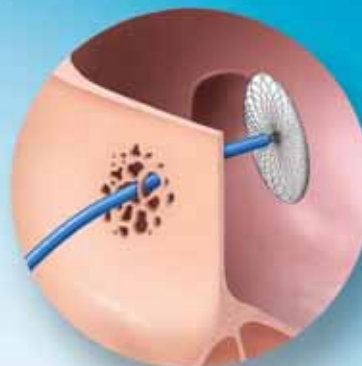
### A Single Solution for Multi-Fenestrated Atrial Septal Defects

- **Narrow waist for atraumatic placement**
- **Broad contact surface to occlude multiple fenestrations with one device**
- **Can be recaptured and repositioned prior to release**

The AMPLATZER® Cribriform Septal Occluder complements AGA Medical Corporation's line of ASD Occlusion Systems, the most comprehensive line of transcatheter closure solutions available for treating atrial septal defects.



*Multi-fenestrated atrial septal defect.*



*The AMPLATZER Cribriform Occluder enables closure of multiple fenestrations with a single device.*

**For More Information:**  
**Call: 888-546-4407 (toll-free, US)**  
**Visit: [www.amplatzer.com](http://www.amplatzer.com)**



**AGA Medical  
CORPORATION**

© AGA Medical Corporation 2007. Amplatzer is a registered trademark of AGA Medical Corporation. Not in any way connected with medical gas or equipment sold under the "AGA" brand by AGA AB or its successors.