

# CONGENITAL CARDIOLOGY TODAY

Timely News and Information for BC/BE Congenital/Structural Cardiologists and Surgeons

Volume 6 / Issue 4  
April 2008  
International Edition

## IN THIS ISSUE

**Transcatheter Closure of Large Secundum Atrial Septal Defects in Patients with Ebstein's Malformation of the Tricuspid Valve. A Report of Two Cases**

by Mohammed T. Numan, MD;  
Sulafa KM Ali, MD, FACC, FRCPC  
Page 1

**Rady Children's Hospital / University of California San Diego Cardiovascular Team Returns to Siem Reap and to the Cambodian Children with PDA**

by Susan T. Grossfeld, BS and  
Paul D. Grossfeld, MD  
Page 5

**Highlights from the XVI International Parma Echo Meeting**

by Umberto Squarcia, MD, FACC  
Page 11

## DEPARTMENTS

**June Medical Meeting Focus - ISHAC**  
Page 9

**June Medical Meeting Focus - CSI 2008**  
Page 11

**Medical News, Products and Information**  
Page 10

## CONGENITAL CARDIOLOGY TODAY

Editorial and Subscription Offices  
16 Cove Rd, Ste. 200  
Westerly, RI 02891 USA

[www.CongenitalCardiologyToday.com](http://www.CongenitalCardiologyToday.com)

© 2008 by Congenital Cardiology Today ISSN: 1544-7787 (print); 1544-0499 (online). Published monthly. All rights reserved.

Statements or opinions expressed in Congenital Cardiology Today reflect the views of the authors and sponsors, and are not necessarily the views of Congenital Cardiology Today.

## Transcatheter Closure of Large Secundum Atrial Septal Defects in Patients with Ebstein's Malformation of the Tricuspid Valve. A Report of Two Cases

By Mohammed T. Numan, MD; Sulafa KM Ali, MD, FACC, FRCPC

### Abstract

Atrial septal defects are common in patients with Ebstein's Malformation of the tricuspid valve and may contribute to their hemodynamic disturbances. We report the transcatheter closure of large atrial septal defects in two patients with Ebstein's Malformation using Amplatzer (26 mm) and Helex (20 mm) septal occluders with no residual atrial shunts and no complications at 10 months follow up.

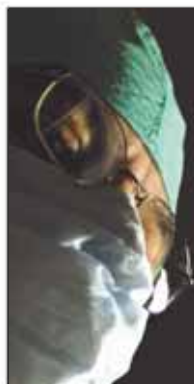Transcatheter closure of large atrial septal defects in Ebstein's Malformation is feasible with a good short-term outcome.

### Introduction

Ebstein's Malformation has been reported to represent 2% of congenital heart defects in the Sudanese population, 4 times the reported frequency in the Western literature [1]. Secundum atrial septal defect is a common finding in patients with Ebstein's Malformation, often leading to aggravation of the volume overload of the right atri-

um[2,3] Secundum atrial septal defect transcatheter closure is now considered a standard practice in patients without Ebstein's Malformation [4,5]. Interventional closure of atrial communications may be preferable in patients with Ebstein's Malformation because postoperative complications and arrhythmias may be avoided. We report our experience with two Sudanese patients who have Ebstein's Malformation and large left to right shunt across secundum atrial septal defect. Both underwent successful transcatheter closure of their defects.

***"Atrial septal defects are common in patients with Ebstein's Malformation of the tricuspid valve and may contribute to their hemodynamic disturbances."***



## RECRUITMENT ADVERTISING FOR Europe, Asia, Middle East, Australia

- Pediatric Cardiologists
- Congenital/Structural Cardiologists
- Interventionalists
- Echocardiographers
- Imaging Specialists
- Electrophysiologists
- Congenital/Structural Heart Failure Specialists
- Cardiac Intensivists

For Recruitment information: [TCarlsonmd@gmail.com](mailto:TCarlsonmd@gmail.com)

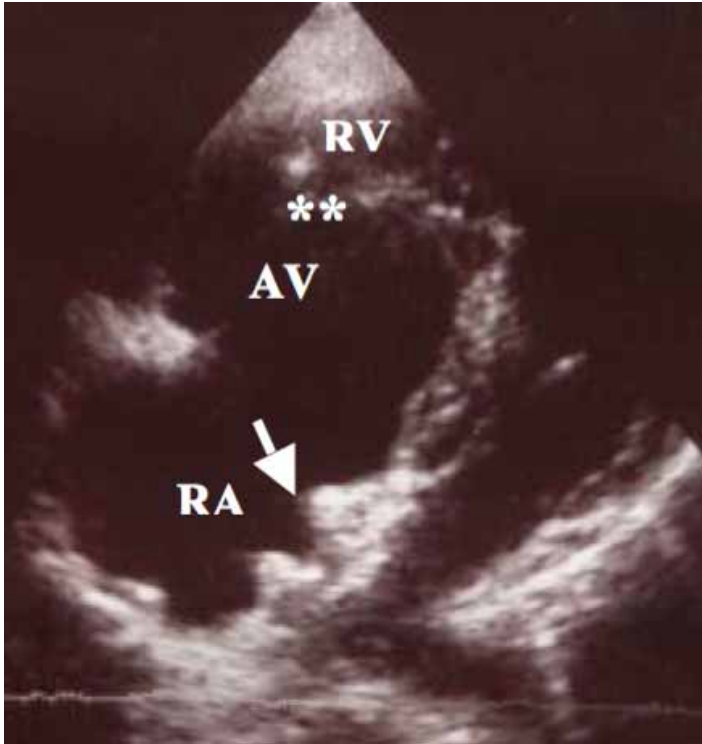


Figure 1. Modified 4 chamber view of patient no. 1 showing Amplatzer device aligned with the interatrial septum (arrow). Displaced tricuspid valve (stars) and atrialized right ventricle (RA: right atrium, AV: atrialized right ventricle, RV: right ventricle).

## Methods

The patients were seen at the Sudan Heart Centre in 2004 and diagnosis was made by clinical and echocardiographic assessment. Ebstein's Malformation was diagnosed because the septal leaflet of the tricuspid valve was apically displaced by more than 8mm per square meter (surface area), and this was referred to as displacement index. In April 2006 transoesophageal echocardiography and cardiac catheterization were performed under general anesthesia. Complete diagnostic hemodynamic studies and atrial defect closure were performed.

## Patient 1

A 35 year old Sudanese lady was evaluated because of a 2 year history of shortness of breath during exercise. Six months prior to presentation she experienced left sided weakness involving her upper and lower limbs. This weakness resolved gradually over 3 months and she regained complete motor function. Cardiac examination revealed signs of secundum atrial septal defect. Her systemic oxygen saturation was 98% at rest. Her electrocardiogram showed normal sinus rhythm, peaked P waves, first degree

atrioventricular block and RSR' pattern. No pre-excitation was noted. Echocardiogram revealed Ebstein's Malformation of the tricuspid valve with a septal leaflet displacement index of 20. Tricuspid regurgitation was mild to moderate. There was a large secundum atrial septal defect measuring 18 mm with left to right shunting. The right atrium was dilated. Left sided structures and Left ventricle ejection fraction were normal.

The patient underwent transesophageal echocardiogram and cardiac catheterization which revealed a stretched ASD diameter of 26 mm. Oxygen saturations showed a left to right shunt with Qp:Qs flow ratio of 2.6:1. Mean right atrial pressure was 10, right ventricle pressure was 20/0 and pulmonary artery mean pressure was 10 mmHg. Amplatzer atrial septal defect occluder size 26mm was deployed successfully with a good alignment (Figure 1). There was no residual atrial shunt on transesophageal echocardiogram and no effect on other cardiac structures. Right atrial pressure post procedure did not change and there were no complications. Prophylactic antibiotics and heparin were given and she was discharged 24 hours after the procedure on aspirin 100mg once a day. On follow up at 2,6 and 8 months she was asymptomatic, in sinus rhythm and echocardiography showed mild tricuspid regurgitation and no residual atrial septal defect.

## Patient 2

An 8 year old female was evaluated because of a heart murmur. Physical examination showed normal growth, normal first heart sound, widely split second heart sound and a soft ejection systolic murmur in the pulmonary area with no clicks. Her oxygen saturation was 98% at rest. Electrocardiogram showed normal sinus rhythm, peaked P wave and RSR pattern. No pre-excitation was seen. Echocardiogram revealed Ebstein's Malformation of the tricuspid valve with a septal leaflet displacement index of 35. Tricuspid regurgitation was mild. There was a large fenestrated secundum atrial septal defect measuring 20 mm from the most superior to the most inferior margin with left to right shunt. The right atrium was dilated. Left sided structures and left ventricle ejection fraction were normal.

The patient underwent trans-esophageal echocardiogram and cardiac catheterization which confirmed an atrial septal defect size of 20mm with fenestration. Hemodynamic measurements showed Qp:Qs flow ratio of 2:1. Mean right atrial pressure was 8 mmHg, right ventricle pressure was 20/0 mmHg and pulmonary artery mean pressure was 10 mmHg. A Helex® (Gore) ASD occluder size 25 was deployed successfully with good alignment (Figure 2). There was no residual atrial shunt on transesophageal echocardiogram and no effect on other cardiac structures. Right atrial pressure post procedure did not change. Prophylactic antibiotics and heparin were given.

During the procedure she developed supraventricular tachycardia with a heart rate of 190 beats per minute. This was terminated with Verapamil. The tachycardia recurred one hour after the procedure and was controlled by oral Amiodarone. She was

## CSI 2008 Congenital and Structural Interventions

Frankfurt, Germany

June 25-28 2008

Congenital and Structural Interventions with live case demonstrations from Frankfurt and Hands on Workshops. For more information: <http://www.csi-congress.org/>



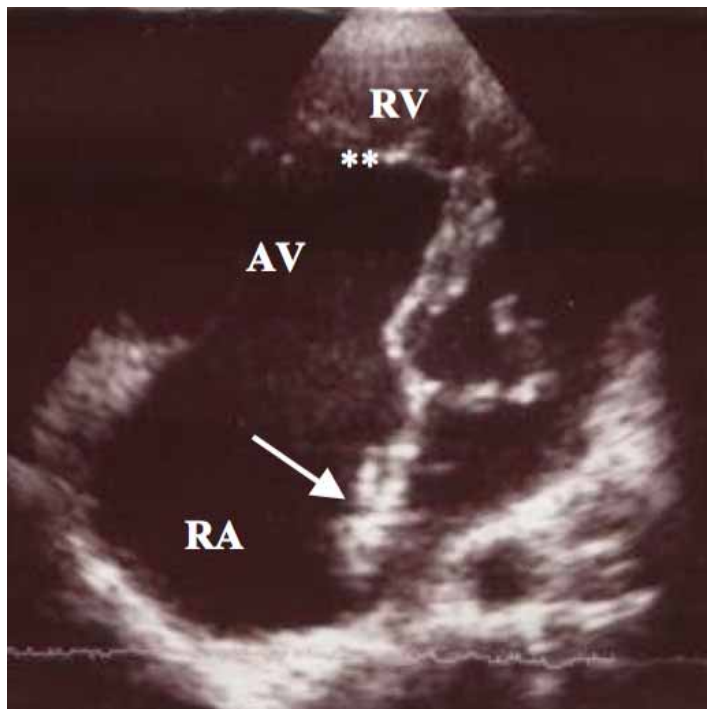



Figure 2. Modified 4 chamber view of patient no. 2 showing Helix device aligned with the interatrial septum (arrow). Displaced tricuspid valve (stars) and atrialized right ventricle (RA: right atrium, AV: atrialized right ventricle, RV: right ventricle).

discharged 48 hours after the procedure in sinus rhythm on Amiodarone and aprin 50 mg once a day. On follow-up at 2, 6 and 8 months, she was asymptomatic, in sinus rhythm and echocardiography showed mild tricuspid regurgitation, and no residual atrial septal defect. After six months, Amiodarone was discontinued without recurrence of tachycardia.

**Discussion**

Closure of atrial septal defects in patients with Ebstein's Malformation is expected to improve the right volume overload. Surgical atrial septal defect closure is not without risk even in patients with otherwise normal hearts as Garson et al [6] reported the incidence of atrial arrhythmia in up to 12.4% in such patients. Similarly, Bink-Boelkens [7] et al. followed 204 patients who underwent surgical repair of atrial septal defect for 10 years and 18% of these patients developed atrial arrhythmia in the follow up period. Moreover, it has been reported that some cases of Ebstein's Malformation deteriorated after surgical closure of atrial septal defect [8]. There are few reports in the literature about percutaneous atrial septal defect closure in patients with Ebstein's Malformation. These reports included patent foramen ovale and small left to right shunt [9,10,11]. Our decision per-



Heart Valves • Cannulae • Oxygenators & Filters  
RVOT Conduits • Ablation Technologies • Pacemakers • ICDs

*Committed to providing more options  
for the lifetime care of patients  
with congenital heart disease.*

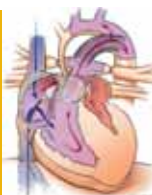

UC200802144 EN © Medtronic, Inc. 2007



**Medtronic**

*Alleviating Pain · Restoring Health · Extending Life*



Two Perspectives.  
Single Focus.



**NATIONWIDE  
CHILDREN'S  
HOSPITAL™**

[www.hybridsymposium.com](http://www.hybridsymposium.com)

June 16-18, 2008

Columbus, OH

**“Our experience suggests that transcatheter atrial septal defect closure in selected patients with Ebstein's Malformation results in a good short-term outcome.”**

form interventional catheterization was based on the patient's symptoms, echocardiographic demonstration of a large left to right shunt supported by hemodynamic data obtained during cardiac catheterization. Patient 2 developed supraventricular tachycardia during catheter manipulation in the atria. It was controlled with Amiodarone which was weaned successfully after 6 months. Gabriella Agnoletti et al [9] reported experience with 4 patients with Ebstein's Malformation who had atrial septal defect catheter closure. One patient needed ablation therapy after the closure. This raises the question of whether all patients with Ebstein's Malformation should routinely have electrophysiologic catheterization prior to interventional treatment. Clearly further studies to look at the long-term results are needed.

Short-term follow up showed improving symptoms in both of our patients and no deterioration in tricuspid valve function. Our experience suggests that transcatheter atrial septal defect closure in selected patients with Ebstein's Malformation results in a good short-term outcome.

#### References

1. Sulafa KM Ali, Nuha AGM Nimeri. Echocardiographic and clinical features of Ebstein malformation in Sudanese children. *Cardiol Young* 2006; 16: 147–151.
2. Keith JD, Rowe RD, Vlad P. Heart disease in infancy and childhood. Macmillan, New York, 1958, p 314.
3. Sealy WC. The cause of the hemodynamic disturbances in Ebstein's anomaly based on observations at operation. *Ann Thorac Surg.* 1979 Jun;27(6):536-46.
4. Berger F, Ewert P, Bjornstad PG et al. Transcatheter closure as standard treatment for most interatrial defects: experience in 200 patients treated with the Amplatzer Septal Occluder. *Cardiol Young.* 1999;9:468-73.
5. Fischer G, Stieh J, Uebing A, Hoffmann U, Morf G, Kramer HH. Experience with transcatheter closure of secundum atrial septal defects using the Amplatzer septal occluder: a single centre study in 236 consecutive patients. *Heart.* 2003 Feb;89(2):199-204.
6. Garson AJ, Bink BM, Hesslein PS. Atrial Flutter in the young; a collaborative study of 380 cases. *J AM Coll Cardiol* 1985;6:871.
7. Bink-Boelkens MT, Velvis H, Vander Heidi JJ. Dysrhythmias after atrial surgery in children. *Am Heart J* 1983;106:125.
8. Deterioration of Ebstein disease after surgical closure of atrial septal defect. *Jpn J surg* 1982, 12(2):126-9.
9. Gabriella Agnoletti, Younes Boudjemline, Phalla Ou, Damien Bonnet and Daniel Sidi. Right to left shunt through interatrial septal defects in patients with congenital heart disease: Results of interventional closure. *Heart.* 2005 Nov 3.
10. Atiq M, Lai L, Lee KJ, Benson LN. Transcatheter closure of atrial septal defects in children with a hypoplastic right ventricle. *Catheter Cardiovasc Interv.* 2005 Jan;64(1):112-6.
11. Percutaneous closure of a patent Foramen ovale, single centre experience using different types of devices and mid-term outcome. *Acta Cardiologica* 2005 Oct, 60(5):515-9.

**CCT**

#### Corresponding Author

Sulafa KM Ali, MD, FACC, FRCPC  
Sudan Heart Centre  
Paediatric Cardiology Department.  
Sudan Heart Centre  
PO Box 11917  
Khartoum, Sudan  
Phone: 00249 183 232137 ext 125  
Fax: 00249183 232135

[sulafakhalid2000@yahoo.com](mailto:sulafakhalid2000@yahoo.com)

Mohammed T. Numan, MD  
Hamad Medical Corporation  
Paediatric Cardiology Department  
PO Box 3050  
Doha-Qatar  
Phone: +9744393800  
Fax: +9744391622

[mtnuman@yahoo.com](mailto:mtnuman@yahoo.com)



**Parent Heart Watch**

PROTECTING KIDS FROM SUDDEN CARDIAC ARREST

[www.ParentHeartWatch.org](http://www.ParentHeartWatch.org)

The members of Parent Heart Watch advocate for awareness and change- all with the goal of protecting children from SCA

**Parent Heart Watch**

P.O. Box 237

Geneva Ohio 44041

Contact Person: Linette Derminer,

[linette@parentheartwatch.org](mailto:linette@parentheartwatch.org)

440-466-0417

# Rady Children's Hospital / University of California San Diego Cardiovascular Team Returns to Siem Reap and to the Cambodian Children with PDA

By Susan T. Grossfeld, BS and Paul D. Grossfeld, MD



Figure 1. PDA patients and their parents in the surgery ward at Angkor Hospital for Children.

Having successfully completed our first medical mission to Cambodia in the summer of 2006, our team was enthusiastic to return and provide much needed PDA ligations to the children of this congenial and welcoming Southeast Asian country. As eager as we were to go back to Angkor Hospital for Children in Siem Reap, we found the Cambodian medical team excited to have us return as their backlog of cardiac patients continues to grow. On October 11, 2007 our ambitious and ebullient medical team from the University of California, San Diego and Rady Children's Hospital San Diego arrived in Siem Reap, Cambodia to be greeted by the staff at Angkor Hospital for Children.

This year's mission was once again made possible by Variety Children's Lifeline's dedication to supporting medical missions for children in third world countries, as well as their commitment to hospital staff education and to achieving a self sustaining medical facility. Variety Children's Lifeline is based in Solana Beach, California and was founded in

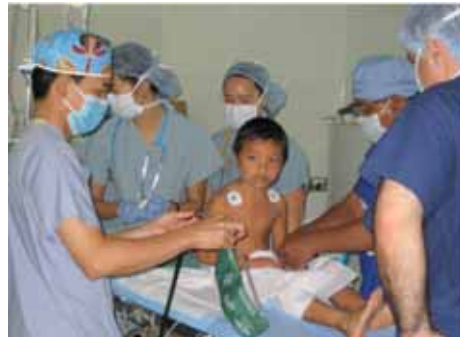

Figure 2. PDA patient Nuon Sokny being prepped for her surgery.

1982. Supported strictly by individual donations, Variety Children's Lifeline founder, Salah Hassanein has supported previous missions to Chile, Nicaragua, India, Panama, Peru, and several African and former Soviet countries.

### The Mission Team

This year's energetic and enthusiastic team of 12 included pediatric cardiologist Paul Grossfeld, MD; cardiothoracic surgeon Jolene Kriett, MD; cardiothoracic surgeon Michael Madani, MD; anesthesiologist Sandra Saw, MD; anesthesiologist Gloria Cheng, MD; respiratory therapist Phillip Panzarella; echo tech William Elias; cardiac intensive care nurse Stephanie Moriarty; cardiac intensive care nurse Sharon Levy; OR nurses Lourdes Pugeda and Mitchell McMurray; and program coordinator/photographer Susan Grossfeld.

### The Cardiac Kids at Angkor Hospital for Children

Angkor Hospital for Children is supported by the non-profit, New York-based group, Friends Without a Border. Friends and Angkor Hospital for Children are commit-

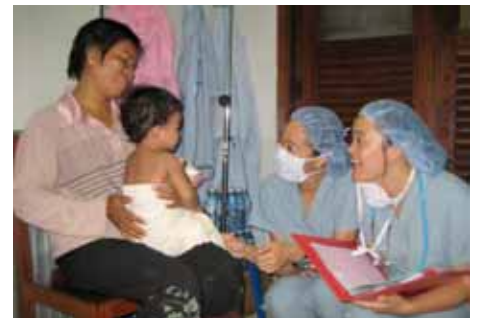

Figure 3. Anesthesiologists Drs. Gloria Cheng and Sandra Saw review the chart of Chy Seavinh.

ted to improving the health and future of Cambodia's children by providing pediatric care and medical education. Additionally, Angkor Hospital for Children is the only accredited teaching hospital in Cambodia.

Along with the San Diego team, there are also cardiology teams from Singapore and Australia traveling to Siem Reap annually to perform PDA ligations. We would have expected that the backlog of patients with PDAs would have been reduced to nothing, but Angkor Hospital for Children is



Figure 4. Pediatric cardiologist Dr. Paul Grossfeld reviews chest X-rays in the radiology room of Angkor Hospital for Children.



**PICS-AICS 08** July 20-23, 2008  
Bellagio, Las Vegas  
PEDIATRIC AND ADULT INTERVENTIONAL CARDIAC SYMPOSIUM

For information, registration, and abstract submission go to: [www.picsymposium.com](http://www.picsymposium.com)

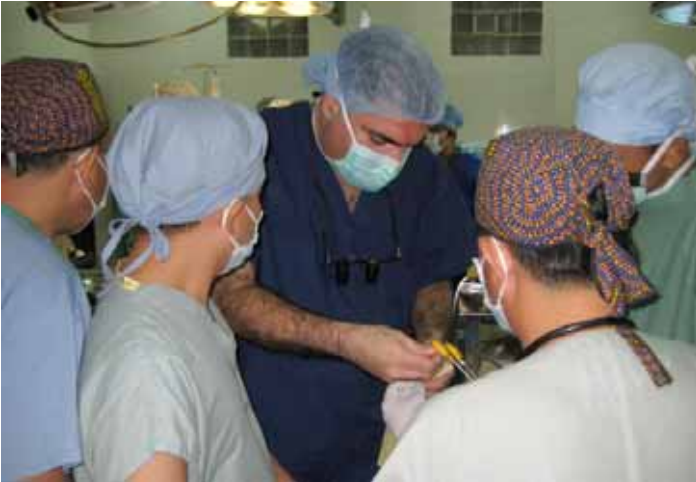

Figure 5. Cardiothoracic surgeon Dr. Michael Madani demonstrates delivery of surgical clip to AHC's surgeons Drs. Vann Ty and Sar Vuthy.

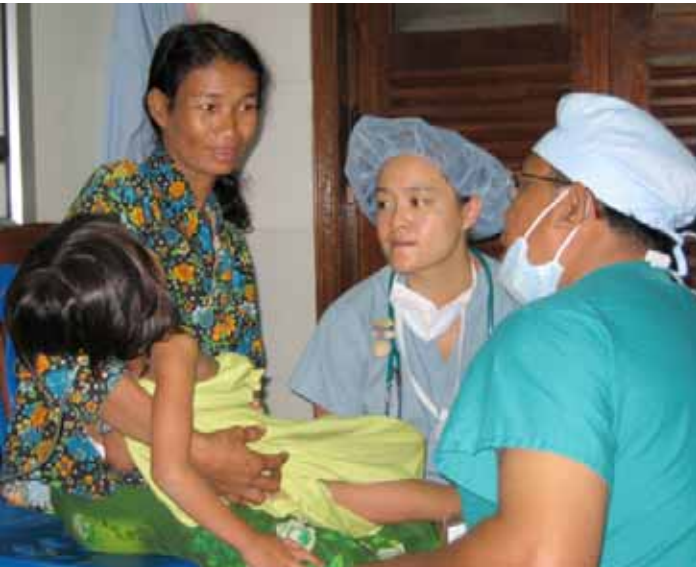

Figure 6. Souem Chreb's anxious mother brings her daughter in to the operating room.

experiencing an increase in the number of PDA cases as well as most of the other congenital heart defects. As children come to AHC for their ligations and then return home to their rural villages, the other parents in the villages are witnessing first hand the miracles of modern medicine. Traditional remedies and cures are still mainstream for the majority of Cambodians too poor to afford the luxury of being seen by a licensed physician in a con-

# CONTEGRA<sup>®</sup>

## Pulmonary Valved Conduit



A natural tissue conduit  
worthy of your pediatric  
RVOT needs

**CONTEGRA<sup>®</sup> Pulmonary Valved Conduit**

Indications: See "Humanitarian Use Device" section below.

**Contraindications:** None known. **Warnings/Precautions/Side Effects:** Acceptable clinical performance has been established for the CONTEGRA conduit in pediatric patients under the age of 10. Because of the possibility that complications of the device could become apparent only after extended use, a benefit-risk consideration of the long-term use of the CONTEGRA conduit in pediatric patients over 10 years of age is particularly important. General complications reported with valved conduits and biological tissue valves implanted in the heart include: hemorrhage, bleeding diathesis due to use of anticoagulants, residual or increasing transvalvular gradients, progressive neointimal thickening and peeling, progressive stenosis and obstruction, progressive pulmonary hypertension, graft infection, endocarditis, regurgitation, hemolysis, valve malfunction, physical or chemical deterioration, thromboembolism, thrombus, conduit dilatation. For additional information, please refer to the instructions for use provided with the product. **CAUTION:** Federal law (USA) restricts this device to sale by or on the order of a physician.

**\*Humanitarian Use Device:**

Authorized by Federal law for use in patients under 18 years of age for correction or reconstruction of the Right Ventricular Outflow Tract (RVOT) in the following congenital heart malformations: Pulmonary Stenosis, Tetralogy of Fallot, Truncus Arteriosus, Transposition with Ventricular Septal Defect (VSD), Pulmonary Atresia. In addition, the CONTEGRA Pulmonary Valved Conduit is indicated for the replacement of previously implanted but dysfunctional pulmonary homografts or valved conduits. The effectiveness of this device for these uses has not been demonstrated.

UC200811915 2/11 © Medtronic, Inc. 2007



**Medtronic**

*Alleviating Pain • Restoring Health • Extending Life*

**CSI 2008 Congenital and Structural Interventions**  
Frankfurt, Germany June 25-28 2008

Congenital and Structural Interventions with live case demonstrations from Frankfurt and Hands on Workshops. For more information: <http://www.csi-congress.org/>



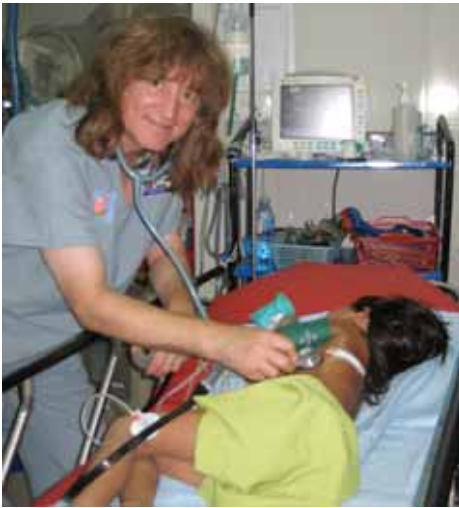

Figure 7. Respiratory therapist Phil Panzarella monitors Souem Chreb in the recovery room.

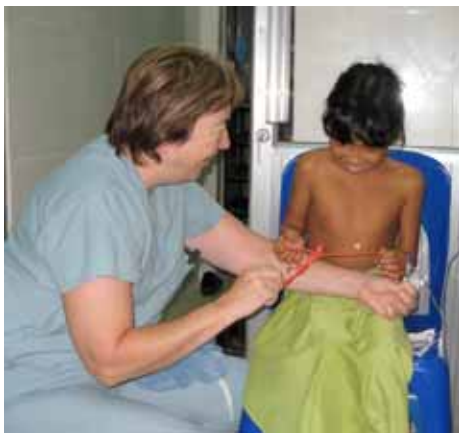

Figure 8. Cardiothoracic surgeon Dr. Jolene Kriett helps to ease pre-op apprehensions of Channa Vy.

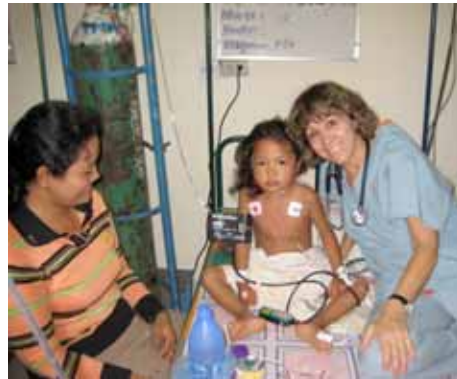

Figure 9. Cardiac intensive care nurse Stephanie Moriarty with Rachna Vy just a couple of hours after her surgery.

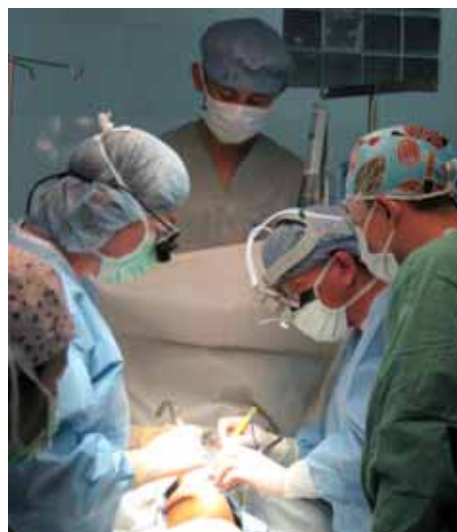

Figure 10. Angkor Hospital for Children's surgeon Dr. Sar Vuthy performs surgery while Dr. Jolene Kriett assists.



Figure 11. Mission coordinator Susan Grossfeld with PDA patient Nuon Sokny on her discharge day.

ventional medical facility. Upon returning to their villages, the now "cured" children are important proof that modern medicine can, indeed, help their children and that these treatments are available to those in need. As village members and those from surrounding villages hear of the treatments available and witness for themselves the remarkable transformations these treatments yield, they began to find ways to get previously undiagnosed children or diag-


nosed children of skeptical parents to come to AHC for evaluations and treatment.

One such patient was Chreb Soeum, a five year old female diagnosed four years ago with a PDA of approximately 4mm. For 4 years, AHC's Dr. Lyda Luy has been trying to schedule Chreb for a ligation when a visiting medical team comes to AHC, but Chreb's mother was too skeptical and afraid to bring her daughter in for

surgery. Residing in Chreb's village are a couple of PDA children treated by the San Diego team during last year's mission that are doing extremely well and, as a result, Chreb's mother finally summoned the courage to bring her daughter in for surgery.

The Vy family traveled for two days to reach Angkor Hospital for Children so that daughters Rachna, 4 years old, and Channa, 8 years old could undergo PDA ligations. Only able to walk about 50 meters or so before tiring, the two girls were treated for years by the rural village doctor for dehydration and respiratory illness. As the years went by and the girls failed to improve, Rachna and Channa's mother took them to a doctor in Battambang who detected heart murmurs and referred them to AHC. Desperate because they could no longer afford the \$2.50 per day for the girls' medication costs, Rachna and Channa's parents were looking for someone to adopt the two girls.

This year the San Diego team saw children that had traveled from as far away as the Vietnam border. Patients and their parents make their way to the hospital by any means available with some even



**Children's  
Cardiomyopathy  
Foundation**

In support of infants, children and teens with pediatric cardiomyopathy

CHILDREN'S CARDIOMYOPATHY FOUNDATION

P.O. Box 547, Tenafly NJ 07670

Tel: 201-227-8852 info@childrenscardiomyopathy.org www.childrenscardiomyopathy.org

"A Cause For Today.... A Cure For Tomorrow"

hitching rides across Cambodia's rugged terrain. As word spreads of the capabilities available at AHC, it is expected that the overall number of patients will only increase across all specialties.

**Patients at a Glance**

Dr. Lyda, the self-trained pediatric cardiologist at AHC, had initially screened the PDA patients and recommended 21 patients for PDA surgery. We performed additional screenings including a complete history, physical and echocardiogram. We determined that all 21 patients were amenable to undergo surgical closure of their PDA, quite an impressive testimony to Dr. Lyda Luy's expertise. The ages of the patients ranged from four months to 12 years and the weights ranged from 4.4-31kg. There were 14 girls and 7 boys, including the two sisters. Most of the patients were failing to thrive and were overtly symptomatic, despite receiving an aggressive regimen of anti-congestive medications. One child was only able to walk about ten steps before experiencing shortness of breath.

**During Surgery**

On our initial mission, our surgeons performed ligations using sutures. This turned out to be a tedious, oftentimes stressful approach, given the fact that we did not have cardiopulmonary bypass backup available in the event of a catastrophic bleed. Consequently, on this mission our surgeons elected to use surgical hemoclips to occlude the PDAs. The PDA sizes ranged from 4-18mm. In general, they were "short and fat" and in some cases, resembled an aortopulmonary window. Interestingly, the two siblings had the two largest PDAs and all but the three largest PDAs were completely occluded using surgical clips. The three largest PDAs were occluded using a combination of clips and sutures. Only these three had tiny, 1mm residual shunts. Four patients experienced a hemothorax and one patient experienced a pneumothorax requiring chest tube placement, resulting in a slightly prolonged hospitalization. Without a doubt, the use of the hemoclips expedited the procedure. The average operating time was 35 minutes, and the initially skeptical AHC staff emerged impressed by the rapidity and success of this approach.


**Happy Endings....Once Again!**

The 21 surgeries were performed over three and one half days and all patients did exceptionally well. All 21 patients were discharged home within one to three days after surgery and all were discharged prior to the departure of the San Diego team.


Chreb Soeum's 4mm PDA was clipped off in a surgery that took all of 25 minutes. When I walked back into the surgery ward to inform her mother that the surgery was over and went very well, Chreb's mother was beside herself with relief and incredulous that her daughter's future was changed in such a short period of time. One hour after leaving her daughter in the operating room, Chreb's mother sat beside her on her cot as she awakened, thus ending four years of fear and worry. Thankful and elated, the family went

**MELODY™**  
Transcatheter Pulmonary Valve

**ENSEMBLE™**  
Transcatheter Delivery System




Providing new options  
for the lifetime management  
of patients with congenital  
heart disease



The Melody™ Transcatheter Pulmonary Valve and Ensemble™ Transcatheter Delivery system have received CE Mark approval and are available for distribution in Europe. Additionally, a Medical Device Licence has been granted and the system is available for distribution in Canada. Products are not available for sale in the United States.

UC20080316 EE © Medtronic, Inc. 2007





Two Perspectives.  
Single Focus.



**www.hybridsymposium.com      June 16-18, 2008      Columbus, OH**



back to their village two days after surgery.

Rachna and Channa Vy's PDAs measured 14 and 18 mm respectively, and they were, without a doubt, this year's recipients of the "largest PDAs." Rachna was sitting up on her cot in the surgery ward, 3 hours after her surgery expressing that she was thirsty and hungry. After allowing her some water, Phil Panzarella, and Sharon Levy delighted the little girl with some bubble blowing, while awaiting the completion of Channa's surgery. Early the next morning, the medical team arrived at the hospital to see both girls outside playing in the courtyard while their appreciative and joyous parents looked on.

All 21 children have since returned to Angkor Hospital for Children for follow-up visits, and Dr. Lyda Luy has informed the San Diego team that all the children are doing remarkably well. Hopefully, 2008 will see this group back in Cambodia to meet yet another captivating group of PDA children and to work once again with our friends, the medical staff at Angkor Hospital for Children.

**CCT**

**Corresponding Author**

Paul D. Grossfeld, MD  
 Assistant Adjunct Professor of Pediatrics  
 Division of Pediatric Cardiology  
 Rady Children's Hospital and  
 University of California San Diego  
 3020 Children's Way, MC 5004  
 San Diego, CA 92123 USA  
 Telephone: 858-966-5855  
 Telefax: 858-571-7903

pgrossfeld@ucsd.edu

Susan T. Grossfeld, BS

**JUNE MEDICAL MEETING FOCUS**

**The Third International Symposium on the Hybrid Approach to Congenital Heart Disease (ISHAC)**

*"Two Perspectives. Single Focus"*

June 16-28, 2008

Columbus, OH USA

[www.hybridsymposium.com](http://www.hybridsymposium.com)

**Keynote addresses:** Edward L. Bove, MD, University of Michigan Health System, and Terry D. King, MD, FAPP, FACC, FACCP, St. Francis Medical Center.

Learn about the latest clinical and research developments from around the world. ISHAC has something for everyone – from tips on starting a hybrid program to follow-up studies on the post-interventional successes, challenges and complications.

Skills Workshop on June 16 at the University Laboratory Animal Resources Experimental Surgical Suites (ULAR). In addition to podium presentations, seven live cases will be broadcast from Nationwide Children's Hospital and ULAR (Columbus) and Rush University Medical Center (Chicago). Attendees can actively participate using the audience response system.

**Program Directors:** John P. Cheatham, MD and Mark Galantowicz, MD

**Workshop Directors:** Ralf J. Holzer, MD and Alistair Phillips, MD

**Program Co-Director:** Sharon L. Hill, MSN, ACNP-BC

**Faculty:** Includes Zahid Amin, MD; Renato Assad, MD; Emile Bacha, MD; John Bauer, PhD; Philipp Bonhoeffer, MD; Edward L. Bove, MD; Redmond Burke, MD; Qi-Ling Cao, MD; Mario Carminati, MD; Jeffrey A. Feinstein, MD, MPH; Craig E. Fleishman, MD; Ziyad M. Hijazi, MD; Frank F. Ing, MD; Terry D. King, MD; Achi Ludomirsky, MD; Doff McElhinney, MD; Charles E. Mullins, MD; Carlos Pedra, MD; Simone Fontes Pedra, MD; Alistair Phillips, MD; Shakeel Qureshi, MD; Daniel Rowland, MD; Dietmar Schranz, MD; Nikolay V. Vasilyev, MD, and Gil Wernovsky, MD to mention only a few.

See upcoming special mid-April issue from *Congenital Cardiology Today* on ISHAC.

**View the entire 45-page "PFO-ASD Closure**

**How to Treat and with What" by Horst Sievert, MD**

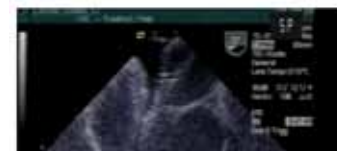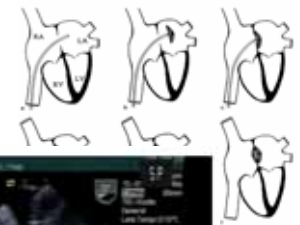**Presentation on the web at:**  
[www.CongenitalCardiology.com/PFO.pdf](http://www.CongenitalCardiology.com/PFO.pdf)

Presentation Includes:

- Devices
- Step-by-Step
- Balloon Sizing
- New Devices
- Technical Considerations
- Tips and Tricks
- Most Common Problems with Large ASDs
- Limitations
- And more....

**Step by Step**

- Local anesthesia
- Transvenous 8-11 F sheath
- 10,000 E Heparin
- Multipurpose catheter → pulmonary vein
- Stiff wire
- LAO projection
- Balloon size
- Device imp
- < 30 min
- Hospital st



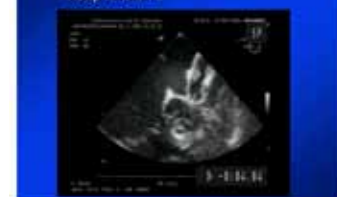**Tips and Tricks**

Large ASD's

Device selection

- Do not over-size device by more than 2-4 mm
- Larger devices may perforate

- Rotate the sheath clock-wise
- Keep tension !!



**The Anthony Bates Foundation**

[www.AnthonyBates.org](http://www.AnthonyBates.org)

**Anthony Bates Foundation**

428 E. Thunderbird Rd., # 633  
 Phoenix, AZ 85022  
 Tel: 602-482-5606

Sharon Bates  
[sharon@anthonybates.org](mailto:sharon@anthonybates.org)

*Education and awareness of the leading killer of young people, HCM, Hypertrophic Cardiomyopathy, through organizing and training in cardiac screening programs for young people everywhere.*

## Medical News, Products and Information

### Patients Appear to Have Lower Rates of Survival if In-Hospital Cardiac Arrest Occurs During Nights and Weekends

Patients who have an in-hospital cardiac arrest at night or on the weekend have a substantially lower rate of survival to discharge than hospitalized patients who experience a cardiac arrest during day/evening times on weekdays, according to a study in the February 20, 2008 issue of JAMA.

The detection and treatment of cardiac arrests may be less effective at night because of patient, hospital, staffing and response factors. If in-hospital cardiac arrests are more common or survival is worse on nights and weekends, this information could have important implications for hospital staffing, training, care delivery processes and equipment decisions, according to background information in the article.

Mary Ann Peberdy, MD, of Virginia Commonwealth University, Richmond, VA, and colleagues evaluated survival rates for adults with in-hospital cardiac arrest by time of day and day of week. The study included data on 86,748 adult, in-hospital cardiac arrest events occurring at 507 medical/surgical hospitals participating in the American Heart Association's National Registry of Cardiopulmonary Resuscitation from January 2000 through February 2007. The researchers examined survival from cardiac arrest in hourly time segments, defining day/evening as 7:00 a.m. to 10:59 p.m., night as 11:00 p.m. to 6:59 a.m., and weekend as 11:00 p.m. on Friday to 6:59 a.m. on Monday.

A total of 58,593 cases of in-hospital cardiac arrest occurred during day/evening hours (including 15,110 on weekends), and 28,155 cases occurred during night hours (including 7,790 on weekends).

The researchers found that rates of survival to discharge (14.7% vs. 19.8%), return of spontaneous circulation for longer than 20 minutes (44.7% vs. 51.1%), survival at 24

hours (28.9% vs. 35.4%), and favorable neurological outcomes (11.0% vs. 15.2%) were substantially lower during the night compared with day/evening.

Survival to discharge at night was similar during the week (14.6%) and weekends (14.8%). Survival during day/evening weekdays (20.6%) was higher than on weekends (17.4%).

"The principal finding of this study was that survival to discharge following in-hospital cardiac arrest was lower [when the arrest occurred] during nights and weekends compared with day/evening times on weekdays, even after accounting for many potentially confounding patient, arrest event, and hospital factors," the authors write.

"The mechanism for the decreased survival during the night is likely multifactorial, potentially including biological differences in patients as well as health care staff and hospital staffing and operational factors. These data suggest the need to focus on night and weekend hospital-wide resuscitation system processes of care that can potentially improve patient safety and survival following cardiac arrest," the researchers conclude.

### Why Are so Many Children on the Road to Heart Disease?

We teach our children how to walk, talk and go to the bathroom, but do we teach them how to eat right? National statistics show that many of us do not. According to the American Obesity Association, an alarming 15.5% of children between the ages of six and eleven are considered obese, putting them on a collision course with the nation's biggest killer: heart disease. The power of preventing such a tragedy lies in the hands of parents, according to pediatric health experts.

"Parents are the gatekeepers and the role models for their children's eating and exercise habits," says Marjorie Milici, MD, pe-

diatrician on the medical staff at Baylor University Medical Center at Dallas.

"Chronic diseases, such as obesity, heart disease and cancer, which take decades to develop, have their roots in childhood, when exercise and eating behaviors are being learned," adds Dr. Milici.

Starting at a very young age, children should begin learning about proper nutrition and exercise. The American Heart Association (AHA) says that children age two and older should eat at least five servings of fruits and vegetables daily, as well as a variety of other foods low in saturated fat and cholesterol, in order to promote cardiovascular health.

"It's up to parents to help their children control the factors that they can, such as diet and exercise," says Dr. Milici. "Children should get at least 30 minutes of exercise five days a week. Lack of exercise prevents the breakdown of bad cholesterol in our bodies. Combined with a high-fat diet, it can lead to health problems such as elevated cholesterol levels, heart disease and diabetes when children are older."

**A Guide for Parents:** Kids are getting too much of the bad stuff and not enough of the good:

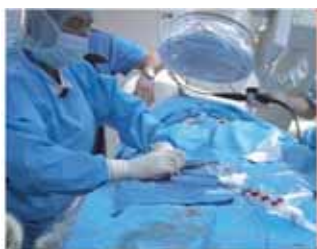#### TOO MUCH/TOO MANY...

- sedentary time
- busy time
- calories found in lower-nutrient foods
- sugary beverages

#### NOT ENOUGH...

- physical activity
- rest or downtime (To increase their energy, children usually eat more when they're tired.)
- fiber, vitamin C, calcium, iron
- low-fat dairy products

For more information visit [www.BaylorHealth.com](http://www.BaylorHealth.com).



### Watch LIVE CASES from Congenital Cardiology Today

[www.CHDVideo.com](http://www.CHDVideo.com)

Presented courtesy of:

The Pediatric and Adult Interventional Therapies for Congenital and Valvular Disease (PICS)  
and

The 6th International Workshop on Interventional Pediatric Cardiology (Workshop IPC)

Watch a Percutaneous Valve Implantation, a Perimembranous VSD Closure or both

# Highlights from the XVI International Parma Echo Meeting

By Umberto Squarcia MD, FACC

As in the past years, between the 27th and the 29th of June, the Section of Pediatric Cardiology of the University of Parma hosted the XVI International Parma Echo Meeting at the University Campus Science Area.

Many specialists and students in the field of neonatal and pediatric cardiology came from many countries to attend our meeting.

The program had sessions on the clinical uses of the strain and strain rate, the assessment of congenital heart diseases with the 3D echo, the evaluation of diastolic function and of the prosthetic valve.

Dr. Hagler discussed the application of the intracardiac echocardiography in the cath lab and its possible application during the percutaneous closure of ASD.

Dr. Tchana talked about the new therapies used for the treatment of the recurrent pericarditis. He presented a new therapeutic protocol which includes steroids, immunomodulating drugs and also monoclonal antibodies.

The assessment of the systolic ventricular function and the strain assessment of the ventricle were presented by Dr. Sanders, Dr. Mertens, and Dr. Vogel. They provide a complete overview on the use of this relatively new technique for the assessment of the global and regional systolic function of the two ventricles. The strain and the strain rate provide also a better knowledge of the left ventricle dynamic.

Dr. Miller presented the assessment of the diastolic function and the echo assessment of the prosthetic valves.

Dr. Shirali provide a new insight of the conotruncal malformation, AV canal defects and VSD studied by the 3D echo.

Two Magistral Lectures were presented during the Meeting. The first Lecture was dedicated to Dr. Fergus Macartney one of the Stars of the history of Pediatric Cardiology. The lecture was given by Dr. Douglas D. Mair, formerly colleague and friend of Prof. Macartney at the Mayo Clinic.

## JUNE MEDICAL MEETING FOCUS

### CSI 2008

#### **Congenital and Structural Interventions**

*with live case demonstrations from*

*Frankfurt, Milan and Toronto.*

Frankfurt, Germany

June 25 - 28, 2008

[www.csi-congress.org](http://www.csi-congress.org)

A unique learning experience in congenital and structural heart interventions

#### **Learn How to:**

- Close atrial and ventricular septal defects
- Close post myocardial ventricular septal defects
- Use balloons and stents in coarctation and pulmonary artery stenoses
- How and when to close patent foramen ovale to prevent paradoxical embolism
- Close paravalvular leaks
- Close the left atrial appendage to prevent embolic stroke in atrial fibrillation
- Repair heart valves by catheter techniques
- Implant heart valves percutaneously
- Close large patent ductus and pulmonary av fistulae

#### **Course Director:**

Horst Sievert, MD

Cardiovascular Center Frankfurt

Frankfurt, Germany

#### **Co-Directors:**

Mario Carminati, MD; Shakeel A. Qureshi, MD; Neil Wilson, MD; Nina Wunderlich, MD

#### **International Faculty:**

Zahid Amin, MD; Boulos Asfour, MD; Uros U. Babic, MD; Lee Benson, MD; Farhouch Berdjis, MD; Felix Berger, MD; Peter Block, MD; Philipp Bonhoeffer, MD; Grazyna Brzezinska-Rajzys, MD; Mario Carminati, MD; Joseph DeGiovanni, MD; Mirko Doss, MD; Peter Ewert, MD; Mohammed O. Galal, MD; Marc Gewillig, MD; Ziyad M. Hijazi, MD; Rafael Hirsch, MD; Yen S. Ho, MD; Eric Horlick, MD; Christian Jux, MD; Saibal Kar, MD; Oliver Kretschmar, MD; Trong-Phi Lê, MD; Jozef Masura, MD; Anton Moritz, MD; Michael Mullen, MD; Oliver Ormerod, MD; Jean-Francois Piechaud, MD; Shakeel A. Qureshi, MD; Greg Robertson, MD; Martin Schneider, MD; Dietmar Schranz, MD; Frank Silvestry, MD; Alec Vahanian, MD; Kevin P. Walsh, MD; Jochen Weil, MD; Neil Wilson, MD; Stephan Windecker, MD

1 out of 125 babies born this year will have a congenital heart defect...



...We'll be there to help them in their time of need.

Saving Little Hearts [info@savinglittlehearts.com](mailto:info@savinglittlehearts.com) // [www.savinglittlehearts.com](http://www.savinglittlehearts.com)



The second lecture was given by Sir Magdi Yacoub on the experimental use of the stem cell for creating new heart valves and vessels. The topic of the lecture, "Will tissue-engineered heart valves change the world?" is fascinating, and helps us enter into this new, and not too far, future world.

The Organizing Committee is already planning the next edition of the International Parma Echo Meeting for June 2008 (25–27 June 2008).

The program's main topics will be: fetal imaging and fetal cardiac intervention, ventricular assessment with Doppler tissue imaging and myocardial imaging. One session will be devoted to the 3D echo imaging in CHD, valvular heart disease and quantification in CHD.

Two Magistral Lectures will be held, discussing adult congenital heart disease and the uses of the Ross procedure in complex LVOT obstruction.

A Magistral Lecture in the Opening Ceremony will be dedicated to Dr. Gian Carlo Rastelli. It will be presented by his daughter Dr. Antonella Rastelli.

The highlights of the Social Program will be the Max Mara Gala Dinner, and the Dinner and Music under the Stars of

Mamiano. The Post Congress tour will lead to the Castelli Parmensi.

The complete Scientific and Social Program of the Meeting is available at the site, [www.unipr.it/arpa/echomeet](http://www.unipr.it/arpa/echomeet).

### CCT

*Umberto Squarcia, MD, FACC  
Professore Universitario  
di 1° Fascia  
Chair of Pediatric Cardiology  
Department of Pediatrics  
University of Parma  
Via Gramsci, 14  
43100 Parma, Italy  
Tel: 39 0521 702201  
Fax: 39 0521 702394*

*umberto.squarcia@unipr.it*

**WATCH SELECTED CHD LIVE  
CASE VIDEOS**  
[www.CHDVideo.com](http://www.CHDVideo.com)

### Do you Want to Recruit a Pediatric Cardiologist?

Advertise in Congenital Cardiology Today, the only monthly publication totally dedicated to pediatric and congenital cardiology. For more information, send an email to: [TCarlsonmd@mac.com](mailto:TCarlsonmd@mac.com)

### CONGENITAL CARDIOLOGY TODAY

© 2008 by Congenital Cardiology Today  
ISSN: 1544-7787 (print); 1544-0499 (online).  
© 2007 by Congenital Cardiology Today  
(ISSN 1554-7787-print; ISSN 1554-0499-online). Published monthly. All rights reserved.

#### Headquarters

9008 Copenhaver Dr. Ste. M  
Potomac, MD 20854 USA

#### Publishing Management

Tony Carlson, Founder & Editor

[TCarlsonmd@mac.com](mailto:TCarlsonmd@mac.com)

Richard Koulbanis, Publisher & Editor-in-Chief

[RichardK@CCT.bz](mailto:RichardK@CCT.bz)

John W. Moore, MD, MPH, Medical Editor/

Editorial Board

[JMoore@RCHSD.org](mailto:JMoore@RCHSD.org)

#### Editorial Board

Teiji Akagi, MD

Zohair Al Halees, MD

Mazeni Alwi, MD

Felix Berger, MD

Fadi Bitar, MD

Jacek Bialkowski, MD

Philipp Bonhoeffer, MD

Mario Carminati, MD

Anthony C. Chang, MD, MBA

John P. Cheatham, MD

Bharat Dalvi, MD, MBBS, DM

Horacio Faella, MD

Yun-Ching Fu, MD

Felipe Heusser, MD

Ziyad M. Hijazi, MD, MPH

Ralf Holzer, MD

Marshall Jacobs, MD

R. Krishna Kumar, MD, DM, MBBS

Gerald Ross Marx, MD

Tarek S. Momenah, MBBS, DCH

Toshio Nakanishi, MD, PhD

Carlos A. C. Pedra, MD

Daniel Penny, MD

James C. Perry, MD

P. Syamasundar Rao, MD

Shakeel A. Qureshi, MD

Andrew Redington, MD

Carlos E. Ruiz, MD, PhD

Girish S. Shirali, MD

Horst Sievert, MD

Hideshi Tomita, MD

Gil Wernovsky, MD

Zhuoming Xu, MD, PhD

William C. L. Yip, MD

Carlos Zabala, MD

#### FREE Subscription

Congenital Cardiology Today is available free to qualified professionals worldwide in pediatric and congenital cardiology. International editions available in electronic PDF file only; North American edition available in print. Send an email to [Subs@CCT.bz](mailto:Subs@CCT.bz). Include your name, title, organization, address, phone and email.

#### Contacts and Other Information

For detailed information on author submission, sponsorships, editorial, production and sales contact, current and back issues, see website or send an email to:

[INFO@CCT.bz](mailto:INFO@CCT.bz)