

CONGENITAL CARDIOLOGY TODAY

Timely News and Information for BC/BE Congenital/Structural Cardiologists and Surgeons

Volume 8 / Issue 4

April 2010

International Edition

IN THIS ISSUE

Medtronic Melody® Transcatheter Pulmonary Valve Improving the Quality of Life

by Sharon L. Hill, ACNP-BC, Joanne L. Chisolm, BSN, and John P. Cheatham, MD

~Page 1

Highlights from "The Evolving Concepts in the Management of Complex Congenital Heart Disease II"

by John W. Moore, MD, MPH

~Page 5

Highlights from "The 18th Utah Conference on Congenital Cardiovascular Disease"

by Collin G. Cowley, MD

~Page 9

Abstracts from "The Evolving Concepts in the Management of Complex Congenital Heart Disease II - Part I"

~Page 11

DEPARTMENTS

Medical New, Products and Information

~Page 8

July Medical Meeting Focus

~Page 10

July Medical Meeting Focus

~Page 13

July Medical Meeting Focus

~Page 15

CONGENITAL CARDIOLOGY TODAY

Editorial and Subscription Offices

16 Cove Rd, Ste. 200

Westerly, RI 02891 USA

www.CongenitalCardiologyToday.com

© 2010 by Congenital Cardiology Today
ISSN: 1544-7787 (print); 1544-0499 (online). Published monthly. All rights reserved.

Statements or opinions expressed in Congenital Cardiology Today reflect the views of the authors and sponsors, and are not necessarily the views of Congenital Cardiology Today.

Medtronic Melody® Transcatheter Pulmonary Valve Improving the Quality of Life

By Sharon L. Hill, ACNP-BC, Joanne L.

Chisolm, BSN, and John P. Cheatham, MD

Case Report

Clinical History

The patient is a 34 year old female with Down's Syndrome and complete AV septal defect, pulmonary atresia, and VSD who has been treated her entire life at C.S. Mott Children's Hospital, University of Michigan, at Ann Arbor. She had palliative bilateral modified Blalock-Taussig shunts (MBTS) as an infant and in 1987 had complete AV septal defect repair with RV-PA conduit, patch VSD closure, along with closure of both MBTS. Ten years later, the degenerating RV-PA conduit was replaced with a 24 mm Hancock porcine valve conduit. She had progressive conduit dysfunction with combined stenosis and moderate pulmonary regurgitation along with associated right heart failure with increasing tricuspid regurgitation and tricuspid stenosis. Her family stated that she could no longer walk up a flight of stairs at home, fell asleep spontaneously throughout the day, and had generalized edema on diuretic therapy. She was New York Heart Association Class III-IV. Her pre-catheterization MRI study confirmed conduit degeneration with combined stenosis and regurgitation with right pulmonary artery stenosis, decreased blood flow of 32% to the right lung and 68% to the left lung. She was referred for percutaneous pulmonary valve replacement using the Medtronic Melody® Transcatheter Pulmonary Valve (TPV).

Procedure

Under general endotracheal anesthesia and full heparinization, a right and left hemodynamic cardiac catheterization was performed with angiography. Right ventricular pressure was elevated at 75/0,19 with simultaneous left ventricular pressure of 90/0,12. Her PA pressure was 32/14 with mean of 24 in the left and 26/15 with mean of 20 in right. A right pulmonary artery (RPA) angiogram demonstrated significant RPA branch stenosis at the insertion site of the previous MBTS, involving the right upper and lower lobe

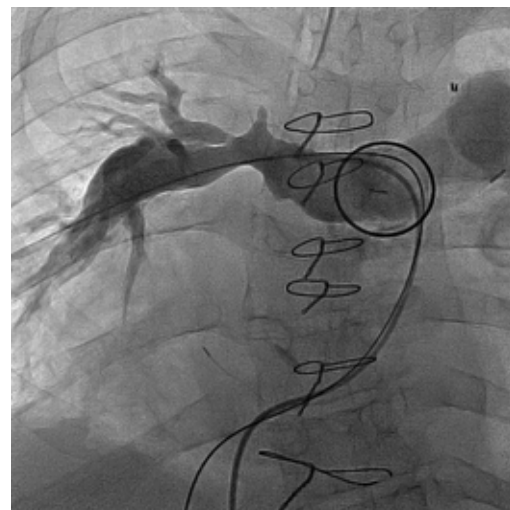

Figure 1. RPA angiogram shows RPA branch stenosis at the insertion site of the previous modified BT shunt.

Do you or your colleagues have interesting research results, observations, human interest stories, reports of meetings, etc. that you would like to share with the Congenital Cardiology community?

Submit a brief summary of your proposed article to: RichardK@CCT.bz

The final manuscript may be between 400-4,000 words, and contain pictures, graphs, charts and tables.

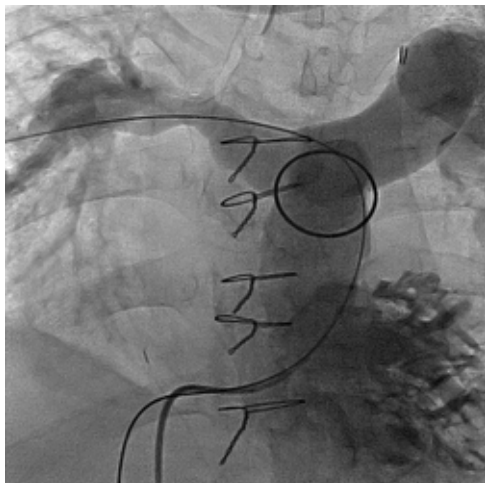


Figure 2. Pulmonary artery angiogram shows moderate pulmonary regurgitation with calcification of the conduit.

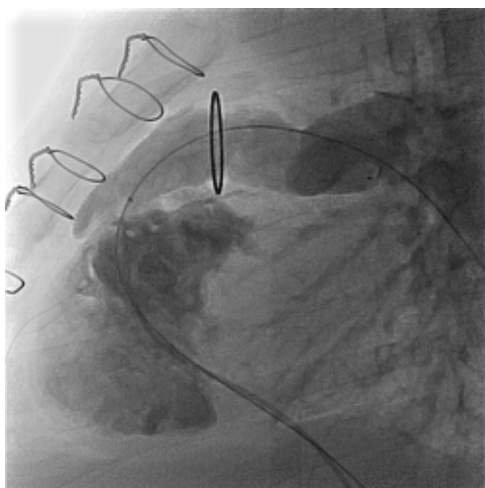


Figure 3. RVOT angiogram shows a dilated and hypertrophied right ventricle with calcified and stenotic Hancock conduit.

branches (Figure 1). This area measured 7-8 mm in diameter, whereas, the rest of the pulmonary artery measured 16 mm. There was moderate pulmonary regurgitation with calcification of the conduit (Figure 2). An angiogram performed in the right ventricular outflow tract (RVOT) showed a dilated and hypertrophic right ventricle with an unusual attachment of the calcified Hancock conduit with almost a hood in the RVOT and some narrowing (Figure 3). The narrowest diameter of the conduit measured 16.3 mm. The aortic root angiogram demonstrated normal coronary arteries which appeared remote

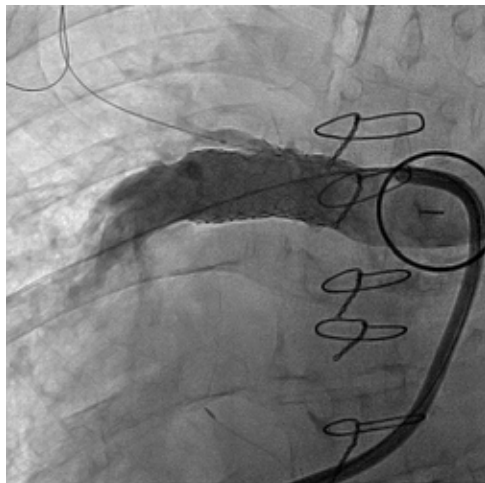


Figure 4. Repeat RPA angiogram s/p implantation with a 36mm long ev3 Max LD stent and balloon angioplasty of the stenotic right upper lobe branch using a 6mm coronary balloon catheter through the open cells of the RPA stent.

from the titanium ring of the valve conduit, therefore little risk for coronary artery compression related to the planned procedure. There was mild aortic insufficiency.

The RPA branch stenosis was treated with a 36 mm long ev3 Max LD stent hand-crimped on a 16 mm X 4 cm BIB delivery catheter followed by redilation using an ATLAS balloon catheter with complete expansion. A repeat angiogram in the RPA demonstrated relief of obstruction. A 6 mm coronary balloon was used to dilate the proximal stenosis of the right upper lobe branch through the open cells of the RPA stent (Figure 4).

Compliance testing of the calcified conduit was performed followed by implantation of the Melody® TPV using the Ensemble Balloon Delivery System as per protocol (Figure 5). A Kevlar-coated ATLAS® balloon catheter was used to completely expand the the stent to 20 mm (Figure 6). Pulmonary artery (PA) pressure recording post implant revealed no significant gradient across the Melody® Valve. There was a 10 mmHg peak systolic gradient across the entry site or attachment of the hooded insertion of the RVOT. Ending RV pressure was 40/4,17 with an LV pressure of 85/4,15. A follow-up PA angiogram using the Multi-Track® angiographic catheter demonstrated no pulmonary regurgitation with excellent positioning of the valve and complete relief

“The patient is a 34 year old female with Down’s Syndrome and complete AV septal defect, pulmonary atresia, and VSD.... She had palliative bilateral modified Blalock-Taussig shunts (MBTS) as an infant and in 1987 had complete AV septal defect repair with RV-PA conduit, patch VSD closure, along with closure of both MBTS. Ten years later, the degenerating RV-PA conduit was replaced with a 24 mm Hancock porcine valve conduit. She had progressive conduit dysfunction with combined stenosis and moderate pulmonary regurgitation along with associated right heart failure with increasing tricuspid regurgitation and tricuspid stenosis.”

of the RPA stenosis with brisk flow into the right and left pulmonary artery branches (Figure 7). An RVOT angiogram was also performed which demonstrated no significant residual stenosis except at the insertion site of the conduit within the RV muscle where there was a 10 mm gradient (Figure 8). An intracardiac echo advanced to the RV outflow tract showed coaptation of the Melody® Valve leaflets and no significant pulmonary regurgitation and a mean gradient of 4-5mmHg (Figure 9). Finally, a “down the barrel” angulation of the AP camera and straight lateral view was recorded as baseline comparison for future images (Figure 10).

At six month follow-up, the patient has improved to New York Heart Association

B | BRAUN

For information, please call 1-800-BRAUN2 (227-2862)

www.bbraunusa.com



Working Together to Develop a Better Tomorrow

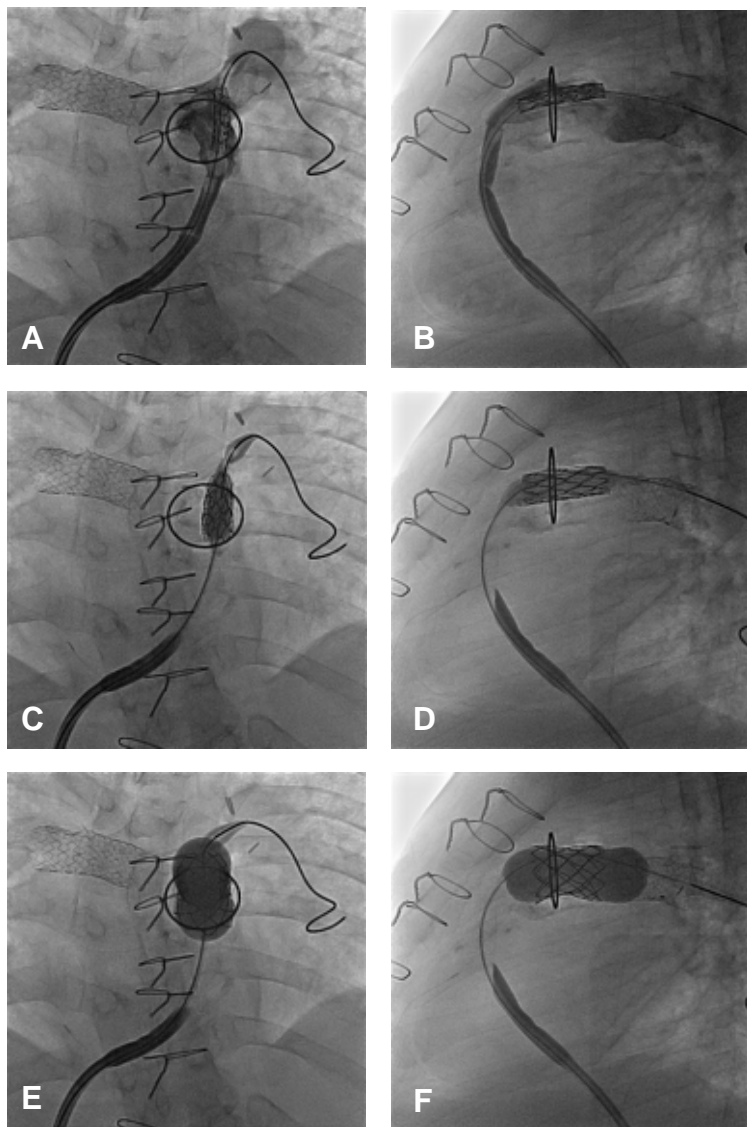


Figure 5. Hand injection for placement of the Melody TPV and Ensemble Balloon Delivery System across the titanium ring in Hancock conduit in AP & Lateral projection (A&B). AP and lateral projections of the inner balloon (C&D) then outer balloon (E&F) of the BIB catheter expanded to 4 atmospheres of pressure.

Class I. Imaging studies demonstrate no change in valve function and no evidence of stent fracture, with 13 mean gradient and no pulmonary regurgitation. The family reports the patient's activity level is markedly increased without any evidence of lethargy. She is asymptomatic and now riding her bicycle, climbing multiple flights of stairs, and walking long distances. She has regained the ability to dance, which she loves and has missed. Her attending cardiologist in Ann Arbor, who has followed her for over 30 years, calls the procedure "a miracle!"

Discussion

Bonhoeffer, et al (2000) reported the first percutaneous transcatheter bovine jugular valve implantation in a conduit in a 12 year old boy with stenosis and insufficiency of a prosthetic RV-PA conduit. Since then, patients with degenerating RV-PA conduits and RV dysfunction have successfully undergone percutaneous transcatheter pulmonary valve implantation using the Medtronic Melody® TPV under CE Mark in Europe and Canada, and more recently under a Food and Drug Administration (FDA) sponsored protocol in the United States (Lurz et al, 2009; Zahn et al, 2010). Recently, a Humanitarian Device Exemption (HDE) was granted. This is a special type of regulatory approval by the FDA for

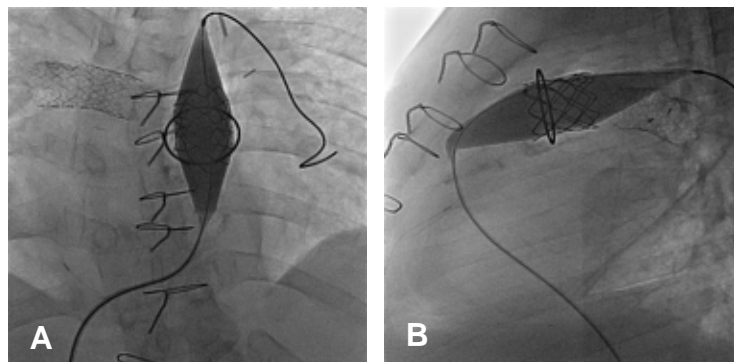


Figure 6. A 20mm x 2cm long Kevlar coated ATLAS balloon catheter inflated to 18 atmospheres of pressure with complete expansion in AP (A) and Lateral (B) view.

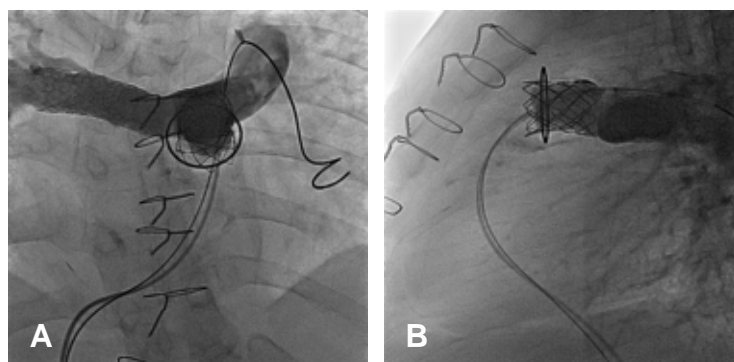


Figure 7. Post PA angiogram in the AP (A) and Lateral (B) projection using a Multi-Track angiographic catheter demonstrated no pulmonary artery regurgitation, relief of the RPA stenosis with brisk flow into the right and left pulmonary artery branches.

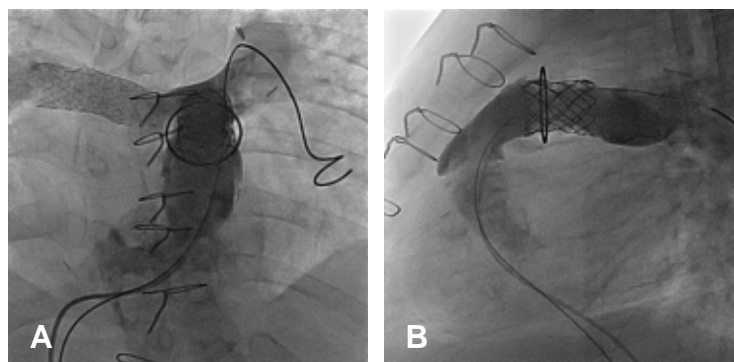


Figure 8. Post RVOT angiogram in the AP (A) and Lateral (B) projection using a Multi-Track angiographic catheter shows the area of mild stenosis (10mmHg gradient) at the insertion site of the conduit within the RV muscle, otherwise no significant residual stenosis.

medical devices which have proven safety and probable benefit, and intended for fewer than 4,000 patients per year. More than 1200 patients in 90 centers worldwide have undergone transcatheter pulmonary valve replacement using the Medtronic Melody® TPV (personal communication, Philipp Bonhoeffer MD, March 2010). This non-surgical option offers an alternative treatment for congenital heart disease patients who have a degenerative RV-PA conduit. Transcatheter pulmonary valve replacement may decrease the number of open heart surgeries needed over the course of a lifetime for many patients. This new interventional procedure can offer patients, who were previously considered inoperable, a competent pulmonary valve with relief of stenosis and regurgitation, as well as improved quality of life. The patients are happy and grateful to regain the ability to perform the activities they love (Figure. 11).

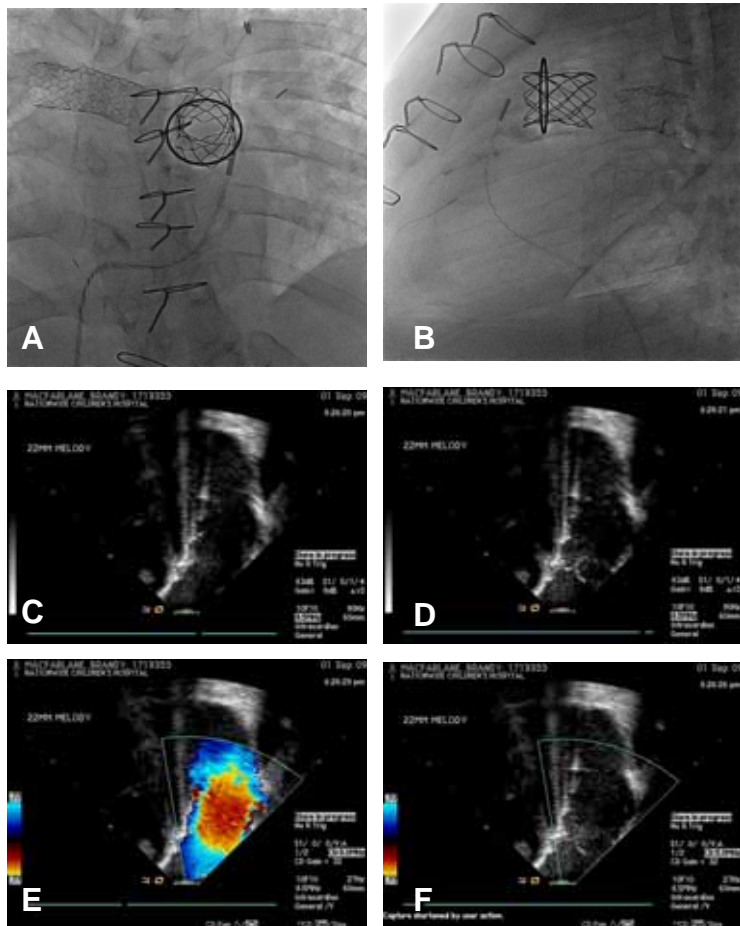


Figure 9. (A&B) Shows placement of the ICE catheter in the RVOT beneath the Melody TPV. ICE imaging shows the valve in the open (C) and closed (D) position with coaptation of the valve leaflets. Color flow Doppler in the open (E) and closed (F) position shows no significant pulmonary regurgitation and a mean gradient of 4-5mmHg.

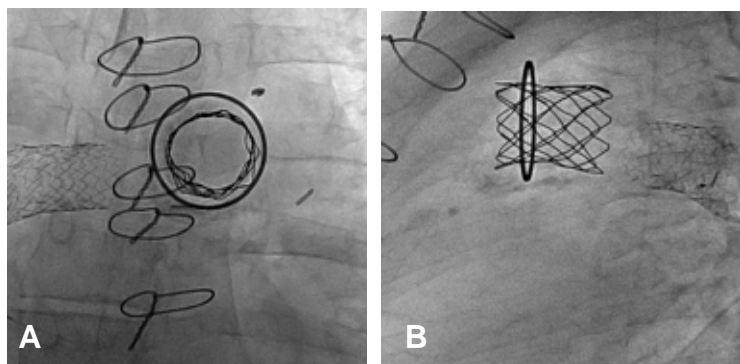


Figure 10. (A) "Down the barrel" and (B) Lateral view post procedure.

Special Acknowledgement: Macdonald "Mac" Dick II, MD and Aimee K. Armstrong, MD; C.S. Mott Children's Hospital.

References

- Bonhoeffer, P., et al. "Percutaneous Replacement of Pulmonary Valve in a Right-Ventricle to Pulmonary-Artery Prosthetic Conduit with Valve Dysfunction." *Lancet* 356.9239 (2000): 1403-5.



Figure 11. Happy patient... returned to dancing and all other activities!

- Lurz, P., P. Bonhoeffer, and A. M. Taylor. "Percutaneous Pulmonary Valve Implantation: An Update." *Expert review of cardiovascular therapy* 7.7 (2009): 823-33.
- Lurz, P., et al. "Percutaneous Pulmonary Valve Implantation." *Seminars in thoracic and cardiovascular surgery. Pediatric cardiac surgery annual* (2009): 112-7.
- Zahn, E. M., et al. "Implantation of the Melody Transcatheter Pulmonary Valve in Patients with a Dysfunctional Right Ventricular Outflow Tract Conduit Early Results from the U.S. Clinical Trial." *Journal of the American College of Cardiology* 54.18 (2009): 1722-9.

CCT

Corresponding Author

Sharon L. Hill, MSN, ACNP-BC
Interventional Nurse Practitioner
Cardiac Catheterization & Interventional Therapy
The Heart Center
Nationwide Children's Hospital
700 Children's Drive
Columbus, OH 43205 USA
The Ohio State University College of Nursing
Tel: 614.722.6124; Fax: 614.722.5030
sharon.hill@nationwidechildrens.org

Joanne L. Chisolm, BSN
Research Coordinator, The Heart Center
Nationwide Children's Hospital
Columbus, OH USA

John P. Cheatham, MD, FAAP, FACC, FSCAI
George H. Dunlap Endowed Chair in Interventional Cardiology
Director, Cardiac Catheterization & Interventional Therapy
Co-Director, The Heart Center
Nationwide Children's Hospital
Columbus, OH USA
Professor, Pediatrics & Internal Medicine, Cardiology Division
The Ohio State University
Columbus, OH USA

Highlights from “The Evolving Concepts in the Management of Complex Congenital Heart Disease II:”

January 14-16th 2010; San Diego, California; Sponsored by Rady Children's Hospital—San Diego and UCSD; Coordinators John Lamberti and John Moore

By John W. Moore, MD, MPH

Our second symposium entitled *Evolving Concepts in the Management of Complex Congenital Heart Disease*, took place in mid-January at the Hyatt Regency Mission Bay Spa and Marina in San Diego.

The first symposium occurred in October 2007, and was a two-day program focusing on surgical management of difficult defects and peri-operative care. Our second symposium was held in mid-January 2010, allowing many attendees to escape harsh winter conditions, stay at a nice bay-side resort and enjoy San Diego's mild Mediterranean climate and many family-oriented attractions. Furthermore, the program was expanded to three days and many sessions were added to provide the audience with a comprehensive cardiology and cardiac surgery program. There were approximately 200 attendees coming from most of the United States; the majority were practicing pediatric cardiologists.

Program Sessions included: Office Cardiology; Cardiomyopathy and Pulmonary Hypertension; Imaging; Electrophysiology; Catheterization; Hypoplastic Left Heart Syndrome; Difficult Surgical Problems; Valvular Heart Disease; and Adult Congenital Heart Disease. The keynote address was given by Jeff Jacobs on the morning of the final day. He discussed the Status and Utility of Clinical Data Bases from the perspectives of quality improvement, research and health care administration.

The Office Cardiology Session featured Victoria Vetter, Lloyd Tani, and Jane Burns. Victoria Vetter discussed ADHD in patients with and without congenital heart disease. She discussed the role of ECG's and the use of stimulant medication. Lloyd Tani provided a case-based discussion of the management of children with aortic and mitral regurgitation. He gave thoughtful advice about the role of medical therapy and the timing of surgery. Jane Burns informed the audience about the current status of Kawasaki Disease research and the latest recommendations for therapy.



Rose Pavillion at Rady Children's Hospital - San Diego, CA



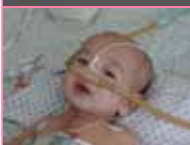
Table at the Faculty Dinner with faculty members: Beth Printz, Joel Kirsch, Howaida El Said, and Jane Burns

The next session dealt with Cardiomyopathy and Pulmonary Hypertension. Speakers included Steven Lipshultz, Daniel Bernstein, and Dunbar Ivy. Steven Lipshultz discussed the Pediatric Cardiomyopathy Registry, and made recommendations for the evaluation and medical treatment for cardiomyopathy patients. A complete discussion of devices for treatment of pediatric heart failure patients and of pediatric cardiac transplantation including the results, patient management and complications encountered after OHT was given by Daniel Bernstein. Dunbar Ivy provided a thorough review of the evaluation and the pharmacological management of pulmonary hypertension.

The Imaging Session was kicked off by Gerald Marx who showed some fantastic 3-D echocardiograms and discussed their clinical utility. Beth Printz showed some cardiac MRI's and CT's and described her considerations in choosing one or the other modality for imaging. Lloyd Tani returned to the podium to discuss the role of routine 2-D and Doppler echocardiography in the evaluation of mitral and aortic regurgitation.

George Van Hare led the Electrophysiology Session. Joel Kirsh discussed Sudden Death and the Channelopathies. George Van Hare laid out treatment for native and post-operative Atrial Ectopic Tachycardia, and Junctional Ectopic Tachycardia. Kevin Shannon

 International Children's Heart Foundation



VOLUNTEER YOUR TIME!

We bring the skills, technology and knowledge to build sustainable cardiac programmes in developing countries, serving children regardless of country of origin, race, religion or gender.

www.babyheart.org



Jenny Boyd and Victoria Vetter



James Perry




James Lock and Scott Kiewer



Gary Webb and John Child



John Lamberti and Joseph Dearani



George Van Hare



John Moore and Anjan Batra

concluded the session with a practical discussion of Device Therapy for Tachyarrhythmia and Heart Failure. He talked about the indications for Bi-Ventricular Pacing and for AICD in children and in adults with congenital heart disease.

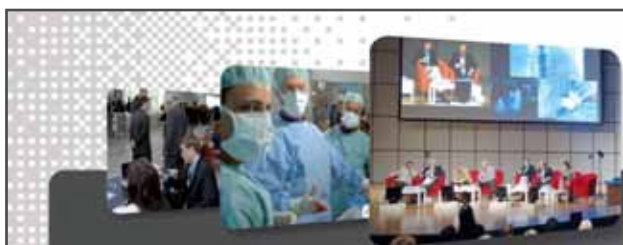The Catheterization Session featured Zahid Amin, Audrey Marshall, and Howaida El Said. Zahid Amin spoke about device closure of VSD, both percutaneous and per-ventricular. He hinted about some new device designs which are still in the drafting stages. Audrey Marshall provided an excellent review of Fetal Interventional Cardiology, including discussions of aortic and pulmonary valvuloplasty, and PFO enlargement and

stenting. Howaida El Said discussed the problems involved in organizing and running a Hybrid program for Hypoplastic Left Heart Syndrome. In Dr. El Said's program hybrid palliation is only offered to high-risk patients. Her talk provided an excellent segue to the Hypoplastic Left Heart Syndrome session which followed immediately thereafter.

The Hypoplastic Left Heart Syndrome (HLHS) Session featured speakers John Cheatham who described the Columbus experience in which Hybrid palliation is offered to all patients with HLHS, and James Tweddell who argued "It's Hard to 'Top' a Well-Done Norwood." Thomas Spray followed with a comprehensive review of what happens after stage I and II procedures in patient with HLHS. He concluded that Fontan completion in this patient group is similar to the single ventricle group at large. A lively panel discussion followed this Session.

Following HLHS, the next Session dealt with Managing Difficult Surgical Problems. Frank Hanley discussed his ground-breaking approach to Management of Patients with One or Two Ventricles and MAPCAS rather than true pulmonary arteries. He also gave Mohan Reddy's talk about the surgical management of the Premature Infant with Complex Congenital Heart Disease. Next, Peter Pastuszko discussed Surgical Strategies to maximize neurological Outcomes after Cardiac Surgery, and Gil Wernovsky gave a very thoughtful talk about the impact of Patient-related, Procedure-related and ICU-related Factors on Long-Term Quality of Life.

On the last day, the first Session dealt with important topics in Valvular Heart Disease. Vaughn Starnes discussed his experience with the Infant Ross/Konno Procedure. James Lock outlined a comprehensive strategy for Incorporating the Percutaneous Pulmonary



CSI - Catheter Interventions in
Congenital & Structural Heart Diseases
July 8-10, 2010 | Frankfurt, Germany

www.csi-congress.org



“Program Sessions included: Office Cardiology; Cardiomyopathy and Pulmonary Hypertension; Imaging; Electrophysiology; Catheterization; Hypoplastic Left Heart Syndrome; Difficult Surgical Problems; Valvular Heart Disease; and Adult Congenital Heart Disease.”

Valve into a Long-Term Patient Care Strategy. Joseph Dearani gave a very clear and comprehensive presentation about Repair of Ebstein's Anomaly of the Tricuspid Valve.

The Final Session covered Adult Congenital Heart Disease. Gary Webb described the challenges involved in establishing an ACHD Program. John Child provided a sweeping case-based discussion of patient care challenges. And, with very little audience attrition, Anjan Batra gave the last talk in which he summarized the management of arrhythmias in this patient population.

Evolving Concepts II adjourned with the satisfied applause of the attendees, and with very positive reviews. We plan to reconvene in January of 2012 with a similar program. Join us for a pleasant and fruitful break from winter at *Evolving Concepts in the Management of Complex Congenital Heart Disease III!*

CCT



John W. Moore, MD, MPH
Professor of Pediatrics
Chief, Section of Cardiology
Department of Pediatrics, UCSD
School of Medicine
Director, Division of Cardiology
Rady Children's Hospital, San Diego
3020 Children's Way, MC 5004
San Diego, CA 92123 USA
(P) 858-966-5855; (F) 858-571-7903
JMoore@rchsd.org


Congenital Cardiology Today will be publishing many of the abstracts from *Evolving Concepts in the Management of Complex Congenital Heart Disease II* in this and the next few issues.

The topics and presenters are:

- How Far Can We Go With VSD Closure? by *Zahid Amin, MD*
- Evolving Concepts in the Management of Arrhythmias in Adults with Congenital Heart Disease by *Anjan S Batra, MD*
- Pediatric Cardiac Transplantation: The Next 25 Years by *Daniel Bernstein, MD*
- Kawasaki Disease Update by *Jane C. Burns MD*
- Assessment of the Hybrid Approach to the Management of HLHS by *John P. Cheatham, MD*
- Late Challenges in Adult CHD – A Case-Based Approach by *John S. Child, MD*
- Surgery for Ebstein's Anomaly by *Joseph A. Dearani, MD*
- Starting a Hybrid Program by *Howaida G. El-Said, MD*
- Management Of Patients With Aorto-Pulmonary Collaterals by *Frank L Hanley, MD*
- Update on Medical Management of Severe Pediatric Pulmonary Hypertension by *D. Dunbar Ivy, MD*
- Clinical Databases: Status and Utility by *Jeffrey P. Jacobs, MD, FACS, FACC, FCCP*
- Sudden Cardiac Death and Channelopathies by *Joel A. Kirsh, MD*
- Diagnosis and Management of Cardiomyopathy in Children by *Steven Lipshultz, MD*
- A Program of Fetal Intervention for Hypoplastic Left Heart Syndrome: Lessons Learned in the First 10 Years by *Audrey C. Marshall, MD*
- 3-D Echocardiography Current Status and Uses by *Gerald R. Marx MD*
- Surgical Strategies to Maximize Neurological Outcomes by *Peter Pastuszko, MD*
- When MRI, When CT by *Beth Feller Printz, MD, PhD*
- Indications for AICD, Anti-Tachycardia PM, Bi-V Pacing by *Kevin Shannon, MD*
- Is the Fontan Procedure Different in HLHS versus Other Single Ventricles? by *Thomas L. Spray, MD*
- The Infant Ross / Konno: Early and Late Results by *Vaughn A. Starnes, MD*
- Management of Children with Aortic or Mitral Regurgitation: Role of Medical Therapy and Timing of Surgery by *Lloyd Y. Tani, MD*
- Role of Echocardiography in the Evaluation of Mitral and Aortic Regurgitation by *Lloyd Y. Tani, MD*
- It's Hard to Top a Well-Done Norwood by *James S Tweddell, MD*
- Treatment of AET and JET – Native and Post-Op by *George F. Van Hare, MD*
- DHD in Patients with and without CHD, Use of Stimulant Medication by *Victoria L. Vetter, MD, MPH*
- Establishing an ACHD Program by *Gary Webb, MD*

SAVE THE DATE
JULY 18–21, 2010

CHICAGO



Medical News, Products and Information

Medtronic Receives FDA Approval for First Replacement Heart Valve Implanted Without Surgery



In a significant development for congenital heart disease patients, Medtronic, Inc. (NYSE: MDT), announced that its Melody® Transcatheter Pulmonary Valve has received US Food and Drug Administration (FDA) approval under a Humanitarian Device Exemption (HDE). This innovative medical device is the first transcatheter heart valve to receive FDA approval.

Delivered through a catheter requiring only a small incision, the Melody valve will benefit children and adults who are born with a malformation of their pulmonary valve, which is the valve between the heart and lungs. These patients often require open-heart surgery to restore effective blood flow to their lungs. Previously, the only way to repair or replace a failed pulmonary valve conduit was through additional surgeries. To date, more than 1,100 patients worldwide have received a Melody valve.

"The Melody Transcatheter Pulmonary Valve is a significant technological breakthrough and offers a reprieve for many patients with congenital heart disease – many of whom are young and will require several heart surgeries over their lifetime," said pediatric cardiologist Dr. William E. Hellenbrand of the New York-Presbyterian Morgan Stanley Children's Hospital and Columbia University Medical Center.

"The Melody valve gives patients with congenital heart disease a new, non-surgical approach to managing their disease."

"This novel technology will improve the lives of thousands of patients in the United States," said Dr. John Liddicoat, VP and General Manager of the Structural Heart division, part of the CardioVascular business, at Medtronic. "Medtronic is leading the development of transcatheter therapies for heart valve disease. FDA approval of the

Melody Transcatheter Pulmonary Valve is evidence of that leadership."

In October 2006, the Melody valve became the first transcatheter valve to receive regulatory approval anywhere in the world when it received the CE (Conformité Européenne) mark. It is now approved by the FDA for use in the United States under an HDE. HDEs are granted for medical devices that have demonstrated reasonable safety and probable benefit, but not clinical effectiveness.

For more information: www.medtronic.com

Top-rated Hospitals Don't Always Have Superior Outcomes

New research published in the January issue of the *Journal of the American College of Surgeons* finds that while popular hospital rating systems can help identify high-quality hospitals for cardiovascular operations, patients can achieve similar outcomes by seeking care at high-volume hospitals closer to home.

"Both the *U.S. News and World Report* and *HealthGrades* quality rating systems are frequently used for hospital marketing. Our study shows that current hospital ratings systems are no better in judging the quality of hospitals than are procedural volumes," according to Nicholas Osborne, MD, Robert Wood Johnson Clinical Scholar, University of Michigan, Ann Arbor.

"These quality ratings are marketed as a tool to help consumers choose the best hospitals. However, the best hospitals are hard to define," Dr. Osborne said. "Procedural volume may represent a good proxy for hospital quality for some high-risk procedures, but continued research is necessary to develop better measures of surgical quality for the public. One promising approach is the American College of Surgeon's National Surgical Quality Improvement Program (ACS NSQIP), a quality initiative aimed at measuring and improving surgical outcomes. ACS NSQIP uses clinical data from patient charts rather than relying on billing data from insurance claims, as most quality rating efforts do. As national and regional quality initiatives like ACS NSQIP expand and develop, these efforts will provide detailed and robust data to help us measure and improve the surgical quality of participating hospitals."

Researchers concluded that hospital volume accounts for as much as 79% of observed differences in hospital quality. Although current ratings systems can identify high-quality hospitals, over-reliance on such ratings may cause patients and their families to choose

facilities more distant from their homes rather than equally performing high-volume hospitals in a closer geographic area.

For more information: www.facs.org.

Edwards SAPIEN XT Transcatheter Valve and Delivery Systems Receive CE Mark

Edwards Lifesciences Corporation announced that it has received CE Mark for its Edwards SAPIEN XT transcatheter aortic heart valve, as well as its NovaFlex transfemoral and Ascendra 2 transapical delivery systems.

The company is beginning a disciplined European launch of the new valve and the 18 French NovaFlex delivery system, and will expand the number of commercial sites utilizing the system throughout the year.

The Edwards SAPIEN XT transcatheter valve enables doctors to replace failing aortic valves without major surgery. The leaflet design of this new valve is modeled after Edwards' clinically proven aortic tissue valves and its cobalt chromium frame provides improved radial strength and, therefore, enhanced circularity. The Edwards SAPIEN XT valve with the NovaFlex transfemoral delivery system is designed to provide easy, precise, balloon-expandable delivery of the valve.

"The Edwards SAPIEN XT valve platform offers best-in-class valve performance with a low-profile delivery system," said Larry L. Wood, Edwards' Corporate VP, Transcatheter Valve Replacement. "We are excited about the new platform and our continued leadership in this transformational technology."

As heart teams continue to gain clinical experience with the Edwards SAPIEN XT valve on the Ascendra 2 transapical delivery system, Edwards will begin introducing that system commercially in Europe during the second quarter. The Ascendra 2 system features a reduced profile, and is designed for improving ease-of-use when delivering the valve through a small incision between the ribs.

The Edwards SAPIEN XT valve is the second commercially available transcatheter valve in the Edwards SAPIEN product portfolio. Edwards transfemoral and transapical transcatheter aortic valve systems, have been available in Europe since 2007. In the United States, the Edwards SAPIEN valve is an investigational device and not yet available commercially.

For more information: www.edwards.com.

Highlights from “The 18th Utah Conference on Congenital Cardiovascular Disease”

By Collin G. Cowley, MD

The 18th Utah Conference on Congenital Cardiovascular Disease convened in the mountainous beauty of Snowbird, Utah February 21-24, 2010. Faculty from across the United States and Australia gathered to present their work and lead discussions on a variety of issues important to the care of children and adults with heart disease.

This year's keynote speaker was Dr Pedro del Nido of Boston Children's Hospital, who presented an excellent and provocative talk on recruitment of the borderline left ventricle. The conference was again organized over a four-day period allowing time during the middle of each day for participants to enjoy the scenic

“This year's keynote speaker was Dr. Pedro del Nido of Boston Children's Hospital who presented his work on recruitment of the borderline left ventricle.”

and recreational opportunities unique to this area. A summary of the speakers and their presentations is included (Table below).



Dr. Cammon Arrington presents his cutting-edge research on advances in our understanding of genotype and phenotype.

18th Utah Conference on Congenital Cardiovascular Disease – Topics and Speakers	
Recruiting the borderline left ventricle	Dr. Pedro del Nido
Optimal methods of preoperative imaging	Dr. Shaji Menon
Surgical strategies for small neonates	Dr. Aditya Kaza
Ventilation strategies for CHD - options and outcomes	Dr. Ira Cheifetz
Perioperative monitoring of cerebral oxygenation	Dr. Madolin Witte
Neuroprotection of neonates with CHD	Dr. Patrick McQuillen
Perventricular VSD Closure	Dr. Geoff Lane
New Technology and the Pulmonary Conduit	Dr. John Hawkins
Advances in the Invasive Treatment of Pediatric Rhythm Disorders	Dr. John Triedman
Transcatheter Interventions For Structural Heart Disease In Adults	Dr. John Whisenant
Anticoagulation in Children - Are We Missing the Clot?	Dr. Gordon Mack
Fetal Diagnosis of CHD - Impact and Outcomes	Dr. Nelangi Pinto
PFO, Strokes and Migraine Headaches in the Pediatric Population	Dr. Rachel McCandless
What's New in Pediatric Heart Transplantation	Dr. Melanie Everitt
Neuropsychological Problems in Children with Heart Disease - Part I	Dr. Richard Martini
Neuropsychological Problems in Children with Heart Disease - Part II	Dr. Lisa Giles
Debate: Comfort Care for HLHS should be offered	Dr. Mike Puchalski
Debate: Comfort Care for HLHS should not be offered	Dr. Phil Burch
Functional Outcomes in Children After Single Ventricle Palliation	Dr. Rick Ohye
Surgical Management of the Failing Fontan Patient	Dr. Constantine Mavroudis
Genetics of Arrhythmias	Dr. Martin Tristani
Advances in our understanding of genotype and phenotype	Dr. Cammon Arrington
Update on Animal Models of CHD	Dr. Deborah Frank
The Science and Practice of Preventing Congenital Heart Defects	Dr. Lorenzo Botto

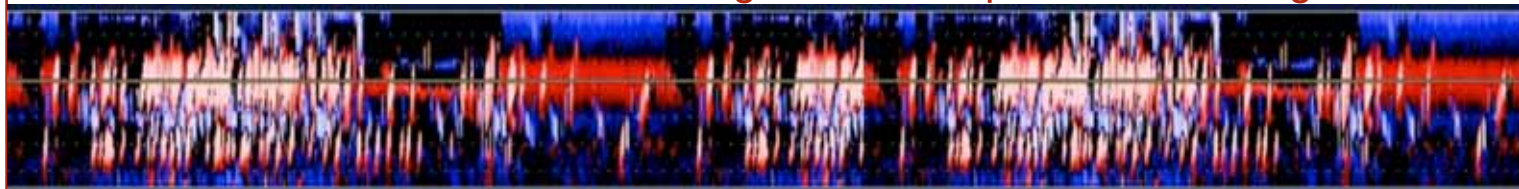


University of Utah Pediatric Cardiology faculty Drs. Rachel McCandless and Nelangi Pinto enjoying themselves at the faculty dinner.



Dr. John Triedman celebrates his winning form after demonstrating his snowboard prowess.

For information on PFO detection go to: www.spencertechnologies.com





Dr. Geoffrey Lane enjoys a cold one at the banquet while listening to some excellent jazz music.



Rick Ohye enjoys a moment with his very fast daughters, Maddie and Lily.

This year's meeting again included a variety of social events with great food and live music and the entertainment of the ski race that has increasingly become the forum for resolution of debates from earlier in the meeting.

The 19th Utah Conference on Congenital Cardiovascular Disease will be held in February 2012 with plans to feature international experts in the field.

The conference was presented by the Department of Pediatrics, University of Utah School of Medicine and primary Children's Pediatric Education Services.

Visit the website later in the year for further information: <http://intermountainhealthcare.org/hospitals/primarychildrens/classes/classesformedical/conferences/Pages/home.aspx>

CCT

Collin G. Cowley, MD
Associate Director, Pediatric Cardiology
University of Utah
100 N. Mario Capecchi Dr., Ste. 1500
Salt Lake City, Utah 84113 USA
Phone: 801.662.5440
collin.cowley@imail.org

JULY 2010 MEDICAL MEETING FOCUS

PEDIATRIC & ADULT INTERVENTIONAL CARDIAC SYMPOSIUM (PICS & AICS 2010)

With Live Case Demonstrations

July 18-21, 2010

Chicago, IL USA

www.picsymposium.com

Program Directors: Ziyad M. Hijazi, MD, MPH; William E. Hellenbrand, MD; Carlos Pedra, MD; John P. Cheatham, MD

Co-Directors: Zahid Amin, MD; Ted Feldman, MD

Guest Faculty: Teiji Akagi, MD; BG Alekian, MD; Wail Alkaskhari, MD; Mazeni Alwi, MD; Emile Bacha, MD; David Balzer, MD; John Bass, MD; Lee Benson, MD; Farhouch Berdjis, MD; Felix Berger, MD; Jacek Bialkowski, MD; Philipp Bonhoeffer, MD; Robert Bonow, MD; Elchanan Bruckheimer, MD; Qi-Ling Cao, MD; Mario Carminati, MD; Alpay Celiker, MD; Jae Young Choi, MD; Roberto Cubeddu, MD; Bharat Dalvi, MD; Pedro Del Nido, MD; Carol Devellian, BS; Makram Ebeid, MD; Peter Ewert, MD; Horacio Faella, MD; Craig Fleishman, MD; Simone Fontes-Pedra, MD; Thomas Forbes, MD; Olaf Franzen, MD; Yun Ching Fu, MD; M. Omar Galal, MD; Mark Galantowicz, MD; Ricardo Gamboa, MD; Wei Gao, MD; J V De Giovanni, MD; Miguel Granja, MD; Donald Hagler, MD; Ali Halabi, MD; Sharon Hill, ACNP; Ralf Holzer, MD; Eric Horlick, MD; Reda Ibrahim, MD; Michel Ilbawi, MD; Frank Ing, MD; Ignacio Ingeles, MD; Mansour Al Joufan, MD; Thomas Jones, MD; Saibal Kar, MD; Cliff Kavinsky, MD; Jan Kovac, MD; Seong-Ho Kim, MD, PhD; Terry D. King, MD; Charles S. Kleinman, MD; Krishna Kumar, MD; Geoffrey Lane, MD; Larry Latson, MD; Trong-Phi Le, MD; Daniel Levi, MD; Achiau Ludomirsky, MD; Raj Makkar, MD; Gerard Martin, MD; Jozef Masura, MD; Tarek Momenah, MD; John W. Moore, MD; Phillip Moore, MD; Michael Mullen, MD; Charles E. Mullins, MD; Toshio Nakanishi, MD; Kathleen Nolan, (RT) (R), (CV); David Nykanen, MD; Eustaquio Onorato, MD; Shakeel A. Qureshi, MD; David Reuter, MD; John Rhodes, MD; Richard Ringel, MD; Jonathan Rome, MD; Russell D'Sa, CVT; Masood Sadiq, MD; Girish Shirali, MD; Terry Sideris, MD; Horst Sievert, MD; Dietmar Schranz, MD; Frank Silvestry, MD; Sherm Sorensen, MD; Jonathan Tobis, MD; Zoltan Turi, MD; Mike Tynan, MD; Julie Vincent, MD; Robert Vincent, MD; Kevin Walsh, MD; Jou-Kou Wang, MD; John Webb, MD; Howard Weber, MD; Paul Weinberg, MD; Gil Wernovsky, MD; Robert White, Jr, MD; James L. Wilkinson, MBBS; Neil Wilson, MD; Carlos Zabal, MD; and Evan Zahn, MD

Meeting Overview:

The meeting will feature live case demonstrations from multiple international centers demonstrating the latest in medical device technology using approved and investigational devices/valves/stents etc. This symposium will give the attendees an opportunity to interact with the faculty during lectures, interactive discussions, workshops, live case demonstrations and daily breakout sessions.

Special sessions will provide an in-depth focus on septal defect closure (PFO, ASD, VSD and PDA) using all available devices (approved and investigational), embolization therapies, coarctation stenting, aortic and mitral valve disease and their management in both children and adults, RVOT and pulmonic valve disease (featuring the new percutaneous valve implants with live cases of both the Melody and Edwards valves), hybrid intervention for Hypoplastic Left Heart Syndrome and muscular VSDs, stent/balloon angioplasty of branch pulmonary arteries, and "how to session," etc. There will be a special session on left atrial appendage, percutaneous aortic and mitral valve therapies presented by the experts in these fields.

There will be "Hot Debates" featuring a cardiologist and a cardiac surgeon debating forms of management and outcome, and the ever-popular session "My Nightmare Case in the Cath Lab."

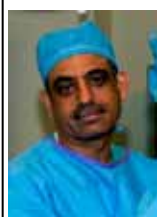This year there will be a special one-day seminar entitled, "Imaging in Congenital & Structural Cardiovascular Interventional Therapies," immediately preceding PICS ~ AICS. For information and program details visit the website.

Abstracts from “Evolving Concepts in the Management of Complex Congenital Heart Disease II” - Part 1

“Abstracts from ‘Evolving Concepts in the Management of Complex Congenital Heart Disease II’ - Part I” includes the following topics and presenters:

- How Far Can We Go With VSD Closure? by *Zahid Amin, MD*
- Evolving Concepts in the Management of Arrhythmias in Adults with Congenital Heart Disease by *Anjan S Batra, MD*
- Pediatric Cardiac Transplantation: The Next 25 Years by *Daniel Bernstein, MD*
- Kawasaki Disease Update by *Jane C. Burns MD*
- Assessment of the Hybrid Approach to the Management of HLHS by *John P. Cheatham, MD*

See Part II in the May issue of Congenital Cardiology Today



Abstract Title: How Far Can We Go With VSD Closure?
Presenter: Zahid Amin, MD; Professor of Pediatrics; Director, Cardiac Catheterization and Hybrid Suites, RUCH Center for Congenital and Structural Heart Disease; RUSH Medical Center, Chicago, IL US

Objective

The objectives of this presentation are to provide a brief history of VSD closure, followed by innovations in minimally invasive VSD closure from trans-catheter, robotic to perventricular procedures. The different types of device and delivery sheaths available and those that may become available will also be discussed.

Abstract

Ventricular septal defects (VSD) are the most common congenital cardiac lesions. VSD was the first defect that underwent closure with open heart surgery by Dr. Lillehei. From surgical perspective, it has become a relatively straightforward procedure. The most common type of VSD is perimembranous (or cono-ventricular) VSD and comprise nearly 90 % of all VSD. A small proportion of the patients have muscular VSD. Over the last several years, the interventional cardiologists have had the opportunity to close perimembranous and muscular VSD with the help of devices. Currently there are two devices approved for muscular VSD closure-CardioSEAL and Amplatzer MVSD device. There is no device approved for perimembranous VSD closure.

From a surgical standpoint, muscular VSD are difficult to close in the operating room as they may be embedded in the trabecular ventricular septum and the rims are not seen clearly. Patch closure, although successful, may not completely close the defect, may increase the cardiopulmonary bypass time and its associated

morbidity and, increase chances of re-operation in cases of significant residual shunt.

Device closure of these defects has gained popularity as the procedure can be performed without cardiopulmonary bypass with decrease post-procedure morbidity.

At the current time, there are two options available to the interventionalist for VSD closure; transcatheter or perventricular closure. Both of these techniques are used on a routine basis and have advantages over the surgical procedure-mainly no cardiopulmonary bypass (CPB).

In the data submitted to the FDA for muscular VSD device approval by AGA Medical Corporation, the risk of complications of transcatheter procedure increased significantly when the patient's weight dropped below 5.2 kg. Hence patients who are less than 5 kg are best-served by perventricular approach. This is a Hybrid approach in which the surgeon and the interventionalist are equally involved. The defect is closed in the operating room, catheterization laboratory or hybrid suite. The closure is directly through the right ventricle (RV) free wall, under echocardiographic guidance while the heart is beating. The visualization of the defect by echocardiography is better than direct visualization when the patient is on CPB.

The procedure requires mini-sternotomy, opening of the pericardial sac and a purse string over the RV free wall. Under TEE guidance, an angio-catheter is inserted into the RV; a wire is advanced through the catheter and maneuvered through the VSD into the left ventricle. An appropriate-sized deliver sheath is introduced over the wire through the RV free wall and the VSD into the left ventricle. The device is then placed in a fashion similar to the catheterization procedure.

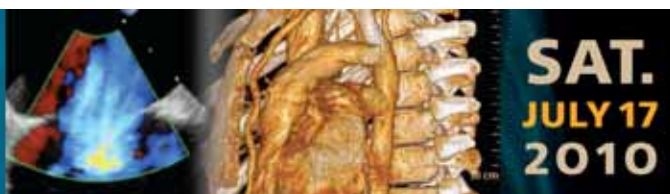The next frontier in tackling the VSD will be to do the procedure without sternotomy under robotic guidance. In addition, advances in development of delivery sheaths that can be maneuvered easily through the VSD during perventricular closure, improvement in device designs that may prevent rhythm issues and impingement of the cardiac valves will add significantly to optimal outcomes for the patient.

Although we have been able to close perimembranous VSD with perventricular technique in the past, we have stopped using devices in the perimembranous position because of high risk complete heart block. Once devices that will obviate this issue are available, perventricular approach will become an attractive option for perimembranous VSD as well.

In summary, device closure of VSD has come a long way with different options available as to the delivery of devices. We, however, can and will go further in improving the minimally invasive



IMAGING IN CONGENITAL AND STRUCTURAL
CARDIOVASCULAR INTERVENTIONAL THERAPIES
ONE DAY SYMPOSIUM
IMMEDIATELY PRECEEDING PICS-AICS



ways of device delivery, improving in design of devices, developing better delivery catheters and researching on robotic procedures.

References

1. Amin, Z, Cao Q, Hijazi Z M. Closure of muscular ventricular septal defects: transcatheter and hybrid techniques. Cathet Cardiovasc Int 2008;72:102-111.
2. Amin Z, Woo R, Danford DA, Reddy VM, Lof J, Overman D. Robotically assisted perventricular closure of perimembranous ventricular septal defects: preliminary results in yucatan pigs. J Thorac Cardiovasc Surg 2006;131:427-432.
3. Bacha E, Cao Q, Starr JP, Waight D, Ebeid MR, Hijazi Z M. Perventricular device closure of muscular VSD on the beating heart: technique and results. J Thorac Cardiovasc Surg 2003;126:1718-1723.
4. Amin Z, Gu X, Berry JM, Bass JL, Titus JL, et al. New device for closure of muscular ventricular septal defects in a canine model. Circulation 1999;100:320-328.
5. Amin Z, Bery JM, Foker JE, Rocchini AP, Bass JL. Intraoperative device closure of muscular ventricular septal defect in a canine model and application of the technique in a baby. J Thorac Cardiovasc Surg 1998;115:1374-76.

CCT



Abstract Title: Evolving Concepts in the Management of Arrhythmias in Adults with Congenital Heart Disease
Presenter: Anjan S Batra, MD; Director of Electrophysiology; Children's Hospital of Orange County; Associate Professor of Clinical Pediatrics; University of California, Irvine; Irvine, CA USA

Objective

- Understand the scope of the problem of arrhythmias in adults with congenital heart disease (CHD).
- Have an understanding of the arrhythmias encountered in common forms of CHD.
- Risk stratify these patients for sudden death, ICDs, catheter ablation and surgical therapy.
- Understand the unique approaches of treating arrhythmias in adults with CHD.

Abstract

Adults with congenital heart disease are a rapidly growing segment of the population. There are more adults than children living with CHD.¹ The incidence of arrhythmias increases with age and, by adulthood, arrhythmias are the leading cause of hospital admissions. Sudden death of presumed arrhythmic etiology is the most common cause of mortality. Criteria for risk stratification for primary and secondary prevention of arrhythmias and sudden death continue to evolve.² Other evolving concepts in the management of

arrhythmias in adults with congenital heart disease include newer medications (Ibutilide, Dofetilide),³ advances in 3D Electro-anatomical mapping,⁴ and newer catheter technology (cooled tip catheter). Advances in pacing include newer devices capable of antitachycardia pacing,⁵ resynchronization,⁶ and defibrillation. Ablation of arrhythmia substrates can be done in the catheterization laboratory and surgically in the operating room.⁷ Other hybrid approaches are also being developed to address these complex arrhythmias.⁸ Despite huge improvements in the recent past, available therapies for treatment of arrhythmias in adults with congenital heart disease remain inadequate.

References

1. Mark Gatzoulis MA, Hechter S, Siu SC, Webb GD. Outpatient clinics for adults with congenital heart disease: increasing workload and evolving patterns of referral. Heart. 1999;81:57-61.
2. Mark Khairy P, Harris L, Landzberg MJ, et al. Implantable cardioverter-defibrillators in tetralogy of Fallot. Circulation 2008;117:363-370.
3. Mark Hoyer AW, Balaji S. The safety and efficacy of ibutilide in children and in patients with congenital heart disease. Pacing Clin Electrophysiol. 2007;30:1003-8.
4. Mark Khairy P. EP challenges in adult congenital heart disease Heart Rhythm 2008;5:1464-72.
5. Mark Batra AS. Pediatr Cardiol. 2008;29:851-4.
6. Mark Dubin AM, Janousek J, Rhee E, et al. J Am Coll Cardiol. 2005; 46:2277-83.
7. Mark Khairy P, Stevenson WG. Catheter ablation in tetralogy of Fallot. Heart Rhythm 2009;6:1069-74.
8. Mark Khairy P, Fournier A, Ruest P, Vobecky SJ. Transcatheter ablation via a sternotomy approach as a hybrid procedure in a univentricular heart. Pacing Clin Electrophysiol. 2008;31:639-40.

CCT



Abstract Title: Pediatric Cardiac Transplantation: The Next 25 Years
Presenter: Daniel Bernstein, MD; Chief, Division of Pediatric Cardiology; Lucille Packard Children's Hospital; Co-Director, Children's Heart Center; Alfred Woodley Salter and Mabel G. Salter Endowment; Professor of Pediatrics; Stanford University Medical Center; Palo Alto, CA USA

Objective

1. Improve competence in managing difficult heart transplant issues leading to improved survival and reduced morbidity.
2. Increase understanding of new mechanisms for managing high risk patients with heart failure to improve pre and post transplant outcomes.

B | BRAUN

For information, please call 1-800-BRAUN2 (227-2862)

www.bbraunusa.com



Working Together to Develop a Better Tomorrow

**JULY 2010
MEDICAL MEETING FOCUS**

CSI 2010 - Congenital and Structural Interventions 2010

July 8-10, 2010; Congress Center, Frankfurt, Germany

www.csi-congress.org

With live cases

Course Directors: Horst Sievert, MD; Nina Wunderlich, MD; Neil Wilson, MD; Shakeel A. Qureshi, MD; and Mario Carminati, MD

Topics include:

Congenital Heart Interventions

- How to Close Atrial and Ventricular Septal Defects
- How to use Balloons and Stents in Coarctation and Pulmonary Artery Stenoses
- How to Close Large Patent Ductus and Pulmonary AV Fistulae

Structural Heart Interventions

- How and When to Close Patent Foramen Ovale to Prevent Paradoxical Embolism
- How to Close Post Myocardial Infarction Ventricular Septal Defects
- How to Close the Left Atrial Appendage to Prevent Embolic Stroke in Atrial Fibrillation
- How to Treat Heart Failure by Catheter Techniques

Valvular Heart Interventions

- How to Close Paravalvular Leaks
- How to Repair Heart Valves by Catheter Techniques
- How to Implant Heart Valves Percutaneously
- How to Perform a Valvuloplasty

Selected List of Faculty: Zahid Amin, MD; Uros U. Babic, MD; Franziska Baumgarten; Lee Benson, MD; Felix Berger, MD; Elchanan Bruckheimer, MD; Grazyna Brzezinska-Rajszy, MD; Gianfranco Butera, MD; Allison Cabalka, MD; John P. Cheatham, MD; Massimo Chessa, MD; Andrew Cook, MD; Ingo Daehnert, MD; Nicholas Dann; Joseph DeGiovanni, MD; Mirko Doss, MD; Caras Esteves, MD; Peter Ewert, MD; Olaf W. Franzen, MD; Franz Freudenthal, MD; Marc Gewillig, MD; Miguel Granja; Frank Groenewegen; Ziyad Hijazi, MD; David Hildick-Smith, MD; Rafael Hirsch, MD; Yen S. Ho, MD; Reda Ibrahim; Huseyin Ince, MD; Bernard lung, MD; Alexander Javois; Saibal Kar, MD; Alexander Khairkhan; Xiang Qing Kong, MD; Rainer Kozlik-Feldmann, MD; Oliver Kretschmar, MD; Jean-Claude Laborde, MD; Alexander Lauten, MD; Trong-Phi Lê, MD; James E. Lock, MD; Francesco Maisano, MD; Jozef Masura, MD; Ralf Müller, MD; David Messika-Zeitoun, MD; Michael Mullen, MD; Jim Newton, MD; Anthony Nobles; Marco Noc, MD; Eustaquio Onorato, MD; Oliver Ormerod, MD; Jai-Wun Park, MD; Jaishankar Raman, MD; Mark Reisman, MD; Kristina Renkhoff; Carlos Ruiz, MD; Martin Schneider, MD; Dietmar Schranz, MD; Gurleen Sharland; Peter Sick, MD; E.B. Sideris, MD; John Simpson, MD; Gaetano Thiene, MD; John Thomson, MD; Gerald Tulzer, MD; Zoltan Turi, MD; Mark Turner, MD; Michael J. Tynan, MD; Frank Uhlemann; Mariano Valdes-Chávari, MD; Kevin P. Walsh, MD; Jochen Wöhrle, MD; Stephen Westaby, MD; Brian Whisenant, MD; Robert F. Wilson; Maarten Witsenburg, MD; Peter Zartner, MD; and Andreas Zeiher, MD

Also see: **iCi - 2010 Imaging in Cardiovascular Interventions** which takes place July 8, one day before **CSI** at the same location, Congress Center, Frankfurt, Germany. See www.ici-congress.org for more information.

Abstract

Cardiac transplantation has evolved significantly over the past quarter century, moving from a highly experimental procedure to one that has become routine, complete with standardized protocols and a successful multi-center registry. Over that time frame, one-year survival has increased from 75% to over 90% and there are an increasing number of true long-term survivors. The next era of transplant medicine will be one of increasing innovation, with the development of new technologies, translation of molecular discoveries to the bedside, and the application of the power of personalized medicine through discoveries in genomics and pharmacogenomics. We will review several challenges for the future:

- pediatric mechanical circulatory support including the development of smaller and less traumatic and risky pediatric support systems;
- the non-invasive diagnosis of rejection using molecular tools for analyzing genome-wide immune pathway activation,
- transplantation of the highly sensitized patient, representing an increasing population of pediatric heart transplant candidates, and
- pharmacogenomics applied to pediatric heart transplantation, allowing clinicians to individualize immunosuppressive regimens.

Through these innovations, the next era of pediatric heart transplantation will be marked by a further reduction in mortality and morbidity and an extension of the benefits of transplantation to patients who would have previously been ineligible.

References

1. Bernstein D, Williams GE, Eisen H, Mital S, Wohlgemuth JG, Klingler TM, Fang KC, Deng MC, Kobashigawa J. Gene expression profiling distinguishes a molecular signature for grade 1B mild acute cellular rejection in cardiac allograft recipients. *J Heart Lung Transplant*. 2007 Dec;26(12):1270-80.
2. Blume ED, Naftel DC, Bastardi HJ, Duncan BW, Kirklin JK, Webber SA; Pediatric Heart Transplant Study Investigators. Outcomes of children bridged to heart transplantation with ventricular assist devices: a multi-institutional study. *Circulation*. 2006 May 16;113(19):2313-9.
3. Deng MC, Eisen HJ, Mehra MR, Billingham M, Marboe CC, Berry G, Kobashigawa J, Johnson FL, Starling RC, Murali S, Pauly DF, Baron H, Wohlgemuth JG, Woodward RN, Klingler TM, Walther D, Lal PG, Rosenberg S, Hunt S; CARGO Investigators. Noninvasive discrimination of rejection in cardiac allograft recipients using gene expression profiling. *Am J Transplant*. 2006 Jan;6(1):150-60.
4. Givita DM, Brooks MM, Webber SA, Burckart GJ, Ferrell R, Zdanowicz G, DeCruo S, Smith L, Chinnock R, Canter C, Addonizio L, Bernstein D, Kirklin JK, Ranganathan S, Naftel D, Givita AL, Zeevi A. Genetic polymorphisms impact the risk of acute rejection in pediatric heart transplantation: a multi-institutional study. *Transplantation*. 2008 Jun 15;85(11):1632-9.
5. Kobashigawa J, Mehra M, West L, Kerman R, George J, Rose M, Zeevi A, Reinsmoen N, Patel J, Reed EF; Consensus Conference Participants. Report from a consensus conference on the sensitized patient awaiting heart transplantation. *J Heart Lung Transplant*. 2009 Mar;28(3):213-25.

CCT



PICS-AICS
Pediatric and Adult Interventional Cardiac Symposium



**JULY
18-21
2010**



Abstract Title: Kawasaki Disease Update
Presenter: Jane C. Burns MD; Professor and Chief, Division of Allergy, Immunology and Rheumatology; Director, Kawasaki Disease Research Center; Rady Children's Hospital - San Diego; Department of Pediatrics; University of California, San Diego, School of Medicine; San Diego, CA USA

Objective

1. To update current knowledge of epidemiology and treatment of Kawasaki disease (KD)
2. To review cardiac outcomes and controversy on appropriate follow-up of KD patients
3. To introduce AHA risk stratification scheme
4. To describe range of potential cardiovascular sequelae in adulthood

Abstract

Kawasaki Disease (KD) is the leading cause of acquired heart disease in children in the developed world.¹ Typically, KD presents in children under the age of five years as a febrile illness with mucocutaneous changes. A subset of patients will develop permanent damage to the arterial wall, valve leaflets, and myocardium. The acute phase of the illness is self-limited and the diagnosis may be missed. If untreated, KD can result in coronary aneurysms in 25% of patients.² Patients who suffer coronary artery damage may develop thrombosis or stenotic lesions associated with the aneurysms and are at risk of myocardial infarction, sudden death, and congestive heart failure.^{3,4} The prognosis for adults who recovered from KD without coronary aneurysms is postulated to be good, but longitudinal studies have not been performed to test this hypothesis.

In 2004, the American Heart Association issued updated guidelines for the care and management of children with KD.⁵ However, studies of the optimal therapy and management of the sequelae of KD in children and adults have not been performed. It is estimated that over 4,000 new cases of KD are diagnosed in the U.S. each year. In Japan, where the incidence is approximately 10-fold higher as compared to the U.S., more than 12,000 new cases are diagnosed each year. Seasonality of cases, nationwide epidemics, and the self-limited nature of the acute illness suggest an infectious trigger but no causative agent has been identified. Genetic influences on disease susceptibility and outcome have been identified and the current paradigm proposes that KD results from exposure to a common agent that triggers the syndrome only in genetically susceptible hosts.

The self-limited clinical syndrome is recognized through a constellation of clinical signs that include: fever for at least 4 days associated with rash, conjunctival injection, erythema of the lips and oropharynx, edema of the hands and feet, erythema of the palms and soles, and, in the convalescent phase, periungual

desquamation. Up to 25% of untreated children will develop permanent damage to the coronary arteries with inflammatory cell infiltration of the arterial wall, destruction of the internal elastic lamina, necrosis of smooth muscle cells, myointimal proliferation, and subsequent aneurysm formation. Aneurysms of systemic, extra-parenchymal muscular arteries also occur in a subset of patients with coronary aneurysms. The proximal coronary arteries can be readily imaged in infants and children using transthoracic echocardiography that permits reliable and reproducible measurement of the internal diameter of the proximal right and left anterior descending coronary arteries (RCA and LAD) and the expression of these measurements as standard deviation units (Z score) normalized for body surface area (BSA).

Administration of a single dose of intravenous immunoglobulin (IVIG) in conjunction with aspirin within the first ten days after fever onset reduces the incidence of aneurysms from 25% to 3-5%. The AHA guidelines have divided these patients into five groups based on coronary artery Z scores and morphology of the coronary artery lesions. Approximately 30% of IVIG-treated children with KD will develop transient dilatation of the coronary arteries (Z score ≥ 2.5 for the RCA or LAD, AHA Risk level II). Another 5-10% will develop coronary artery aneurysms, which in some cases can be attributed to delayed diagnosis and treatment.

Management of the KD patient with evolving aneurysms should focus on halting the inflammatory process, decreasing myocardial oxygen demand, and preventing thrombosis. Use of anti-inflammatory agents to block TNF alpha (infliximab) and to downregulate T-cell activation (cyclosporine, tacrolimus) are currently being studied to decrease inflammation. Beta-blockade and transfusion may have a cardioprotectant role. Anti-platelet therapy and systemic anti-coagulation have roles in prevention of thrombosis.

References

1. Kawasaki T, Kosaki F, Okawa S, Shigematsu I, Yanagawa H. A new infantile acute febrile mucocutaneous lymph node syndrome (MLNS) prevailing in Japan. *Pediatrics* 1974;54:271-6.
2. Kato H, Sugimura T, Akagi T, et al. Long-term consequences of Kawasaki disease. A 10- to 21-year follow-up study of 594 patients. *Circulation* 1996;94:1379-85.
3. Burns JC, Glode MP. Kawasaki syndrome. *Lancet* 2004;364:533-44.
4. Newburger JW, Takahashi M, Gerber MA, et al. Diagnosis, treatment, and long-term management of Kawasaki disease: a statement for health professionals from the Committee on Rheumatic Fever, Endocarditis and Kawasaki Disease, Council on Cardiovascular Disease in the Young, American Heart Association. *Circulation* 2004;110:2747-71.
5. Gordon JB, Kahn A, Burns JC. When children with Kawasaki disease grow up: Myocardial and vascular complications in adulthood. *JACC* 2009;54:1911-1920.

CCT

International Symposium on the Hybrid Approach to Congenital Heart Disease

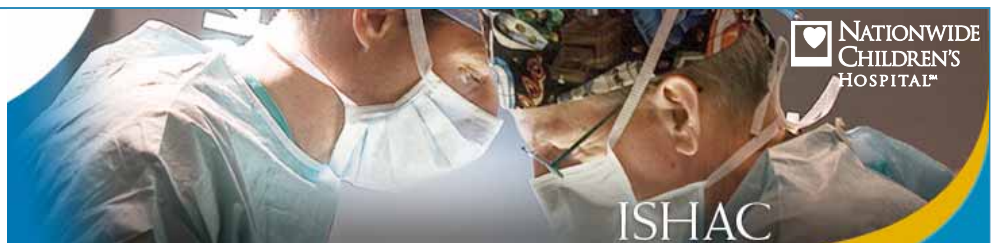with live presentations

August 31-September 2, 2010

Columbus, OH USA

For details and to register go to:

hybridsymposium.com



**JULY 2010
MEDICAL MEETING FOCUS**

**APPCS 2010 (The 3rd Annual Congress
of Asia-Pacific Pediatric Cardiac Society)**

June 6-8, 2010; Urayasu, Chiba, Japan

www.appcs.org/2010

Language: English

Co-Chair Persons: Makoto Nakazawa, MD; Toshikatsu Yagihara, MD

Co-Vice Persons: Tsutomu Saji, MD; Shunji Sano, MD

Honorary Chair Persons: Last Kensuke Harada; Hikaru Matuda, MD

Theme: "New horizon in Pediatric Cardiology from Asian Pacific to the World"

This year's congress will be held in Disney Resort, Chiba, Japan along with the **2nd Congress of Asia-Pacific Society for Adult Congenital Heart Disease** (www.appcs.org/2010/apsachd.htm) and the **46th Annual Meeting of Japanese Society of Pediatric Cardiology and Cardiac Surgery** (<http://square.umin.ac.jp/scpi/index.html>).

Topics Include:

- Acquired Heart Disease
 - Adult Congenital Heart Disease
 - Arrhythmias (Basic and clinical; EPS, RF Ablation, CRT, ICD)
 - Autonomic Nervous Function
 - Basic and/or Molecular Science
 - Cardiac Function
 - Cardiopulmonary Bypass
 - Cardiovascular Risks (Metabolic Syndrome)
 - Catheter Intervention
 - Collaborative Studies Session
 - Congenital Cardiovascular Surgery (Neonatal, Complex)
 - Cyanotic Disorder
 - Education; Epidemiology
 - Fetal Cardiology
 - General Cardiology (IE, RS Virus Infection, Rheumatic Heart Disease)
 - Genetics; Heart Failure; Imaging (Echo, CT, MRI, RI)
 - Intensive Care
 - Kawasaki Disease
 - Mechanical Circulatory Support
 - Mechanical Heart;
 - Pediatric Cardiac Anesthesiology
 - Pediatric Valve Diseases
 - Psychosocial Problems Development
 - Tissue Engineering
 - Transplantation
- And more...

Selected List of Faculty: Carl Backer, MD; Jane C. Burns, MD; Michael A Gatzoulis, MD; Ziyad M. Hijazi, MD; Pamela D. Miner, MD; Shakeel A Qureshi, MD; Alain Serraf, MD; and Edward P. Walsh, MD



Abstract Title: Assessment of the Hybrid Approach to the Management of HLHS
Presenter: John P. Cheatham, MD, FAAP, FACC; FSCAI; George H. Dunlap Endowment Chair in Interventional Cardiology; Director, Cardiac Catheterization and Interventional Therapy; Co-Director, The Heart Center, Nationwide Children's Hospital; Professor, Pediatrics and Internal Medicine, Cardiology Division; The Ohio State University College of Medicine; Columbus, OH USA

Objectives

- Understand the techniques for performing Hybrid Stage I Palliation
- Describe the indications & contraindications of the Hybrid procedure
- List the potential advantages & disadvantages of the Hybrid approach.

Abstract

Hypoplastic Left Heart Syndrome (HLHS) is uniformly fatal with approximately 90% of patients dying within the first month of life without some sort of intervention. The objective of Stage I palliation for single ventricle physiology is to provide an unobstructed systemic outflow tract, unrestrictive interatrial communication, a controlled source of pulmonary blood flow, and a reliable source of coronary blood flow. The Norwood procedure described in 1981, cardiac transplantation described in 1986, and the Sano modification of the Norwood procedure in 2001, all met the above objectives. However, while individual centers worldwide have had success with one or more of the surgical strategies, the learning curve has been steep and neurodevelopmental outcomes questionable.

In 1999 while at Nemours Cardiac Center in Orlando, a "comprehensive" Hybrid approach was initiated, where surgical and transcatheter therapies were merged in order to flank one comprehensive open heart surgical procedure with two off CPB procedures: initially Hybrid Stage I palliation and a final transcatheter Fontan completion. From 2002 to present, members of The Heart Center at Nationwide Children's Hospital have promoted this approach as not only an acceptable alternative to "high risk patients", but also to all patients with HLHS, complex single and two-ventricle anatomy, who are being considered for conventional surgical procedures or cardiac transplantation.

Hybrid Stage I Palliation evolved into placing surgical RPA and LPA bands using Gore-Tex strips through a small median sternotomy off CPB, followed by a PDA stent delivered through a sheath placed in the MPA through a small purse-string suture using fluoroscopic guidance. Finally, creation of an adequate ASD is performed electively prior to discharge using a BAS catheter. In the case of severely restrictive ASD or intact atrial



International Children's Heart Foundation

VOLUNTEER YOUR TIME!

We bring the skills, technology and knowledge to build sustainable cardiac programmes in developing countries, serving children regardless of country of origin, race, religion or gender.

www.babyheart.org

septum, the communication is created first by several different techniques, including: RF perforation, stent implant, or static balloon septoplasty. This palliation meets the criteria of 1) control & protects PBF, 2) provide reliable systemic cardiac output, and 3) create unobstructed flow from the LA.

Both Giessen University in Germany and NCH in Columbus championed this approach and published extensively so others could follow...from the initial techniques, to lessons learned, to intermediate results and follow-up. Using this Hybrid approach, contraindications to therapy in these sick neonates virtually disappeared. Size of patient, size of ascending aorta, poor RV function with significant TR, and avoidance of blood products were no longer a contraindication for palliation...unlike for the Norwood or Sano surgical procedures. Eventual biventricular repair or later cardiac transplant strategies could also benefit from Hybrid Stage I palliation. Only retrograde aortic arch flow obstruction seemed to be a contraindication to this novel approach.

In 2008, Galantowicz, et al published NHC's intermediate results in The Annals of Thoracic Surgery. From July 2002 – June 2008, 80 neonates underwent PA bands and PDA stent weighing 1.1 – 4.0 Kg, average age of 5 days, with 65 HLHS, 13 complex SV, and 2 complex 2V. There were 55 patients with typical HLHS and uniform risks who were analyzed. Procedural mortality was 2%, interstage mortality 6%, interstage reinterventions 26%, Comprehensive Stage II repair mortality 6% with no open sternum or ECMO support needed. The overall cumulative survival was 87% (92% for "usual risks"), which was virtually identical to that reported by Giessen as well as quite favorable to the contemporary reports from Boston and Philadelphia.

A concern with the Hybrid approach is the persistence of requiring retrograde aortic arch flow for the additional 4-6 months until Comprehensive Stage II is performed, as well as the challenges of PDA stent and PA band surgical removal. Thus far, interstage retrograde aortic flow obstruction occurs in ~ 20% of patients and can be successfully treated with percutaneous stent therapy. All PDA stents have been able to be removed surgically. However, further studies are underway to assess the neurodevelopmental outcomes of these patients, with correlation with transcranial Doppler and MR imaging... both through an NIH grant and a multi-institutional study.

While some centers have only offered the Hybrid approach to those high risk neonates who are not suitable candidates for the Norwood or Sano repairs, the results thus far

suggest that the Hybrid approach should be an evenly discussed option with all patients, regardless of their risk scale. Improvement in both mortality and neurodevelopmental outcomes must override conventional strategies and thinking.

References

1. Ashburn DA, McCrindle BW, Tchervenkov CI, et al. Outcomes after the Norwood Operation in Neonates with Critical Aortic Stenosis or Aortic Valve Atresia. J Thorac Cardiovasc Surg. 2003;125:1070-82.
2. Ohye RG, Gaynor JW, Ghanayem NS, Goldberg CS, Laussen PC, Frommelt PC, Newburger JW, Pearson GD, Tabbutt S, Wernovsky G, Wruck LM, Atz AM, Colan SD, Jaggers J, McCrindle BW, Prakash A, Puchalski MD, Sleeper LA, Stylianou MP, Mahony L; Pediatric Heart Network Investigators. Design and Rationale of a Randomized Trial Comparing the Blalock-Taussig and Right Ventricle-Pulmonary Artery Shunts in the Norwood Procedure. J Thorac Cardiovasc Surg. 2008 Oct;136(4):968-75. Epub 2008 May 19.
3. Hill SL, Galantowicz M, Cheatham JP. Hybrid Stage I Palliation. Pediatr Cardiol Today, 2003;1:1-4.
4. Akintürk H, Michel-Behnke I, Valeske K, Mueller M, Thul J, Bauer J, Hagel KJ, Schranz D. Hybrid Transcatheter-Surgical Palliation, Basis for Univentricular or Biventricular Repair: The Giessen Experience. Pediatr Cardiol. 2007 Mar-Apr;28(2):79-87. Epub 2007 Feb 15.
5. Galantowicz M, Cheatham JP, Phillips A, Cua CL, Hoffman TM, Hill SL, Rodeman R. Hybrid Approach for Hypoplastic Left Heart Syndrome: Intermediate Results After the Learning Curve. Ann Thorac Surg. 2008 Jun;85(6):2063-70; discussion 2070-1.
6. Wernovsky G, Shillingford AJ, Gaynor JW. Central Nervous System Outcomes in Children with Complex Congenital Heart Disease. Curr Opin Cardiol. 2005;20:94-9.
7. Chen Q, Parry AJ. The Current Role of Hybrid Procedures in the Stage I Palliation of Patients with Hypoplastic left Heart Syndrome. Eur J Cardiothorac Surg. 2009 Jul;36(1):77-83. Epub 2009 Mar 10.

CCT

Read Part II: "Abstracts from 'Evolving Concepts in the Management of Complex Congenital Heart Disease II' - in the May issue

CONGENITAL CARDIOLOGY TODAY

© 2010 by Congenital Cardiology Today (ISSN 1554-7787-print; ISSN 1554-0499-online). Published monthly. All rights reserved.

Headquarters

9008 Copenhaver Dr. Ste. M
Potomac, MD 20854 USA

Publishing Management

Tony Carlson, Founder & Senior Editor

TCarlsonmd@gmail.com

Richard Koulbanis, Publisher & Editor-in-Chief

RichardK@CCT.bz

John W. Moore, MD, MPH, Medical Editor/

Editorial Board

JMoore@RCHSD.org

Editorial Board

Teiji Akagi, MD

Zohair Al Halees, MD

Mazeni Alwi, MD

Felix Berger, MD

Fadi Bitar, MD

Jacek Bialkowski, MD

Philipp Bonhoeffer, MD

Mario Carminati, MD

Anthony C. Chang, MD, MBA

John P. Cheatham, MD

Bharat Dalvi, MD, MBBS, DM

Horacio Faella, MD

Yun-Ching Fu, MD

Felipe Heusser, MD

Ziyad M. Hijazi, MD, MPH

Ralf Holzer, MD

Marshall Jacobs, MD

R. Krishna Kumar, MD, DM, MBBS

Gerald Ross Marx, MD

Tarek S. Momenah, MBBS, DCH

Toshio Nakanishi, MD, PhD

Carlos A. C. Pedra, MD

Daniel Penny, MD

James C. Perry, MD

P. Syamasundar Rao, MD

Shakeel A. Qureshi, MD

Andrew Redington, MD

Carlos E. Ruiz, MD, PhD

Girish S. Shirali, MD

Horst Sievert, MD

Hideshi Tomita, MD

Gil Wernovsky, MD

Zhuoming Xu, MD, PhD

William C. L. Yip, MD

Carlos Zabal, MD

FREE Subscription

Congenital Cardiology Today is available free to qualified professionals worldwide in pediatric and congenital cardiology. International editions available in electronic PDF file only; North American edition available in print. Send an email to Subs@CCT.bz. Include your name, title, organization, address, phone and email.

Contacts and Other Information

For detailed information on author submission, sponsorships, editorial, production and sales contact, current and back issues, see website or send an email to: INFO@CCT.bz.



Medtronic



Hope,
Restored.

Melody® TPV Receives FDA HDE Approval

Melody® Transcatheter Pulmonary Valve (TPV) Therapy: A revolutionary, non-surgical option for children and adults with RVOT conduit dysfunction.

www.Melody-TPV.com

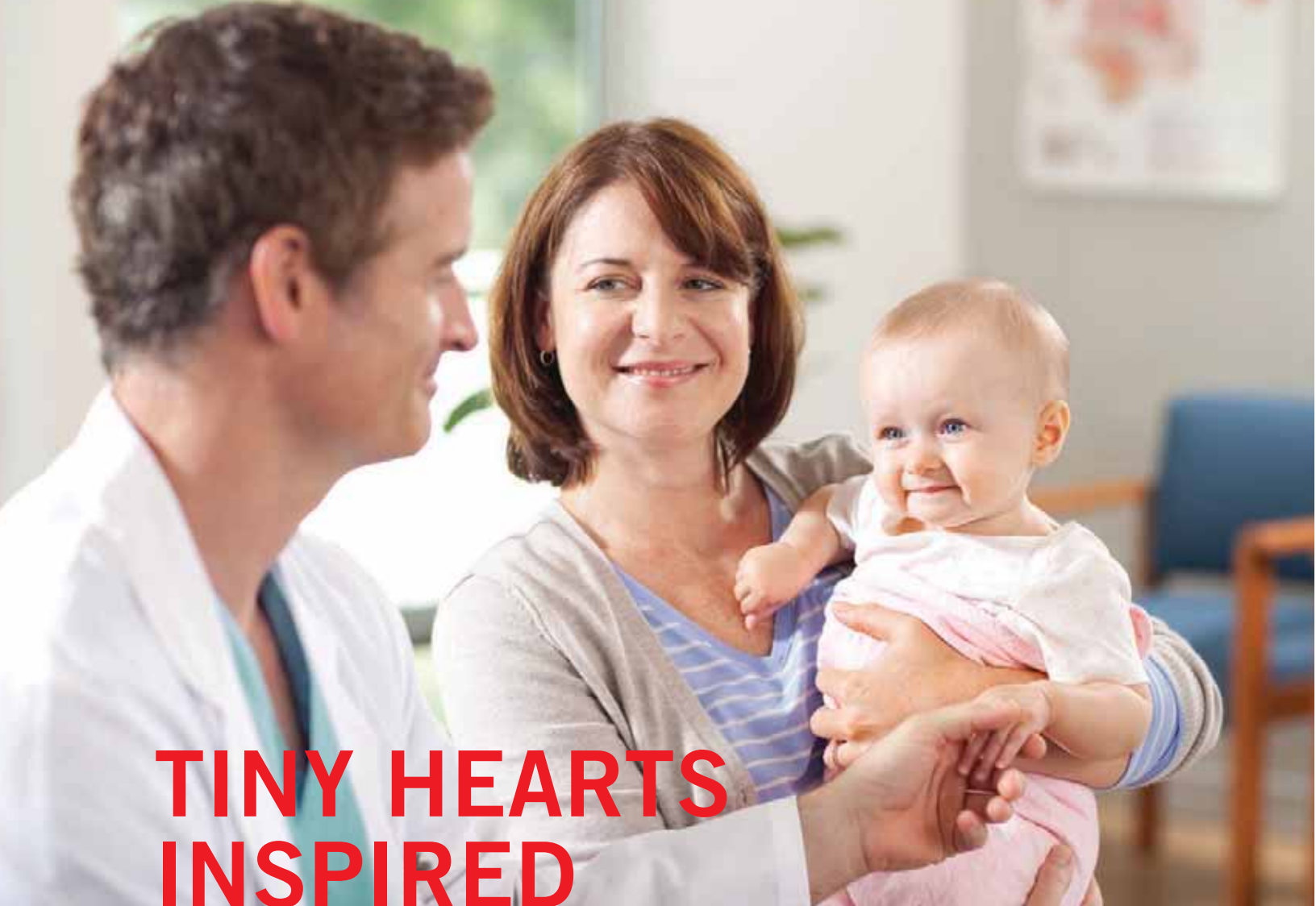Melody® Transcatheter Pulmonary Valve,
Ensemble® Transcatheter Valve Delivery System

For more information about Melody Transcatheter Pulmonary Valve Therapy, contact your Medtronic Sales Representative, your local Medtronic office or visit www.Melody-TPV.com.

Melody and Ensemble are registered trademarks of Medtronic, Inc.

The Melody® Transcatheter Pulmonary Valve and Ensemble® Transcatheter Delivery system has received CE Mark approval and is available for distribution in Europe. Additionally, a Medical Device Licence has been granted and the system is available for distribution in Canada.

©Medtronic, Inc. 2010 UC201001894a EE



TINY HEARTS INSPIRED HYBRID LABS WITH ACCESS FOR BIG TEAMS.

Fixing a heart from birth through adulthood takes big teams working together. So we examined the needs of leading clinicians when designing our hybrid solutions. The result: our Infinix™-i with 5-axis positioners and low profile detectors, stays out of the way, but right where needed, providing the best possible access to patients. To lead, you must first listen.

medical.toshiba.com

TOSHIBA
Leading Innovation >>>